Settings

1 2 3 4 5 6 7 8 9 10 11 12 13 14 15 16 17 18 19 20 21 22 23 24 25 26 27 28 29 30

Item 1 of 40
Question Id: 1105

Mark | Previous | Next | Full Screen | Tutorial | Lab Values | Notes | Calculator | Reverse Color | Text Zoom | Settings

A 64-year-old man comes to the office due to skin blisters on his trunk and groin. The patient has had itching for the past several weeks and developed the blisters a week ago. He has a history of hypertension and osteoarthritis. He received zoster vaccine at age 60. Examination shows numerous 0.5- to 3-cm bullous skin lesions. Skin biopsy is performed and shows the findings in the image below. Which of the following is the most likely diagnosis?

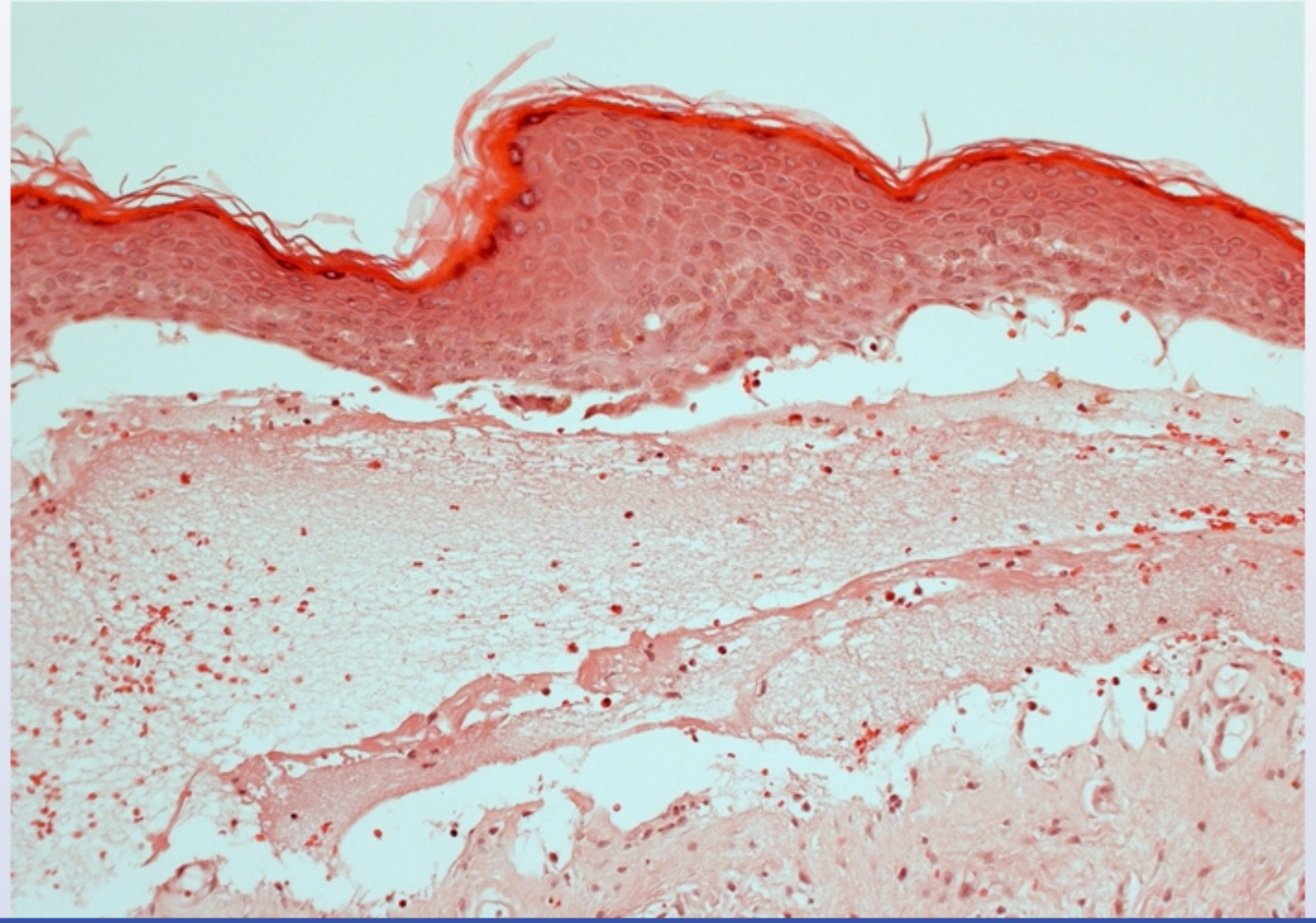

Block Time Remaining: 00:00:04
TUTOR

8 | Feedback | Suspend | End Block

Settings

1 2 3 4 5 6 7 8 9 10 11 12 13 14 15 16 17 18 19 20 21 22 23 24 25 26 27 28 29 30

Item 1 of 40
Question Id: 1105

Mark | Previous | Next | Full Screen | Tutorial | Lab Values | Notes | Calculator | Reverse Color | Text Zoom | Settings

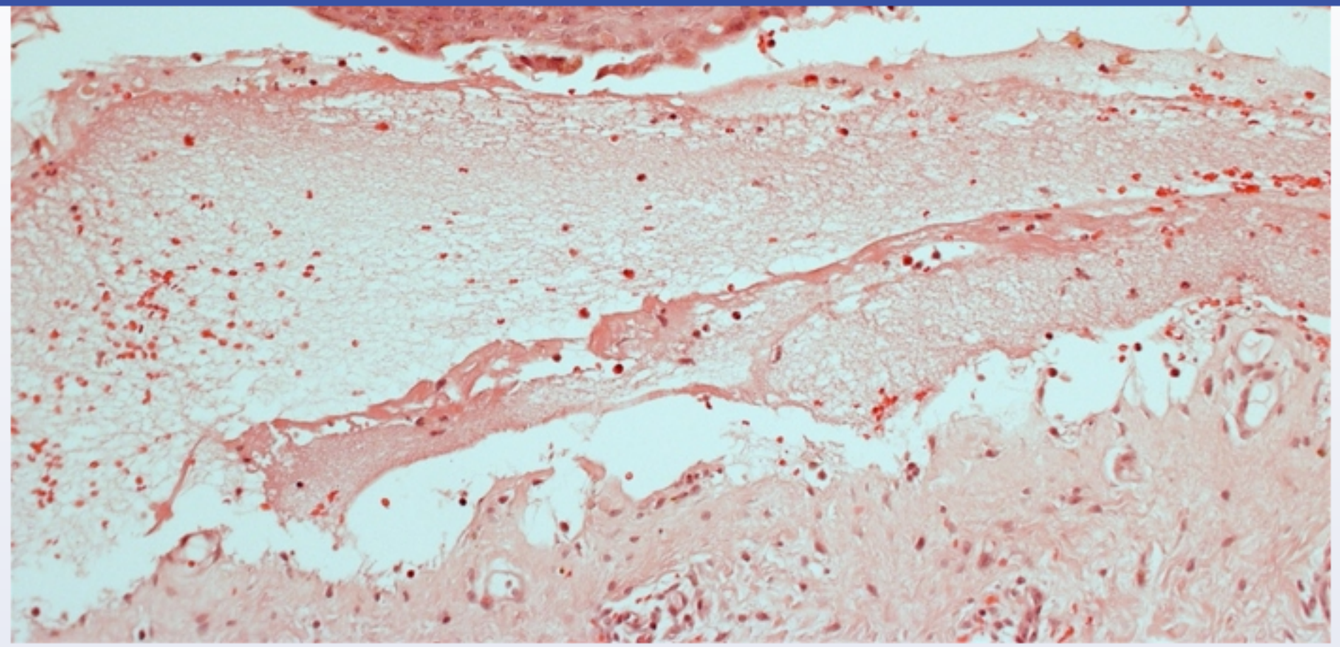

A. Bullous pemphigoid

B. Contact dermatitis

C. Dermatitis herpetiformis

D. Lichen planus

E. Pemphigus vulgaris

Submit

Block Time Remaining: 00:00:06
TUTOR

8 | Feedback | Suspend | End Block

Settings

1 2 3 4 5 6 7 8 9 10 11 12 13 14 15 16 17 18 19 20 21 22 23 24 25 26 27 28 29 30

Item 1 of 40
Question Id: 1105

Mark | Previous | Next | Full Screen | Tutorial | Lab Values | Notes | Calculator | Reverse Color | Text Zoom | Settings

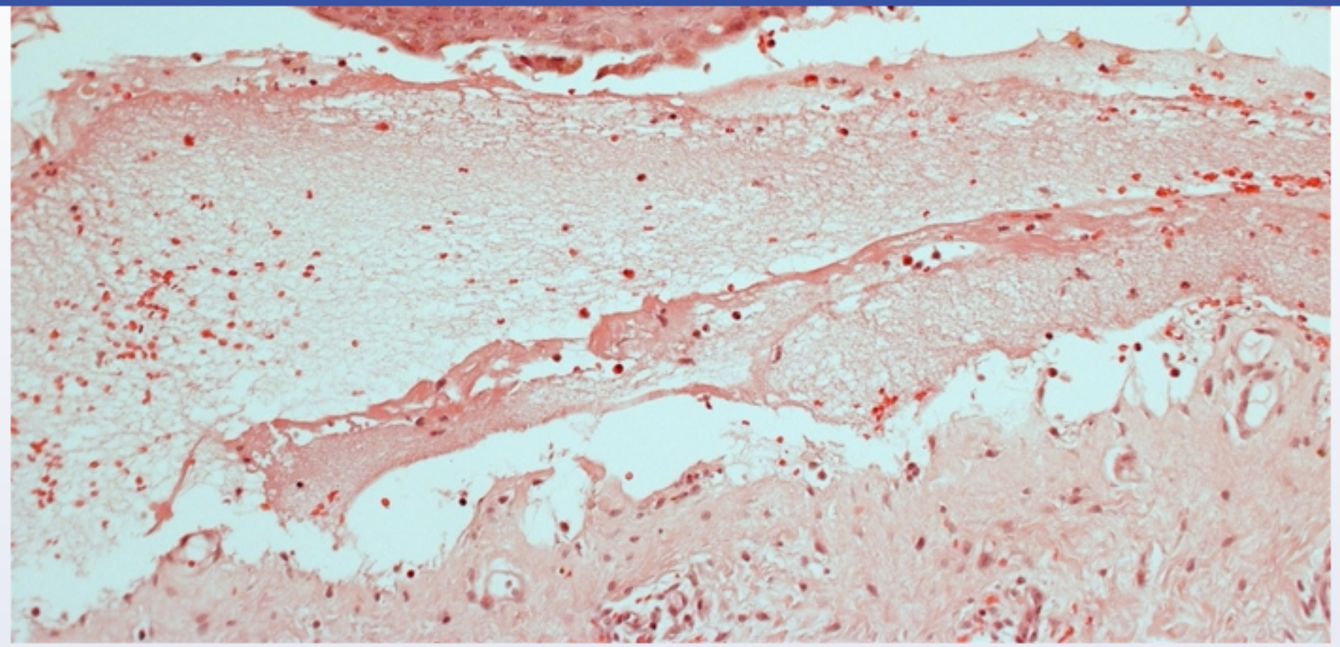

A. Bullous pemphigoid (77%)
B. Contact dermatitis (2%)
C. Dermatitis herpetiformis (4%)
D. Lichen planus (2%)
E. Pemphigus vulgaris (13%)

Omitted
Correct answer

77%
Answered correctly

08 secs
Time Spent

01/21/2020
Last Updated

Block Time Remaining: 00:00:08
TUTOR

8 | Feedback | Suspend | End Block

Explanation

	Pemphigus vulgaris	Bullous pemphigoid
Autoantibody target	• Desmosomes (desmoglein 3 & 1)	• Hemidesmosomes (bullous pemphigoid antigens 1 & 2)
Histopathology	• **Intraepidermal** cleavage • **Acantholysis** (detached keratinocytes) • "Tombstone cells" along basal layer	• **Subepidermal** cleavage • No acantholysis
Immunofluorescence	• Netlike intercellular IgG	• Linear IgG at basement membrane
Clinical features	• Middle-aged or elderly • **Flaccid** bullae • Oral/mucosal involvement • Nikolsky sign positive	• Predominantly elderly • **Tense** bullae • Rare oral/mucosal involvement

©UWorld

Bullous pemphigoid (BP) is an autoimmune condition characterized by serous fluid-filled, tense bullae on normal or erythematous skin. The most common sites of involvement include the inner thighs, flexor aspects of the forearms, axillae, groin, and lower abdomen. Elderly individuals are

Bullous pemphigoid (BP) is an autoimmune condition characterized by serous fluid-filled, tense bullae on normal or erythematous skin. The most common sites of involvement include the inner thighs, flexor aspects of the forearms, axillae, groin, and lower abdomen. Elderly individuals are most commonly affected.

BP is caused by antibodies against **hemidesmosomes** along the basement membrane of the **dermal-epidermal junction**. These autoantibodies result in a destructive inflammatory cascade that causes the entire epidermis to separate from the dermis, forming **subepidermal, nonacantholytic** blisters. Immunofluorescence shows IgG and/or C3 deposits in a linear pattern along the basement membrane.

(Choice B) Acute allergic contact dermatitis is characterized by localized erythema, vesicles, edema, and severe pruritus. Biopsy typically shows spongiosis (abnormal accumulation of edema fluid in the intercellular spaces between keratinocytes) and lymphocytic perivascular infiltrates.

(Choice C) Dermatitis herpetiformis is characterized histologically by microabscesses containing fibrin and neutrophils at the dermal papillae tips. The overlying basal cells become vacuolated, and blisters form at the tips of the involved papillae.

(Choice D) Lichen planus causes pruritic, purple papules and plaques involving the skin and mucous membranes. Microscopic analysis shows a lymphocytic infiltrate at the dermal-epidermal junction with destruction of basal epidermal cells.

(Choice E) Pemphigus is due to autoantibodies directed against desmosomal proteins. Biopsy of an active pemphigus lesion will show intraepithelial cleavage with detached keratinocytes (acantholysis), retained keratinocytes along the basement membrane, and an eosinophilic inflammatory infiltrate.

Educational objective:
Bullous pemphigoid is characterized by autoantibodies against hemidesmosomes along the basement membrane of the dermal-epidermal junction. This causes the entire epidermis to separate from the dermis, forming tense, subepidermal blisters.

References

- Diagnosis and classification of pemphigus and bullous pemphigoid.

Pathology	Dermatology	Bullous pemphigoid
Subject	System	Topic

common sites of involvement include the inner thighs, flexor aspects of the forearms, axillae, groin, and lower abdomen. Elderly individuals are most commonly affected.

BP is caused by antibodies against **hemidesmosomes** along the basement membrane of the **dermal-epidermal junction**. These autoantibodies result in a destructive inflammatory cascade that causes the entire epidermis to separate from the dermis, forming **subepidermal, nonacantholytic** blisters. Immunofluorescence shows IgG and/or C3 deposits in a linear pattern along the basement membrane.

(Choice B) Acute allergic contact dermatitis is characterized by localized erythema, vesicles, edema, and severe pruritus. Biopsy typically shows spongiosis (abnormal accumulation of edema fluid in the intercellular spaces between keratinocytes) and lymphocytic perivascular infiltrates.

(Choice C) Dermatitis herpetiformis is characterized histologically by microabscesses containing fibrin and neutrophils at the dermal papillae tips. The overlying basal cells become vacuolated, and blisters form at the tips of the involved papillae.

(Choice D) Lichen planus causes pruritic, purple papules and plaques involving the skin and mucous membranes. Microscopic analysis shows a lymphocytic infiltrate at the dermal-epidermal junction with destruction of basal epidermal cells.

(Choice E) Pemphigus is due to autoantibodies directed against desmosomal proteins. Biopsy of an active pemphigus lesion will show intraepithelial cleavage with detached keratinocytes (acantholysis), retained keratinocytes along the basement membrane, and an eosinophilic inflammatory infiltrate.

Educational objective:
Bullous pemphigoid is characterized by autoantibodies against hemidesmosomes along the basement membrane of the dermal-epidermal junction. This causes the entire epidermis to separate from the dermis, forming tense, subepidermal blisters.

References

- Diagnosis and classification of pemphigus and bullous pemphigoid.

Pathology	Dermatology	Bullous pemphigoid
Subject	System	Topic

Copyright © UWorld. All rights reserved.

Settings

1 2 3 4 5 6 7 8 9 10 11 12 13 14 15 16 17 18 19 20 21 22 23 24 25 26 27 28 29 30

Item 1 of 40
Question Id: 1105

Mark | Previous | Next | Full Screen | Tutorial | Lab Values | Notes | Calculator | Reverse Color | Text Zoom | Settings

- **Flaccid** bullae

elderly

Exhibit Display

Bulla Bullous Pemphigoid Bulla Bullous Pemphigoid

Zoom In | Zoom Out | Reset | Add To New Card | Existing Card

Block Time Remaining: 00:00:08
TUTOR

8 | Feedback | Suspend | End Block

Settings

1 2 3 4 5 6 7 8 9 10 11 12 13 14 15 16 17 18 19 20 21 22 23 24 25 26 27 28 29 30

Item 1 of 40
Question Id: 1105

Mark | Previous | Next | Full Screen | Tutorial | Lab Values | Notes | Calculator | Reverse Color | Text Zoom | Settings

- **Flaccid** bullae

elderly

Exhibit Display

Bulla Bullous Pemphigoid Bulla Bullous Pemphigoid

Zoom In | Zoom Out | Reset | Add To New Card | Existing Card

Block Time Remaining: 00:00:08
TUTOR

8 | Feedback | Suspend | End Block

Settings

1 2 3 4 5 6 7 8 9 10 11 12 13 14 15 16 17 18 19 20 21 22 23 24 25 26 27 28 29 30

Item 1 of 40
Question Id: 1105

Mark | Previous | Next | Full Screen | Tutorial | Lab Values | Notes | Calculator | Reverse Color | Text Zoom | Settings

- **Flaccid** bullae

elderly

Exhibit Display

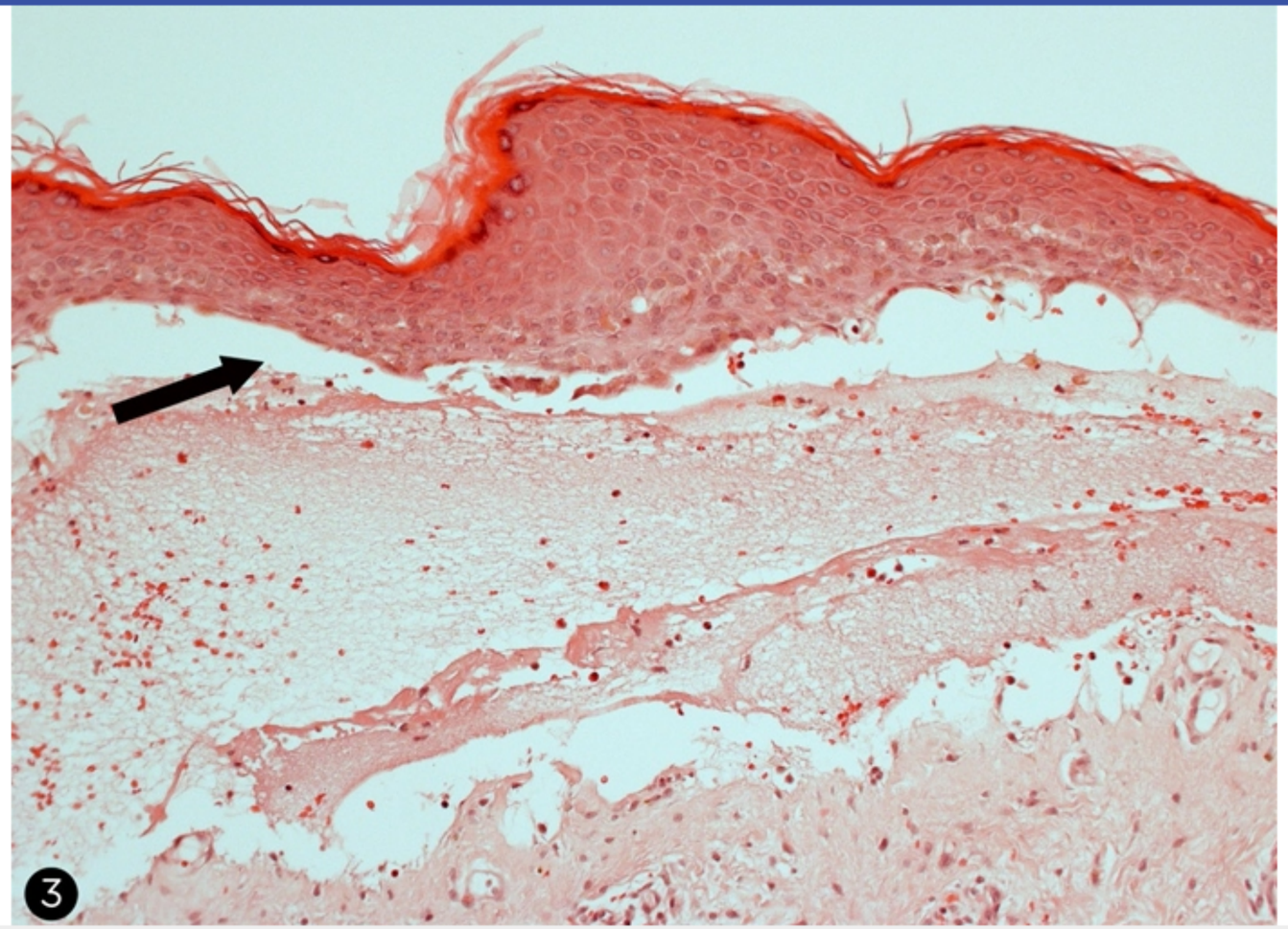

Zoom In | Zoom Out | Reset | Add To New Card | Existing Card

Block Time Remaining: 00:00:08
TUTOR

8 | Feedback | Suspend | End Block

Settings

1 2 3 4 5 6 7 8 9 10 11 12 13 14 15 16 17 18 19 20 21 22 23 24 25 26 27 28 29 30

Item 1 of 40
Question Id: 1105

Mark | Previous | Next | Full Screen | Tutorial | Lab Values | Notes | Calculator | Reverse Color | Text Zoom | Settings

- **Flaccid** bullae

elderly

Exhibit Display

Zoom In | Zoom Out | Reset | Add To New Card | Existing Card

Block Time Remaining: 00:00:08
TUTOR

8 | Feedback | Suspend | End Block

Settings

1 2 3 4 5 6 7 8 9 10 11 12 13 14 15 16 17 18 19 20 21 22 23 24 25 26 27 28 29 30

Item 1 of 40
Question Id: 1105

Mark | Previous | Next | Full Screen | Tutorial | Lab Values | Notes | Calculator | Reverse Color | Text Zoom | Settings

- **Flaccid** bullae

elderly

Exhibit Display

Zoom In | Zoom Out | Reset | Add To New Card | Existing Card

Block Time Remaining: 00:00:08
TUTOR

8 | Feedback | Suspend | End Block

Settings

1 2 3 4 5 6 7 8 9 10 11 12 13 14 15 16 17 18 19 20 21 22 23 24 25 26 27 28 29 30

Item 1 of 40
Question Id: 1105

Mark | Previous | Next | Full Screen | Tutorial | Lab Values | Notes | Calculator | Reverse Color | Text Zoom | Settings

- **Flaccid** bullae

elderly

Exhibit Display

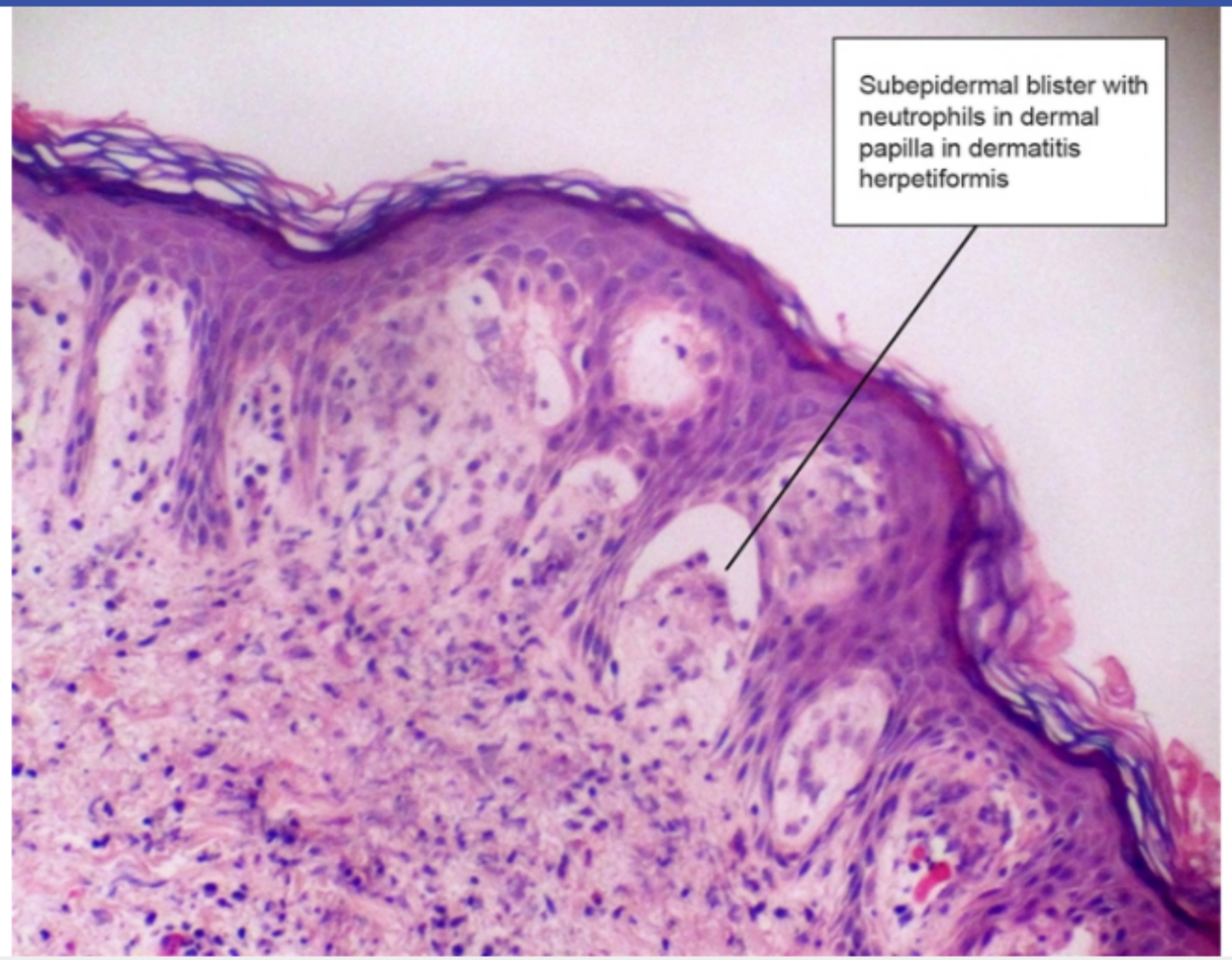

Zoom In | Zoom Out | Reset | Add To New Card | Existing Card

Block Time Remaining: 00:00:08
TUTOR

8 | Feedback | Suspend | End Block

Settings

1 2 3 4 5 6 7 8 9 10 11 12 13 14 15 16 17 18 19 20 21 22 23 24 25 26 27 28 29 30

Item 1 of 40
Question Id: 1105

Mark | Previous | Next | Full Screen | Tutorial | Lab Values | Notes | Calculator | Reverse Color | Text Zoom | Settings

common sites of involvement include the inner thighs, flexor aspects of the forearms, axillae, groin, and lower abdomen. Elderly individuals are

Exhibit Display

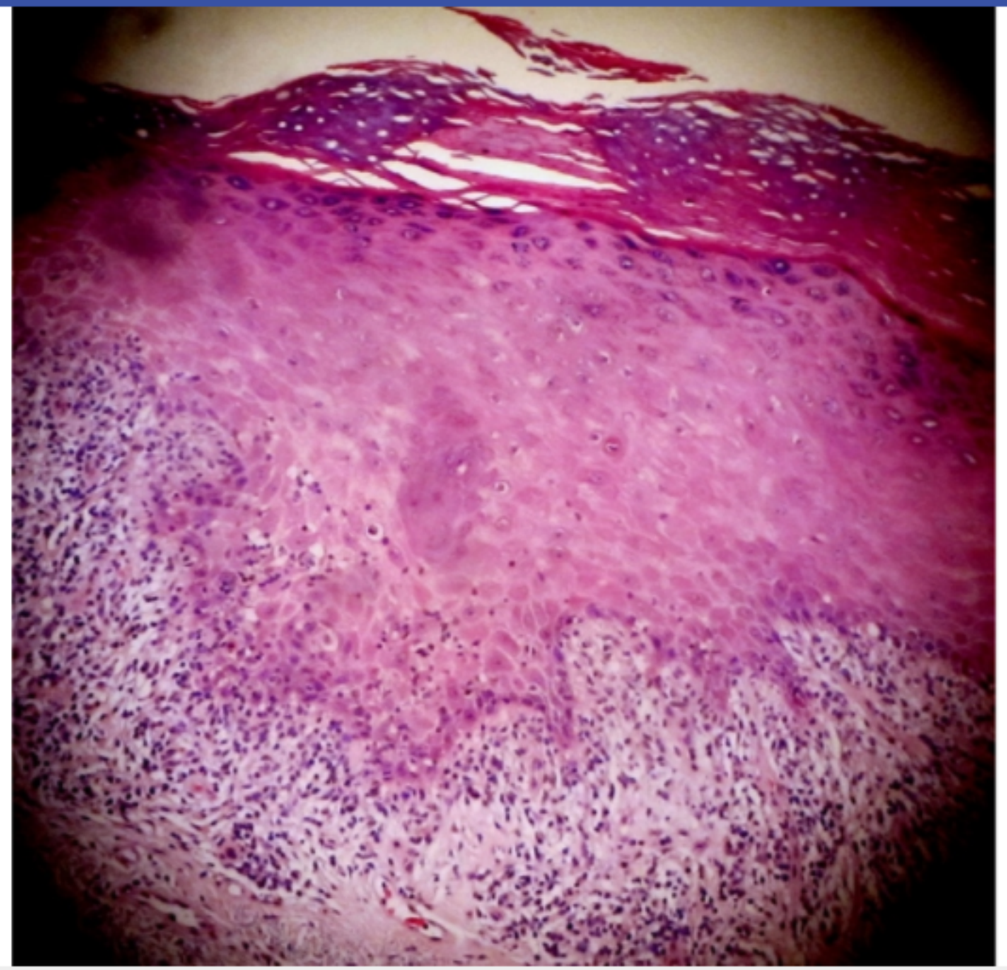

Zoom In | Zoom Out | Reset | Add To New Card | Existing Card

Block Time Remaining: 00:00:08
TUTOR

8 | Feedback | Suspend | End Block

Settings

1 2 3 4 5 6 7 8 9 10 11 12 13 14 15 16 17 18 19 20 21 22 23 24 25 26 27 28 29 30

Item 1 of 40
Question Id: 1105

Mark | Previous | Next | Full Screen | Tutorial | Lab Values | Notes | Calculator | Reverse Color | Text Zoom | Settings

common sites of involvement include the inner thighs, flexor aspects of the forearms, axillae, groin, and lower abdomen. Elderly individuals are

Exhibit Display

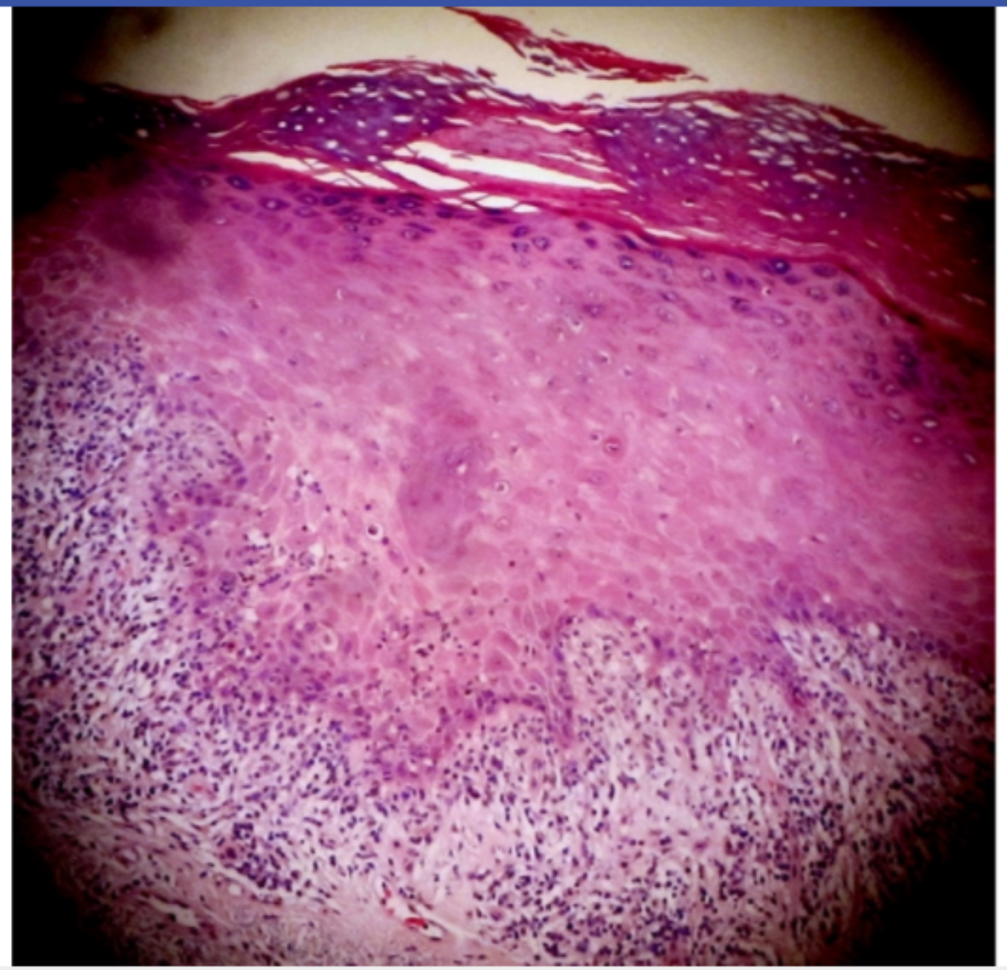

Zoom In | Zoom Out | Reset | Add To New Card | Existing Card

Block Time Remaining: 00:00:08
TUTOR

8 | Feedback | Suspend | End Block

Settings

1 2 3 4 5 6 7 8 9 10 11 12 13 14 15 16 17 18 19 20 21 22 23 24 25 26 27 28 29 30

Item 1 of 40
Question Id: 1105

Mark | Previous | Next | Full Screen | Tutorial | Lab Values | Notes | Calculator | Reverse Color | Text Zoom | Settings

common sites of involvement include the inner thighs, flexor aspects of the forearms, axillae, groin, and lower abdomen. Elderly individuals are

Exhibit Display

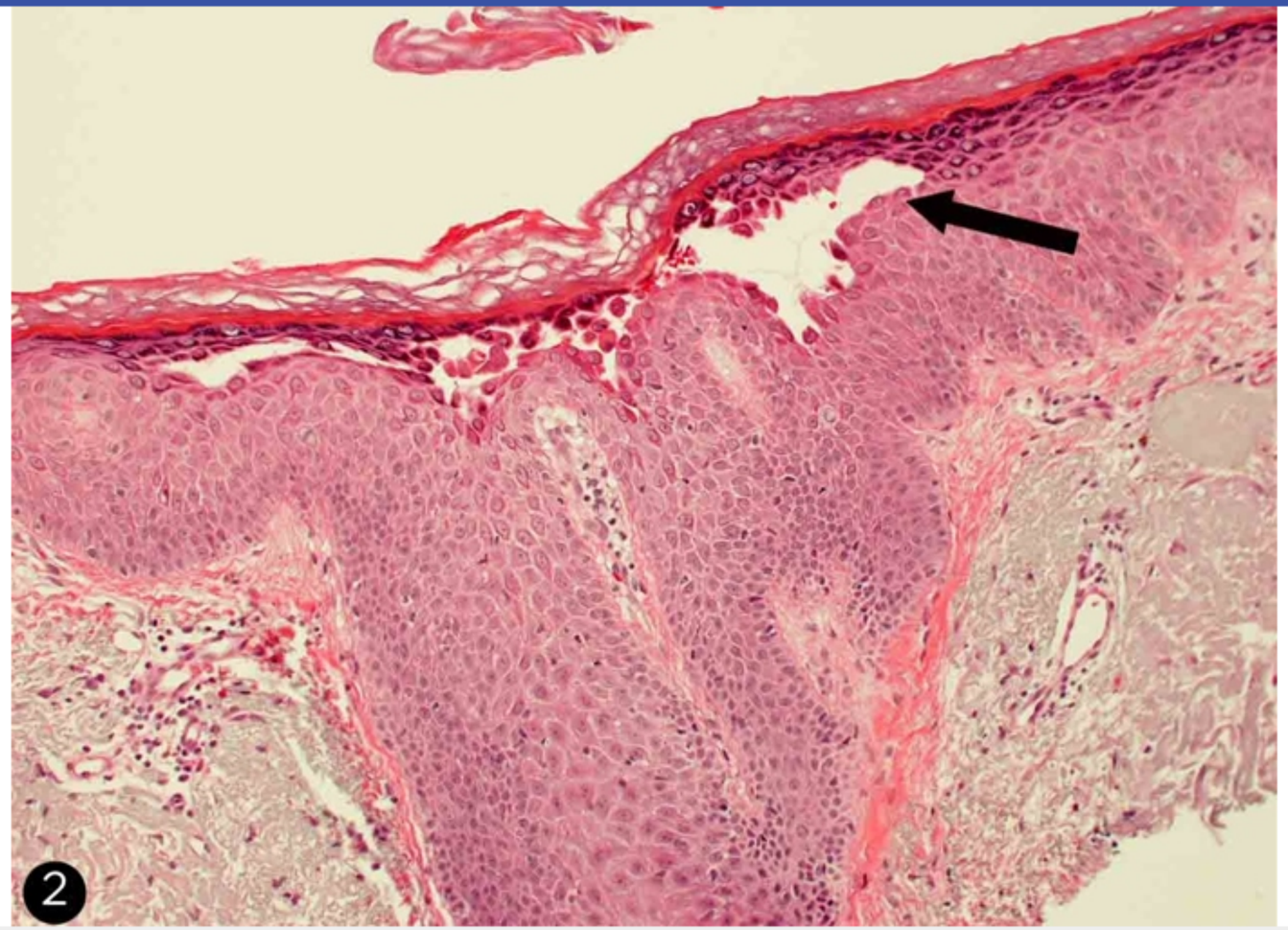

Zoom In | Zoom Out | Reset | Add To New Card | Existing Card

Block Time Remaining: 00:00:08
TUTOR

8 | Feedback | Suspend | End Block

A 3-month-old male is brought to the office with a rapidly growing skin lesion on his cheek. Physical examination findings are shown in the image below.

Which of the following is the most likely diagnosis in this patient?

- A. Cavernous hemangioma
- B. Cherry hemangioma

Settings

1
2
3
4
5
6
7
8
9
10
11
12
13
14
15
16
17
18
19
20
21
22
23
24
25
26
27
28
29
30

Item 2 of 40
Question Id: 827

Mark | Previous | Next | Full Screen | Tutorial | Lab Values | Notes | Calculator | Reverse Color | Text Zoom | Settings

Which of the following is the most likely diagnosis in this patient?

A. Cavernous hemangioma

B. Cherry hemangioma

C. Cystic hygroma

D. Spider angioma

E. Strawberry (capillary) hemangioma

Submit

Block Time Remaining: 00:00:14
TUTOR

3 | Feedback | Suspend | End Block

Settings

1 2 3 4 5 6 7 8 9 10 11 12 13 14 15 16 17 18 19 20 21 22 23 24 25 26 27 28 29 30

Item 2 of 40
Question Id: 827

Mark | Previous | Next | Full Screen | Tutorial | Lab Values | Notes | Calculator | Reverse Color | Text Zoom | Settings

Which of the following is the most likely diagnosis in this patient?

A. Cavernous hemangioma (2%)

B. Cherry hemangioma (12%)

C. Cystic hygroma (0%)

D. Spider angioma (0%)

✓ E. Strawberry (capillary) hemangioma (84%)

Omitted
Correct answer

84%
Answered correctly

08 secs
Time Spent

04/07/2020
Last Updated

Block Time Remaining: 00:00:16
TUTOR

3 | Feedback | Suspend | End Block

Explanation

The image above shows a superficial infantile hemangioma (ie, **capillary hemangioma**), which is the most common benign vascular tumor in children. These superficial lesions are composed of strawberry-like **bright red compressible plaques** with sharply demarcated borders and most often occur on the head or neck. Microscopically, capillary hemangiomas consist of thin-walled blood vessels filled with blood and separated by connective tissue.

Superficial capillary hemangiomas appear during the days or weeks after birth and **grow rapidly** during the first year of life. Most of these tumors **regress** by the time the child is 5-9 years old. Infantile hemangiomas can also be found in deeper tissues and the viscera, especially the liver.

(Choice A) Cavernous hemangiomas may be present at birth or develop later in life. They present as soft blue compressible masses up to a few centimeters in size. Light microscopy reveals large dilated vascular spaces.

(Choice B) Cherry hemangiomas are the most common benign vascular proliferations in adults. They are small, bright red, cutaneous papules that appear in patients during adulthood. They consist of dilated capillaries and post-capillary venules in the papillary dermis and do not regress spontaneously.

(Choice C) Cystic hygromas (lymphangiomas) are benign tumors that consist of dilated lymphatic spaces lined by endothelium. They most commonly occur on the neck, and on physical examination these tumors are lobulated, compressible and usually transilluminate.

(Choice D) Spider angiomas are common in pregnancy, liver disease and in patients that take OCPs or estrogen supplements. They are dilated cutaneous arterioles that present as central papules with radiating blanching capillaries.

Educational Objective:
Superficial infantile hemangiomas (ie, strawberry/capillary hemangiomas) are benign vascular tumors of childhood. They appear during the first weeks of life, initially grow rapidly, and typically regress by the time the child is 5-9 years old. These tumors are composed of blood-filled capillaries separated by connective tissue.

Pathology	Dermatology	Hemangioma
Subject	System	Topic

Settings

1
2
3
4
5
6
7
8
9
10
11
12
13
14
15
16
17
18
19
20
21
22
23
24
25
26
27
28
29
30

Item 2 of 40
Question Id: 827

Mark | Previous | Next | Full Screen | Tutorial | Lab Values | Notes | Calculator | Reverse Color | Text Zoom | Settings

Explanation

Exhibit Display

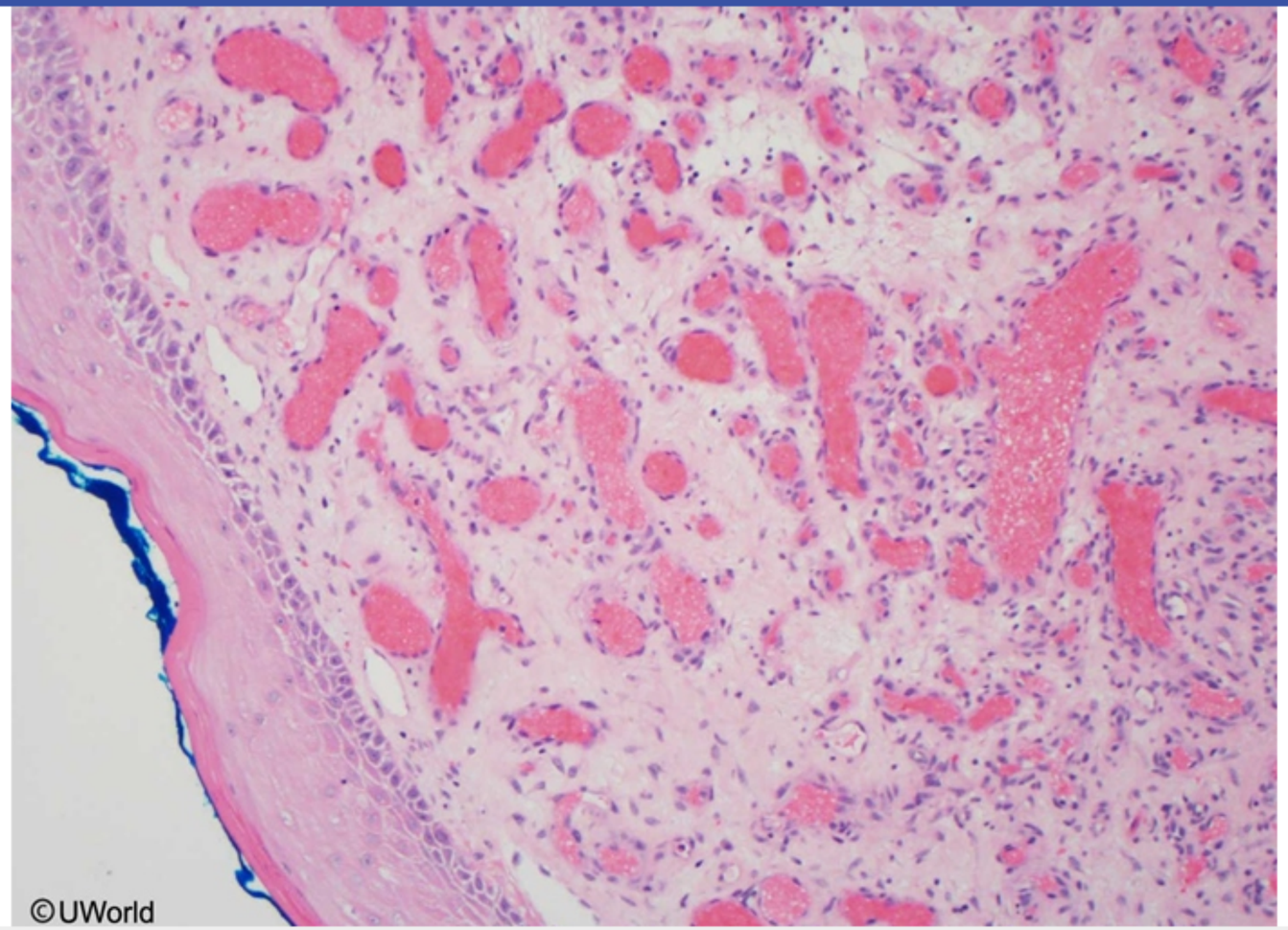

Zoom In | Zoom Out | Reset | Add To New Card | Existing Card

Block Time Remaining: 00:00:16
TUTOR

3 | Feedback | Suspend | End Block

Settings

1
2
3
4
5
6
7
8
9
10
11
12
13
14
15
16
17
18
19
20
21
22
23
24
25
26
27
28
29
30

Item 2 of 40
Question Id: 827

Mark | Previous | Next | Full Screen | Tutorial | Lab Values | Notes | Calculator | Reverse Color | Text Zoom | Settings

Explanation

Exhibit Display

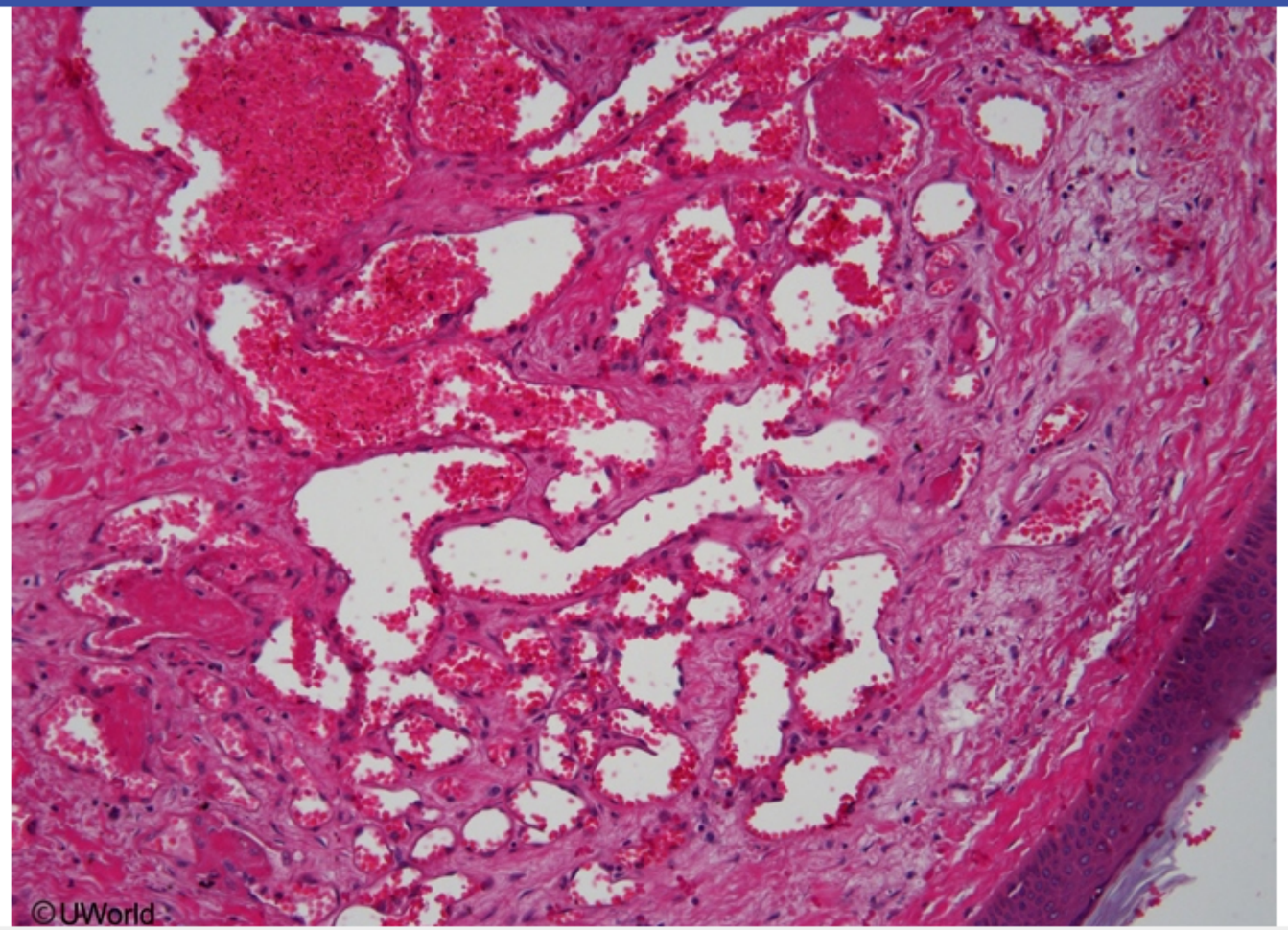

Zoom In | Zoom Out | Reset | Add To New Card | Existing Card

Block Time Remaining: 00:00:16
TUTOR

3 | Feedback | Suspend | End Block

Settings

1
2
3
4
5
6
7
8
9
10
11
12
13
14
15
16
17
18
19
20
21
22
23
24
25
26
27
28
29
30

Item 2 of 40
Question Id: 827

Mark | Previous | Next | Full Screen | Tutorial | Lab Values | Notes | Calculator | Reverse Color | Text Zoom | Settings

Explanation

Exhibit Display

Zoom In | Zoom Out | Reset | Add To New Card | Existing Card

Block Time Remaining: 00:00:16
TUTOR

3 | Feedback | Suspend | End Block

1
2
3
4
5
6
7
8
9
10
11
12
13
14
15
16
17
18
19
20
21
22
23
24
25
26
27
28
29
30

The image above shows a superficial infantile hemangioma (ie, **capillary hemangioma**), which is the most common benign vascular tumor in

Exhibit Display

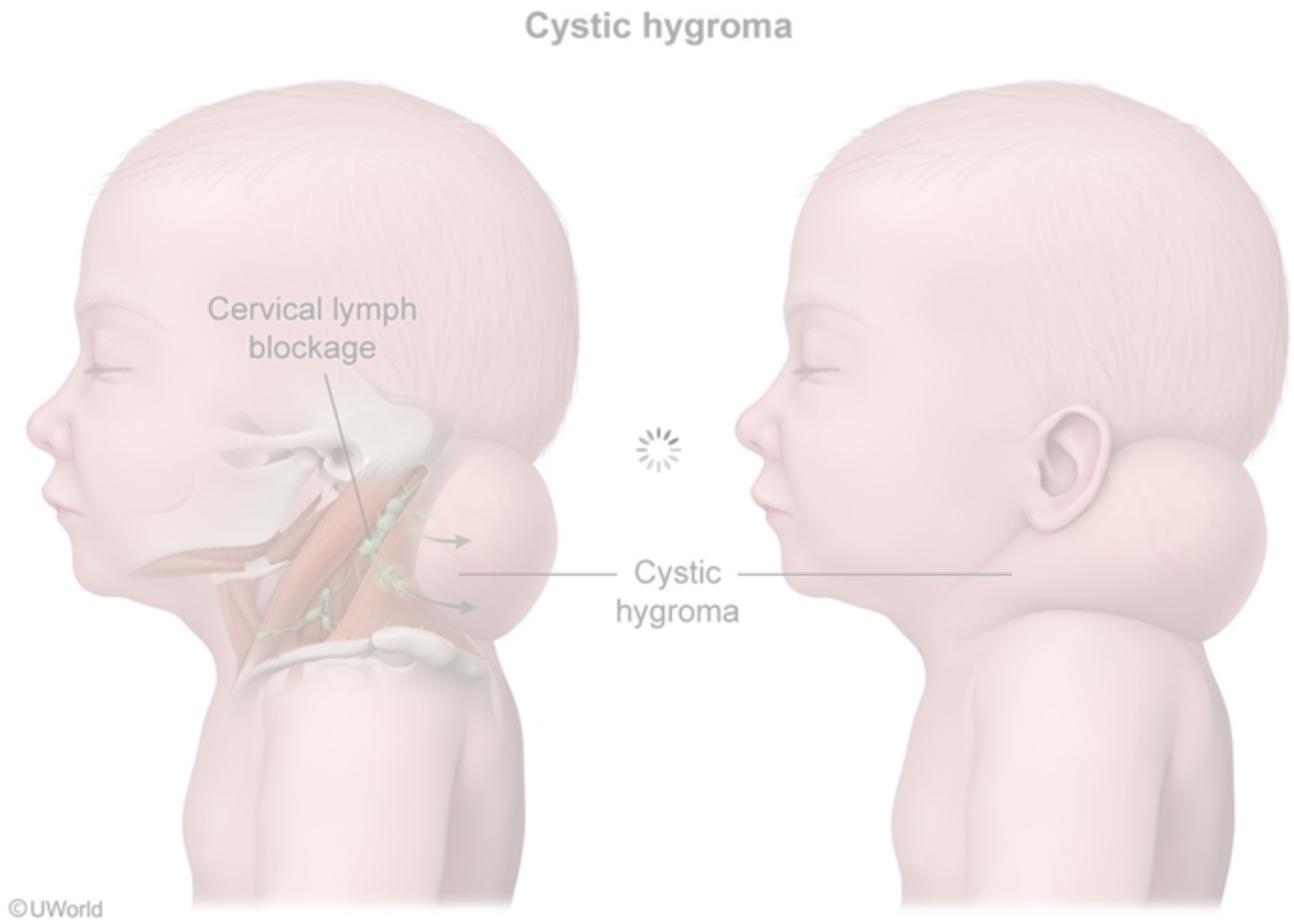

Zoom In | Zoom Out | Reset | Add To New Card | Existing Card

The image above shows a superficial infantile hemangioma (ie, **capillary hemangioma**), which is the most common benign vascular tumor in children. These superficial lesions are composed of strawberry-like **bright red compressible plaques** with sharply demarcated borders and most often occur on the head o y connective tissue.

Superficial capillary hema ors **regress** by the time the ch

(Choice A) Cavernous he few centimeters in size. Light

(Choice B) Cherry hema s that appear in patients du ss spontaneously.

(Choice C) Cystic hygron commonly occur on the ne

(Choice D) Spider angior ed cutaneous arterioles that p

Educational Objective:
Superficial infantile hemar st weeks of life, initially grow capillaries separated by c

Pathology
Subject

Dermato
System

Copyright © UWorld. All rights reserved.

Exhibit Display

0:00

A 27-year-old woman comes to the emergency department with a scalp laceration after a fall. She reports a tendency to develop big scars even with small injuries. Physical examination reveals an old, healed laceration as shown in the image below.

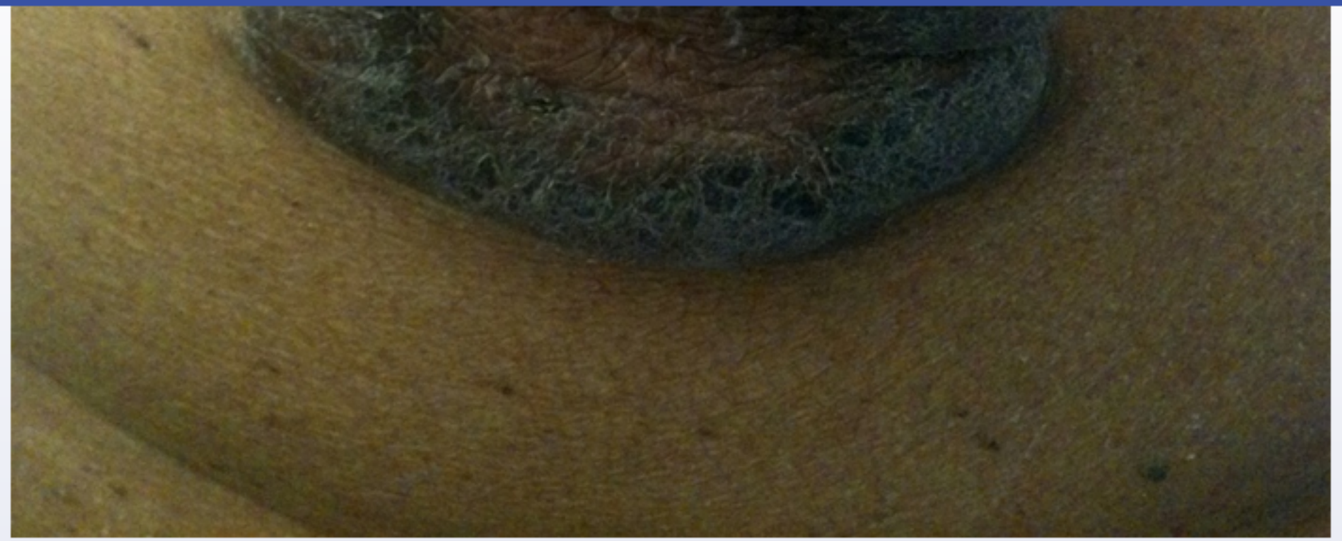

Histochemical analysis of her tissue reveals fibroblasts that overexpress a cytokine essential for normal wound healing. Which of the following substances is most likely involved?

A. Interferon-β

B. Interleukin-17

C. Nuclear factor-kappa B

D. Transforming growth factor-β

E. Tumor necrosis factor-α

Submit

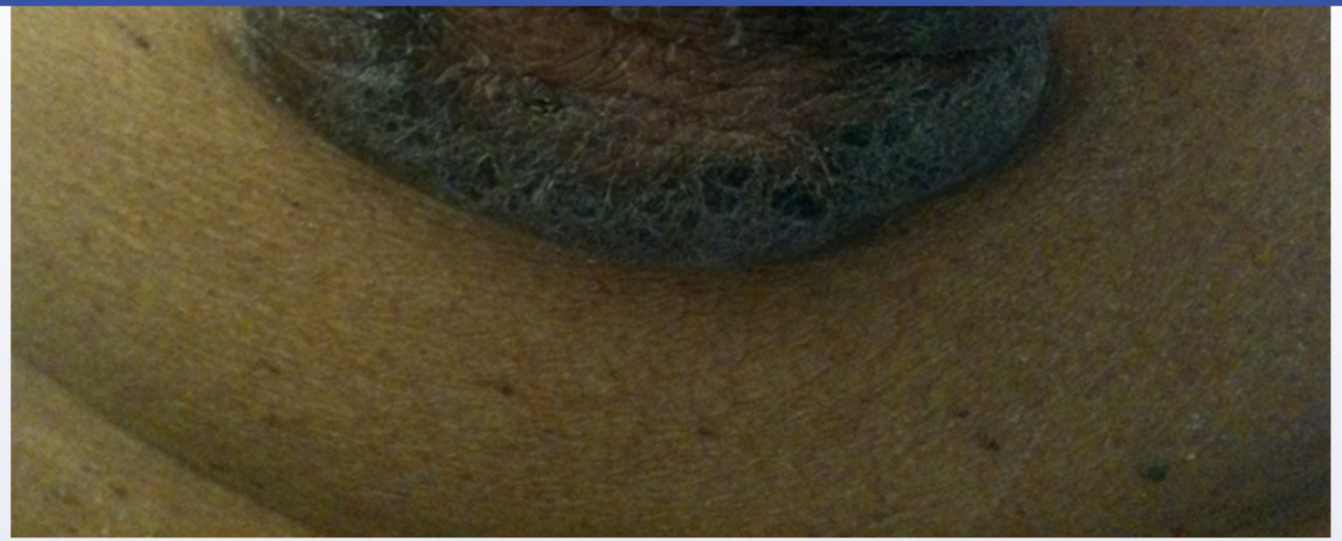

Histochemical analysis of her tissue reveals fibroblasts that overexpress a cytokine essential for normal wound healing. Which of the following substances is most likely involved?

A. Interferon-β (1%)

B. Interleukin-17 (2%)

C. Nuclear factor-kappa B (6%)

✓ D. Transforming growth factor-β (83%)

E. Tumor necrosis factor-α (5%)

Omitted
Correct answer

83%
Answered correctly

07 secs
Time Spent

04/12/2020
Last Updated

Explanation

Wound healing generally proceeds in 3 phases:

1. **The inflammatory phase** begins with formation of a fibrin clot that results in hemostasis. Cytokines released by activated platelets and damaged cells lead to migration of neutrophils (within the first 24 hours) and macrophages (2-3 days later) to the damaged area.
2. **The proliferative phase** begins 3-5 days after the injury. Fibroblasts and endothelial vascular cells proliferate to form connective tissue and blood vessels (neovascularization), respectively. Around this time, epithelial cells begin to proliferate at the dermal edges and secrete basement membrane material.
3. **The maturation phase** is characterized by fibrosis (scar formation) and starts during the second week after injury. During this phase, active fibroblasts synthesize collagen, elastin, and other components of the connective tissue matrix.

During the healing process, fibroblast migration and proliferation are controlled by multiple growth factors including platelet-derived growth factor (PDGF) and **transforming growth factor-β** (TGF-β). TGF-β is also critical for stimulating connective tissue synthesis and remodeling of the extracellular matrix. TGF-β typically decreases during the maturation phase of wound healing to limit the amount of collagenous scar tissue. Hypertrophic or disfiguring scars can be caused by persistently elevated TGF-β, which leads to increased fibroblast proliferation and activity. In addition, the fibroblasts in hypertrophic scars often have altered TGF-β signaling due to increased TGF-β receptor expression.

(Choice A) Interferon-β is an antiviral cytokine that also decreases inflammatory cell movement across the blood-brain barrier. Interferon-β analogs can be used to treat multiple sclerosis.

(Choice B) Interleukin-17 (IL-17) is produced by T_H17 cells and recruits neutrophils in addition to stimulating production of antimicrobial peptides. IL-17 improves host defense against fungi and bacteria at epithelial and mucosal surfaces. Dysregulation has been implicated in many autoimmune conditions.

(Choice C) Nuclear factor-kappa B (NF-κB) is a proinflammatory transcription factor that regulates cytokine production, adhesion molecule expression, and cell survival. Increased NF-κB activity is found in many cancers and inflammatory diseases (eg, rheumatoid arthritis, inflammatory bowel disease).

(Choice E) Tumor necrosis factor-α (TNF-α) is a cytokine secreted by activated macrophages and T cells that promotes leukocyte recruitment,

(PDGF) and **transforming growth factor-β** (TGF-β). TGF-β is also critical for stimulating connective tissue synthesis and remodeling of the extracellular matrix. TGF-β typically decreases during the maturation phase of wound healing to limit the amount of collagenous scar tissue. Hypertrophic or disfiguring scars can be caused by persistently elevated TGF-β, which leads to increased fibroblast proliferation and activity. In addition, the fibroblasts in hypertrophic scars often have altered TGF-β signaling due to increased TGF-β receptor expression.

(Choice A) Interferon-β is an antiviral cytokine that also decreases inflammatory cell movement across the blood-brain barrier. Interferon-β analogs can be used to treat multiple sclerosis.

(Choice B) Interleukin-17 (IL-17) is produced by T_H17 cells and recruits neutrophils in addition to stimulating production of antimicrobial peptides. IL-17 improves host defense against fungi and bacteria at epithelial and mucosal surfaces. Dysregulation has been implicated in many autoimmune conditions.

(Choice C) Nuclear factor-kappa B (NF-κB) is a proinflammatory transcription factor that regulates cytokine production, adhesion molecule expression, and cell survival. Increased NF-κB activity is found in many cancers and inflammatory diseases (eg, rheumatoid arthritis, inflammatory bowel disease).

(Choice E) Tumor necrosis factor-α (TNF-α) is a cytokine secreted by activated macrophages and T cells that promotes leukocyte recruitment, induces the systemic inflammatory response (eg, fever, acute-phase proteins), and regulates apoptosis.

Educational objective:
Transforming growth factor-β (TGF-β) is critical for fibroblast migration, proliferation, and connective tissue synthesis. Increased TGF-β activity is responsible for the hypertrophic/keloid scarring and fibrosis of the lung, liver, and kidney that occur with chronic inflammation.

References

- The role of the TGF-ß family in wound healing, burns and scarring: a review

Pathology	Dermatology	Keloid
Subject	System	Topic

Copyright © UWorld. All rights reserved.

A 48-year-old man who recently immigrated to the United States comes to the physician with multiple skin lesions. Physical examination shows a few well-defined, hypopigmented lesions on the skin of his lower extremities that have diminished sensation. After confirming the diagnosis of leprosy, the patient undergoes further testing to help classify the severity of his disease. Intradermal injection of heat-killed *Mycobacterium leprae* causes the development of a large indurated nodule. The patient is most likely to demonstrate which of the following additional findings?

A. Blood smears positive for mycobacteria

B. High serum level of protective antimycobacterial antibodies

C. Inactivated macrophages

D. Increased interleukin-2 and interferon-γ in skin lesions

E. Numerous acid-fast bacteria in skin lesions

Submit

A 48-year-old man who recently immigrated to the United States comes to the physician with multiple skin lesions. Physical examination shows a few well-defined, hypopigmented lesions on the skin of his lower extremities that have diminished sensation. After confirming the diagnosis of leprosy, the patient undergoes further testing to help classify the severity of his disease. Intradermal injection of heat-killed *Mycobacterium leprae* causes the development of a large indurated nodule. The patient is most likely to demonstrate which of the following additional findings?

- A. Blood smears positive for mycobacteria (1%)
- B. High serum level of protective antimycobacterial antibodies (12%)
- C. Inactivated macrophages (6%)
- ✓ D. Increased interleukin-2 and interferon-γ in skin lesions (59%)
- E. Numerous acid-fast bacteria in skin lesions (18%)

Omitted
Correct answer
D

59%
Answered correctly

02 secs
Time Spent

05/15/2020
Last Updated

Explanation

Immune response in leprosy

+ lepromin **- lepromin**

1 2 3 4 5 6 7 8 9 10 11 12 13 14 15 16 17 18 19 20 21 22 23 24 25 26 27 28 29 30

Immune response in leprosy

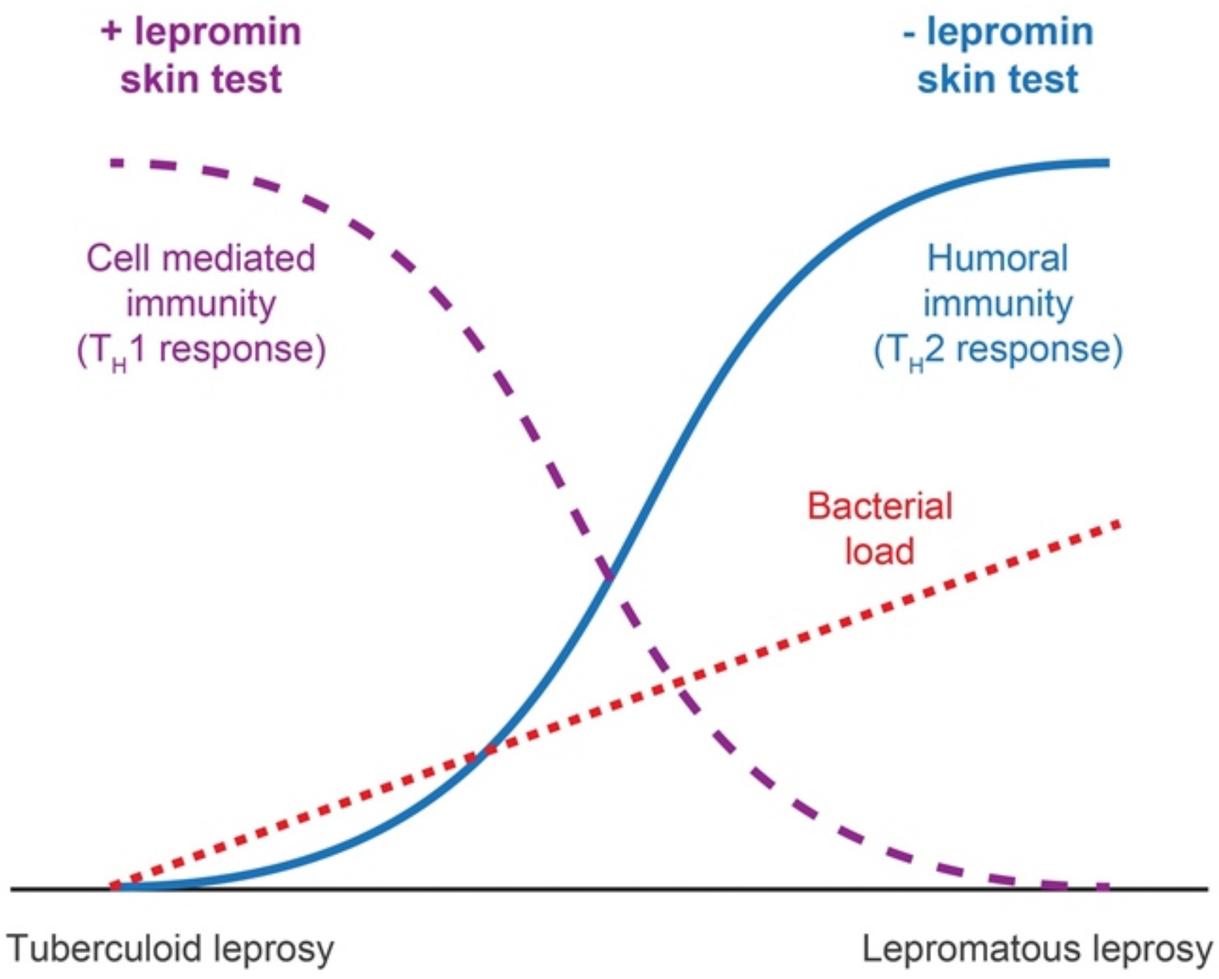

Leprosy is a chronic, slowly progressive, communicable disease caused by *Mycobacterium leprae* that typically involves the skin and peripheral nerves. Clinical manifestations are widely variable depending on the strength of the T_H1 cell-mediated immune response to the organism. Disease is classified along a spectrum between tuberculoid (mild) to lepromatous (severe) forms. Patients with tuberculoid leprosy develop a strong T_H1-mediated response (interleukin [IL]-2, IFN-γ, and IL-12) in affected tissues, leading to the activation of macrophages that kill *M leprae* organisms, thereby limiting disease extent. However, this localized inflammation damages the skin and cutaneous nerves, leading to the development of a small number of hypopigmented, well-demarcated plaques with decreased sensation.

Lepromatous leprosy is a more disseminated form of the disease characterized by an innate inability to recognize and mount a cellular immune response against *M leprae* antigens. Affected tissues show extensive accumulation of acid-fast bacilli within macrophages and often a T_H2 cytokine profile (IL-4, IL-5, and IL-10). Patients with lepromatous leprosy develop more numerous, poorly demarcated plaques that are widespread across the body. Over time, the bacterial load increases and the nodular lesions coalesce, causing the development of leonine facies and degeneration and loss of the nose and digits.

The lepromin skin test (in which *M leprae* antigens are injected intradermally) can be used to distinguish between tuberculoid and lepromatous leprosy. Patients with tuberculoid leprosy will develop an indurated nodule at the site of the injection (much like a positive PPD test for *M tuberculosis*). In contrast, the test is usually nonreactive in patients with lepromatous leprosy due to their weak T_H1 cell-mediated immune response.

(Choice A) Patients with lepromatous leprosy have a high bacterial load with widespread involvement throughout the peripheral (cooler) tissues of the body. As a result, intermittent bacteremia often occurs in the later stages of the disease. However, this patient's few lesions and positive lepromin skin test are more indicative of tuberculoid leprosy, which has a very low bacterial load with limited tissue involvement.

(Choice B) High serum antimycobacterial antibody levels are more frequently seen in lepromatous leprosy than tuberculous leprosy. Because *M leprae* resides mostly within macrophages, circulating immunoglobulins have little access to the organism and are unable to bind, opsonize, or fix complement. Humoral immunity does not influence the positivity of the lepromin skin test.

(Choice C) In lepromatous leprosy, macrophages remain inactivated due to the inability of T_H1 cells to recognize *M leprae* antigens. This form of leprosy is characterized by a poor cell-mediated response and diffuse spread of the organism. This patient is presenting with the tuberculoid form, in which activated macrophages actively kill *M leprae* organisms.

The lepromin skin test (in which *M leprae* antigens are injected intradermally) can be used to distinguish between tuberculoid and lepromatous leprosy. Patients with tuberculoid leprosy will develop an indurated nodule at the site of the injection (much like a positive PPD test for *M tuberculosis*). In contrast, the test is usually nonreactive in patients with lepromatous leprosy due to their weak T_H1 cell-mediated immune response.

(Choice A) Patients with lepromatous leprosy have a high bacterial load with widespread involvement throughout the peripheral (cooler) tissues of the body. As a result, intermittent bacteremia often occurs in the later stages of the disease. However, this patient's few lesions and positive lepromin skin test are more indicative of tuberculoid leprosy, which has a very low bacterial load with limited tissue involvement.

(Choice B) High serum antimycobacterial antibody levels are more frequently seen in lepromatous leprosy than tuberculous leprosy. Because *M leprae* resides mostly within macrophages, circulating immunoglobulins have little access to the organism and are unable to bind, opsonize, or fix complement. Humoral immunity does not influence the positivity of the lepromin skin test.

(Choice C) In lepromatous leprosy, macrophages remain inactivated due to the inability of T_H1 cells to recognize *M leprae* antigens. This form of leprosy is characterized by a poor cell-mediated response and diffuse spread of the organism. This patient is presenting with the tuberculoid form, in which activated macrophages actively kill *M leprae* organisms.

(Choice E) Acid-fast bacteria typically do not accumulate in the skin lesions of tuberculoid leprosy due to the strong cell-mediated response that is effective at eradicating *M leprae*. In some instances, this immune response is so effective that tuberculoid leprosy can be self-limited and heal completely without treatment.

Educational objective:
The lepromin skin test will be positive in patients with tuberculoid leprosy as they exhibit a strong CD4+ T_H1 cell-mediated immune response to *Mycobacterium leprae*. Patients with lepromatous leprosy will test negative due to their weak T_H1 cell-mediated immune response.

Pathology	Dermatology	Leprosy
Subject	System	Topic

Copyright © UWorld. All rights reserved.

A 58-year-old man comes to the office for evaluation of a foot wound. The patient noticed a small ulcer on the bottom of his right foot a week ago but recalls no significant foot injury. He has been applying antiseptics, but the wound has failed to heal. The patient has a 15-year history of type 2 diabetes mellitus and is nonadherent to medical therapy. He has smoked a pack of cigarettes daily for 20 years. Temperature is 37.1 C (98.8 F), blood pressure is 140/80 mm Hg, and pulse is 72/min. Right lower extremity examination shows a 1-cm (0.39-in) plantar ulcer under the first metatarsal head. There are no other lesions, and the tibial and dorsalis pedis pulses are normal. Which of the following is the major inciting factor responsible for this patient's foot ulcer?

- A. Atherosclerotic disease
- B. Bacterial infection
- C. Irritant dermatitis
- D. Sensory impairment
- E. Systemic vasculitis
- F. Venous insufficiency

Submit

A 58-year-old man comes to the office for evaluation of a foot wound. The patient noticed a small ulcer on the bottom of his right foot a week ago but recalls no significant foot injury. He has been applying antiseptics, but the wound has failed to heal. The patient has a 15-year history of type 2 diabetes mellitus and is nonadherent to medical therapy. He has smoked a pack of cigarettes daily for 20 years. Temperature is 37.1 C (98.8 F), blood pressure is 140/80 mm Hg, and pulse is 72/min. Right lower extremity examination shows a 1-cm (0.39-in) plantar ulcer under the first metatarsal head. There are no other lesions, and the tibial and dorsalis pedis pulses are normal. Which of the following is the major inciting factor responsible for this patient's foot ulcer?

- A. Atherosclerotic disease (10%)
- B. Bacterial infection (1%)
- C. Irritant dermatitis (0%)
- ✓ D. Sensory impairment (73%)
- E. Systemic vasculitis (5%)
- F. Venous insufficiency (7%)

Omitted
Correct answer
D

73%
Answered correctly

02 secs
Time Spent

04/03/2020
Last Updated

Explanation

Lower extremity ulcers

Lower extremity ulcers			
	Arterial insufficiency	**Venous insufficiency**	**Neuropathic**
Common location	Tips of toes, malleoli	Medial tibia	Bony prominences, plantar surfaces
Clinical features	Sharply demarcated, pale base; deep	Irregular, shallow, erythematous base with granulation tissue & exudate	Sharply demarcated, erythematous base
Pain	Very painful	Moderate pain	None
Skin changes	Hairless, shiny, cold	Brown/hyperpigmentation, erythema, thickened skin	Dry, scaly, calloused
Pulses	Decreased/absent	Present	Present
Associated conditions	Smoking, hypertension, atherosclerosis	Deep vein thrombosis, varicose veins, pregnancy, increased age	Diabetes mellitus, other peripheral neuropathy
Treatment	Revascularization, antiplatelet agents	Compression, elevation	Pressure offloading

This patient has a plantar ulcer under the first metatarsal head. In a patient with chronic, poorly controlled **diabetes mellitus**, this is likely a **neuropathic ulcer** due to underlying peripheral **sensory neuropathy**. Chronic hyperglycemia promotes nerve injury and impairs nerve repair in distal sensory fibers, causing decreased sensation of pain, pressure, and proprioception.

Loss of these protective senses can cause individuals to not recognize an injury due to minor trauma, friction, or **pressure**. Areas that are particularly susceptible are points of localized pressure created by a shoe or weight-bearing bones of the foot (eg, plantar surface of the **first metatarsal head**). A wound in this area often goes unnoticed (due to lack of pain sensation and being hidden by socks or shoes) and can develop into a nonhealing foot ulcer.

This patient has a plantar ulcer under the first metatarsal head. In a patient with chronic, poorly controlled **diabetes mellitus**, this is likely a **neuropathic ulcer** due to underlying peripheral **sensory neuropathy**. Chronic hyperglycemia promotes nerve injury and impairs nerve repair in distal sensory fibers, causing decreased sensation of pain, pressure, and proprioception.

Loss of these protective senses can cause individuals to not recognize an injury due to minor trauma, friction, or **pressure**. Areas that are particularly susceptible are points of localized pressure created by a shoe or weight-bearing bones of the foot (eg, plantar surface of the **first metatarsal head**). A wound in this area often goes unnoticed (due to lack of pain sensation and being hidden by socks or shoes) and can develop into a nonhealing foot ulcer.

Loss of proprioception and an increase in ligamentous laxity can also cause chronic pressure-induced joint/skin damage in the feet of patients with diabetic neuropathy, which can lead to calluses or foot deformities (eg, Charcot foot, hammer toe).

(Choice A) Although diabetic patients (especially those who smoke) often have comorbid arterial insufficiency, arterial ulcers are typically painful, sharply demarcated, and located at the tips of the toes. This patient has full distal pulses, which makes clinically significant atherosclerotic disease unlikely to be the primary cause of the ulcer.

(Choice B) Bacterial infection may delay ulcer healing, especially if there is underlying osteomyelitis, but it is not the inciting cause of neuropathic ulcers. In addition, although diabetic ulcers are often colonized by bacteria, this patient has no fever, erythema, or purulent drainage to suggest serious infection.

(Choice C) Irritant contact dermatitis presents with pruritic or painful erythema in areas of exposed skin (eg, hands). It can occasionally cause small vesicles or fissures, but ulcers are not typical.

(Choice E) Systemic vasculitic disorders (eg, polyarteritis nodosa) are an uncommon cause of skin ulcers. Vasculitic ulcers are usually painful and associated with other skin (eg, purpura, nodules) and systemic (eg, fever, fatigue) symptoms.

(Choice F) Ulcers caused by venous insufficiency are most common over the tibias or proximal to the medial malleolus. They present as irregular ulcerations in the setting of stasis dermatitis and/or varicose veins.

Educational objective:
Neuropathic foot ulcers can occur in diabetic patients when loss of pain sensation and proprioception delays recognition of injury due to trauma, friction, or sustained pressure (on plantar surface of foot bones). The risk is greatest in patients with longstanding diabetes who have poor

This patient has a plantar ulcer under the first metatarsal head. In a patient with chronic, poorly controlled **diabetes mellitus**, this is likely a **neuropathic ulcer** due to underlying peripheral **sensory neuropathy**. Chronic hyperglycemia promotes nerve injury and impairs nerve repair in distal sensory fibers, caus

Loss of these protective s
particularly susceptible ar
metatarsal head). A wou
develop into a nonhealing

Loss of proprioception an with
diabetic neuropathy, which

(Choice A) Although diab ful,
sharply demarcated, and
disease unlikely to be the

(Choice B) Bacterial infe thic
ulcers. In addition, althou st
serious infection.

(Choice C) Irritant contac
small vesicles or fissures,

(Choice E) Systemic vas l
and associated with other

(Choice F) Ulcers caused gular
ulcerations in the setting c

Educational objective:
Neuropathic foot ulcers can occur in diabetic patients when loss of pain sensation and proprioception delays recognition of injury due to trauma, friction, or sustained pressure (on plantar surface of foot bones). The risk is greatest in patients with longstanding diabetes who have poor

Exhibit Display

Zoom In Zoom Out Reset Add To New Card | Existing Card

Settings

1 2 3 4 5 6 7 8 9 10 11 12 13 14 15 16 17 18 19 20 21 22 23 24 25 26 27 28 29 30

Item 5 of 40
Question Id: 15675

Mark | Previous | Next | Full Screen | Tutorial | Lab Values | Notes | Calculator | Reverse Color | Text Zoom | Settings

This patient has a plantar ulcer under the first metatarsal head. In a patient with chronic, poorly controlled **diabetes mellitus**, this is likely a

Exhibit Display

Zoom In | Zoom Out | Reset | Add To New Card | Existing Card

friction, or sustained pressure (on plantar surface of foot bones). The risk is greatest in patients with longstanding diabetes who have poor

Block Time Remaining: 00:00:27
TUTOR

8 | Feedback | Suspend | End Block

This patient has a plantar ulcer under the first metatarsal head. In a patient with chronic, poorly controlled **diabetes mellitus**, this is likely a

Exhibit Display

Hammer & claw toe deformities

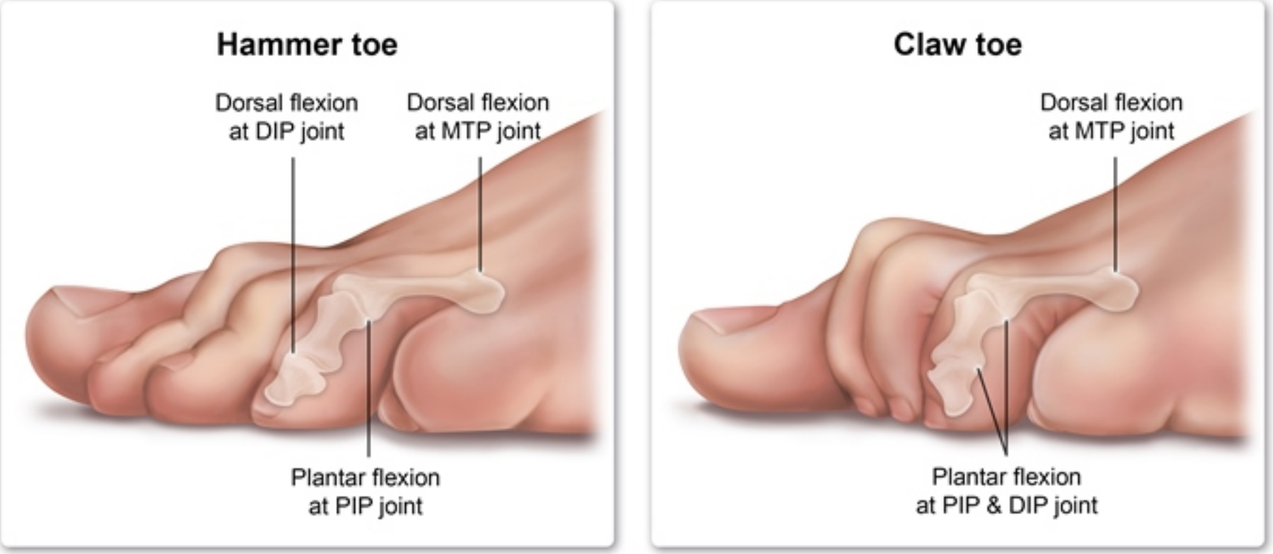

DIP = distal interphalangeal; **MTP** = metatarsophalangeal; **PIP** = proximal interphalangeal.

©UWorld

Zoom In Zoom Out Reset Add To New Card | Existing Card

friction, or sustained pressure (on plantar surface of foot bones). The risk is greatest in patients with longstanding diabetes who have poor

Settings

1 2 3 4 5 6 7 8 9 10 11 12 13 14 15 16 17 18 19 20 21 22 23 24 25 26 27 28 29 30

Item 5 of 40
Question Id: 15675

Mark | Previous | Next | Full Screen | Tutorial | Lab Values | Notes | Calculator | Reverse Color | Text Zoom | Settings

This patient has a plantar ulcer under the first metatarsal head. In a patient with chronic, poorly controlled **diabetes mellitus**, this is likely a

Exhibit Display

Zoom In | Zoom Out | Reset | Add To New Card | Existing Card

friction, or sustained pressure (on plantar surface of foot bones). The risk is greatest in patients with longstanding diabetes who have poor

Block Time Remaining: 00:00:27
TUTOR

8 | Feedback | Suspend | End Block

Settings

1
2
3
4
5
6
7
8
9
10
11
12
13
14
15
16
17
18
19
20
21
22
23
24
25
26
27
28
29
30

Item 5 of 40
Question Id: 15675

Mark | Previous | Next | Full Screen | Tutorial | Lab Values | Notes | Calculator | Reverse Color | Text Zoom | Settings

diabetic neuropathy, which can lead to calluses or foot deformities (eg, Charcot foot, hammer toe).

Exhibit Display

Zoom In | Zoom Out | Reset | Add To New Card | Existing Card

Block Time Remaining: 00:00:27
TUTOR

8 | Feedback | Suspend | End Block

Settings

1 2 3 4 5 6 7 8 9 10 11 12 13 14 15 16 17 18 19 20 21 22 23 24 25 26 27 28 29 30

Item 6 of 40
Question Id: 467

Mark | Previous | Next | Full Screen | Tutorial | Lab Values | Notes | Calculator | Reverse Color | Text Zoom | Settings

A 34-year-old female presents with a small bluish lesion under the nail of her right index finger. The lesion is extremely tender to touch. If the lesion is a tumor, its cells of origin are most likely to have which of the following functions:

- A. Proprioception
- B. Light touch
- C. Thermoregulation
- D. Lymphatic drainage
- E. Antigen processing
- F. Nail growth

Submit

Block Time Remaining: 00:00:28
TUTOR

2 | Feedback | Suspend | End Block

A 34-year-old female presents with a small bluish lesion under the nail of her right index finger. The lesion is extremely tender to touch. If the lesion is a tumor, its cells of origin are most likely to have which of the following functions:

- A. Proprioception (9%)
- B. Light touch (24%)
- ✓ C. Thermoregulation (35%)
- D. Lymphatic drainage (9%)
- E. Antigen processing (9%)
- F. Nail growth (11%)

Omitted
Correct answer
C

35%
Answered correctly

02 secs
Time Spent

02/03/2020
Last Updated

Explanation

A bluish neoplasm occurring underneath the nail bed may be either a glomus tumor (glomangioma) or a subungual melanoma. Both are rare diagnoses. Melanomas are composed of melanocytes, which have the function of pigmentation. Because 'pigmentation' is not among the answer choices, glomus tumor is the most likely diagnosis.

A glomangioma is a tumor of the modified smooth muscle cells of a glomus body. Glomus bodies are numerous small, encapsulated neurovascular organs found in the dermis of the nail bed, the pads of the fingers and toes, and the ears. Each glomus body is composed of an

A bluish neoplasm occurring underneath the nail bed may be either a glomus tumor (glomangioma) or a subungual melanoma. Both are rare diagnoses. Melanomas are composed of melanocytes, which have the function of pigmentation. Because 'pigmentation' is not among the answer choices, glomus tumor is the most likely diagnosis.

A glomangioma is a tumor of the modified smooth muscle cells of a glomus body. Glomus bodies are numerous small, encapsulated neurovascular organs found in the dermis of the nail bed, the pads of the fingers and toes, and the ears. Each glomus body is composed of an afferent arteriole connected to a richly innervated, muscular arteriovenous anastomosis, which is then connected to an efferent vein. Modified smooth muscle cells are arranged in layers around these vascular channels. The role of the glomus body is to shunt blood away from the skin surface in cold temperatures in order to prevent heat loss, and to direct blood flow to the skin surface in hot environments to facilitate the dissipation of heat.

(Choice A) Extremity receptors responsible for proprioception include muscle spindles, Golgi tendon organs, Pacinian corpuscles, and cutaneous touch receptors (including Meissner's corpuscles, Merkel's disks, and free nerve endings). A tumor of any component of these structures (e.g. neurons, connective tissue cells) would not have a bluish coloration.

(Choice B) Light touch is mediated by cutaneous mechanoreceptors, which may be encapsulated or free nerve endings. A tumor of these structures would not have a blue hue.

(Choice D) A lymphangioma is a tumor of the cells involved in lymphatic drainage. These benign lymphatic neoplasms are analogous to vascular hemangiomas. Lymphangiomas tend to occur subepidermally, in the head, neck, and axilla. They consist of networks of endothelium-lined lymph spaces. Because they do not contain pigmented cells or red blood cells, lymphangiomas would be unlikely to have a bluish appearance.

(Choice E) A tumor of antigen-processing cells would be either a histiocytosis or a lymphoma. When there is cutaneous involvement in Langerhans cell histiocytosis, patients present with erythematous papules, nodules, and/or scaling plaques. B-cell lymphomas very rarely involve the skin.

(Choice F) The basal epidermal cells of the nail matrix are responsible for nail growth. Tumors originating from the epidermis include squamous cell carcinomas (SCC) and basal cell carcinomas (BCC). SCC does not involve pigmented cells. Although BCC may involve pigmented cells, the majority of these lesions (85%) appear on the head and neck; BCC rarely affects the dorsum of the hands.

surface in cold temperatures in order to prevent heat loss, and to direct blood flow to the skin surface in hot environments to facilitate the dissipation of heat.

(Choice A) Extremity receptors responsible for proprioception include muscle spindles, Golgi tendon organs, Pacinian corpuscles, and cutaneous touch receptors (including Meissner's corpuscles, Merkel's disks, and free nerve endings). A tumor of any component of these structures (e.g. neurons, connective tissue cells) would not have a bluish coloration.

(Choice B) Light touch is mediated by cutaneous mechanoreceptors, which may be encapsulated or free nerve endings. A tumor of these structures would not have a blue hue.

(Choice D) A lymphangioma is a tumor of the cells involved in lymphatic drainage. These benign lymphatic neoplasms are analogous to vascular hemangiomas. Lymphangiomas tend to occur subepidermally, in the head, neck, and axilla. They consist of networks of endothelium-lined lymph spaces. Because they do not contain pigmented cells or red blood cells, lymphangiomas would be unlikely to have a bluish appearance.

(Choice E) A tumor of antigen-processing cells would be either a histiocytosis or a lymphoma. When there is cutaneous involvement in Langerhans cell histiocytosis, patients present with erythematous papules, nodules, and/or scaling plaques. B-cell lymphomas very rarely involve the skin.

(Choice F) The basal epidermal cells of the nail matrix are responsible for nail growth. Tumors originating from the epidermis include squamous cell carcinomas (SCC) and basal cell carcinomas (BCC). SCC does not involve pigmented cells. Although BCC may involve pigmented cells, the majority of these lesions (85%) appear on the head and neck; BCC rarely affects the dorsum of the hands.

Educational Objective:
A benign glomus tumor (glomangioma) can produce a very tender, small (a few millimeters in diameter), red-blue lesion under the nail bed. This type of tumor originates from the modified smooth muscle cells that control the thermoregulatory functions of dermal glomus bodies.

Pathology	Dermatology	Glomus tumor
Subject	System	Topic

Copyright © UWorld. All rights reserved.

A 3-year-old girl is brought to the office due to 2 days of fever and rash. Her mother says the patient has also been refusing to eat or drink. She has no prior medical conditions and is up to date with recommended vaccinations. None of the family members have had recent febrile illness, but the patient recently started attending day care. Temperature is 38.3 C (101 F). Physical examination shows multiple small vesicles and ulcers with an erythematous base on the buccal mucosa and tongue. There are similar vesicular lesions on the distal extremities. Which of the following is the most likely underlying cause of this patient's rash?

- A. Autoantibody-mediated acantholysis
- B. Disseminated enteroviral infection
- C. Idiosyncratic hypersensitivity reaction
- D. Immune response to a bacterial toxin
- E. Medium-sized arterial inflammation

Submit

A 3-year-old girl is brought to the office due to 2 days of fever and rash. Her mother says the patient has also been refusing to eat or drink. She has no prior medical conditions and is up to date with recommended vaccinations. None of the family members have had recent febrile illness, but the patient recently started attending day care. Temperature is 38.3 C (101 F). Physical examination shows multiple small vesicles and ulcers with an erythematous base on the buccal mucosa and tongue. There are similar vesicular lesions on the distal extremities. Which of the following is the most likely underlying cause of this patient's rash?

- A. Autoantibody-mediated acantholysis (6%)
- ✓ B. Disseminated enteroviral infection (70%)
- C. Idiosyncratic hypersensitivity reaction (4%)
- D. Immune response to a bacterial toxin (10%)
- E. Medium-sized arterial inflammation (7%)

Omitted
Correct answer
B

70%
Answered correctly

01 sec
Time Spent

04/07/2020
Last Updated

Explanation

Enterovirus	
Epidemiology	• Infants & young children • Summer season

Enterovirus	
Epidemiology	• Infants & young children • Summer season • Fecal-oral transmission
Clinical features	• Herpangina (oral ulcerations) • Hand-foot-and-mouth disease (oral & extremity ulcerations) • Aseptic meningitis • Myocarditis

This patient's vesicular rash on the buccal mucosa, tongue, and distal extremities likely indicates **hand-foot-and-mouth disease** (HFMD), a common childhood illness caused by species of **Enterovirus** (eg, Coxsackievirus). Transmission largely occurs via the fecal-oral route, and outbreaks are common in **day cares** and elementary schools.

The virus initially replicates in gastrointestinal lymphatic tissue and subsequently **disseminates** through the reticuloendothelial system and bloodstream to other organs (eg, heart, liver, brain, skin). Patients generally develop low-grade fever and the following mucocutaneous findings:

- **Oral enanthem** – painful, erythematous vesicles and ulcers on the tongue and buccal mucosa, which may lead to refusal to eat or drink
- **Skin exanthem** – maculopapular or vesicular lesions on the hands, feet, and extremities

Most cases can be managed with supportive care and resolve spontaneously within a week. However, viral shedding in the stool continues for >6 weeks, which can propagate transmission.

(Choice A) Pemphigus vulgaris is characterized by autoantibody-mediated acantholysis, which leads to the formation of painful mucous membrane and cutaneous erosions. Vesicles on an *erythematous base* would be atypical; in addition, the palms and soles are generally spared and HFMD is far more common in children.

(Choice C) Stevens-Johnson syndrome is a hypersensitivity reaction that is typically triggered by medication (eg, allopurinol) or infection (eg,

This patient's vesicular rash on the buccal mucosa, tongue, and distal extremities likely indicates **hand-foot-and-mouth disease** (HFMD), a common childhood illness caused by species of **Enterovirus** (eg, Coxsackievirus). Transmission largely occurs via the fecal-oral route, and outbreaks are common in **day cares** and elementary schools.

The virus initially replicates in gastrointestinal lymphatic tissue and subsequently **disseminates** through the reticuloendothelial system and bloodstream to other organs (eg, heart, liver, brain, skin). Patients generally develop low-grade fever and the following mucocutaneous findings:

- **Oral enanthem** – painful, erythematous vesicles and ulcers on the tongue and buccal mucosa, which may lead to refusal to eat or drink
- **Skin exanthem** – maculopapular or vesicular lesions on the hands, feet, and extremities

Most cases can be managed with supportive care and resolve spontaneously within a week. However, viral shedding in the stool continues for >6 weeks, which can propagate transmission.

(Choice A) Pemphigus vulgaris is characterized by autoantibody-mediated acantholysis, which leads to the formation of painful mucous membrane and cutaneous erosions. Vesicles on an *erythematous base* would be atypical; in addition, the palms and soles are generally spared and HFMD is far more common in children.

(Choice C) Stevens-Johnson syndrome is a hypersensitivity reaction that is typically triggered by medication (eg, allopurinol) or infection (eg, *Mycoplasma*). It is characterized by necrosis and detachment of the epidermis, leading to high fever; hemorrhagic oral erosions; and coalescing, erythematous skin macules/bullae with purpuric centers.

(Choice D) Scarlet fever is a delayed-type immune response to a pyrogenic exotoxin produced by *Streptococcus pyogenes*. Patients usually have a history of streptococcal infection (eg, pharyngitis, cellulitis) and then develop a diffuse, erythematous, papular rash that has a "sandpaper" quality. Vesicles are not typically seen, and the oral cavity is not usually involved.

(Choice E) Kawasaki disease is an inflammatory childhood vasculitis that primarily affects medium-sized blood vessels. Patients generally have high fever, mucositis (eg, red lips, strawberry tongue), and a macular or targetoid rash. The presence of vesicles and ulcers makes this diagnosis unlikely.

Educational objective:

Hand-foot-and-mouth disease is a common childhood illness characterized by painful, vesicular mouth lesions; ulcers on the extremities; and low

Settings

1
2
3
4
5
6
7
8
9
10
11
12
13
14
15
16
17
18
19
20
21
22
23
24
25
26
27
28
29
30

Item 7 of 40
Question Id: 15550

Mark

Previous | Next | Full Screen | Tutorial | Lab Values | Notes | Calculator | Reverse Color | Text Zoom | Settings

Exhibit Display

Zoom In | Zoom Out | Reset | Add To New Card | Existing Card

Hand, foot, and mouth disease is a common childhood illness characterized by painful, vesicular mouth lesions; ulcers on the extremities; and low

Block Time Remaining: 00:00:30
TUTOR

7 | Feedback | Suspend | End Block

Settings

1
2
3
4
5
6
7
8
9
10
11
12
13
14
15
16
17
18
19
20
21
22
23
24
25
26
27
28
29
30

Item 7 of 40
Question Id: 15550

Mark

Previous | Next | Full Screen | Tutorial | Lab Values | Notes | Calculator | Reverse Color | Text Zoom | Settings

Exhibit Display

Zoom In | Zoom Out | Reset | Add To New Card | Existing Card

Hand, foot, and mouth disease is a common childhood illness characterized by painful, vesicular mouth lesions; ulcers on the extremities; and low

Block Time Remaining: 00:00:30
TUTOR

7 | Feedback | Suspend | End Block

Settings

1
2
3
4
5
6
7
8
9
10
11
12
13
14
15
16
17
18
19
20
21
22
23
24
25
26
27
28
29
30

Item 7 of 40
Question Id: 15550

Mark

Previous | Next | Full Screen | Tutorial | Lab Values | Notes | Calculator | Reverse Color | Text Zoom | Settings

Exhibit Display

Zoom In | Zoom Out | Reset | Add To New Card | Existing Card

Hand-foot-and-mouth disease is a common childhood illness characterized by painful, vesicular mouth lesions; ulcers on the extremities; and low

Block Time Remaining: 00:00:30
TUTOR

7 | Feedback | Suspend | End Block

Settings

1
2
3
4
5
6
7
8
9
10
11
12
13
14
15
16
17
18
19
20
21
22
23
24
25
26
27
28
29
30

Item 7 of 40
Question Id: 15550

Mark

Previous | Next | Full Screen | Tutorial | Lab Values | Notes | Calculator | Reverse Color | Text Zoom | Settings

Exhibit Display

Zoom In | Zoom Out | Reset | Add To New Card | Existing Card

Hand, foot, and mouth disease is a common childhood illness characterized by painful, vesicular mouth lesions; ulcers on the extremities; and low

Block Time Remaining: 00:00:30
TUTOR

7 | Feedback | Suspend | End Block

- **Oral enanthem** – painful, erythematous vesicles and ulcers on the tongue and buccal mucosa, which may lead to refusal to eat or drink
- **Skin exanthem** – maculopapular or vesicular lesions on the hands, feet, and extremities

Most cases can be managed with supportive care and resolve spontaneously within a week. However, viral shedding in the stool continues for >6 weeks, which can propagate transmission.

(Choice A) Pemphigus vulgaris is characterized by autoantibody-mediated acantholysis, which leads to the formation of painful mucous membrane and cutaneous erosions. Vesicles on an *erythematous base* would be atypical; in addition, the palms and soles are generally spared and HFMD is far more common in children.

(Choice C) Stevens-Johnson syndrome is a hypersensitivity reaction that is typically triggered by medication (eg, allopurinol) or infection (eg, *Mycoplasma*). It is characterized by necrosis and detachment of the epidermis, leading to high fever; hemorrhagic oral erosions; and coalescing, erythematous skin macules/bullae with purpuric centers.

(Choice D) Scarlet fever is a delayed-type immune response to a pyrogenic exotoxin produced by *Streptococcus pyogenes*. Patients usually have a history of streptococcal infection (eg, pharyngitis, cellulitis) and then develop a diffuse, erythematous, papular rash that has a "sandpaper" quality. Vesicles are not typically seen, and the oral cavity is not usually involved.

(Choice E) Kawasaki disease is an inflammatory childhood vasculitis that primarily affects medium-sized blood vessels. Patients generally have high fever, mucositis (eg, red lips, strawberry tongue), and a macular or targetoid rash. The presence of vesicles and ulcers makes this diagnosis unlikely.

Educational objective:
Hand-foot-and-mouth disease is a common childhood illness characterized by painful, vesicular mouth lesions; ulcers on the extremities; and low-grade fever. It is caused by the ingestion and subsequent dissemination of an enterovirus (eg, Coxsackievirus).

Pathology	Dermatology	Hand, foot, mouth disease
Subject	System	Topic

Copyright © UWorld. All rights reserved.

A skin lesion on the upper eyelid of a 46-year-old woman is biopsied. Light microscopy of the tissue specimen is shown in the image below.

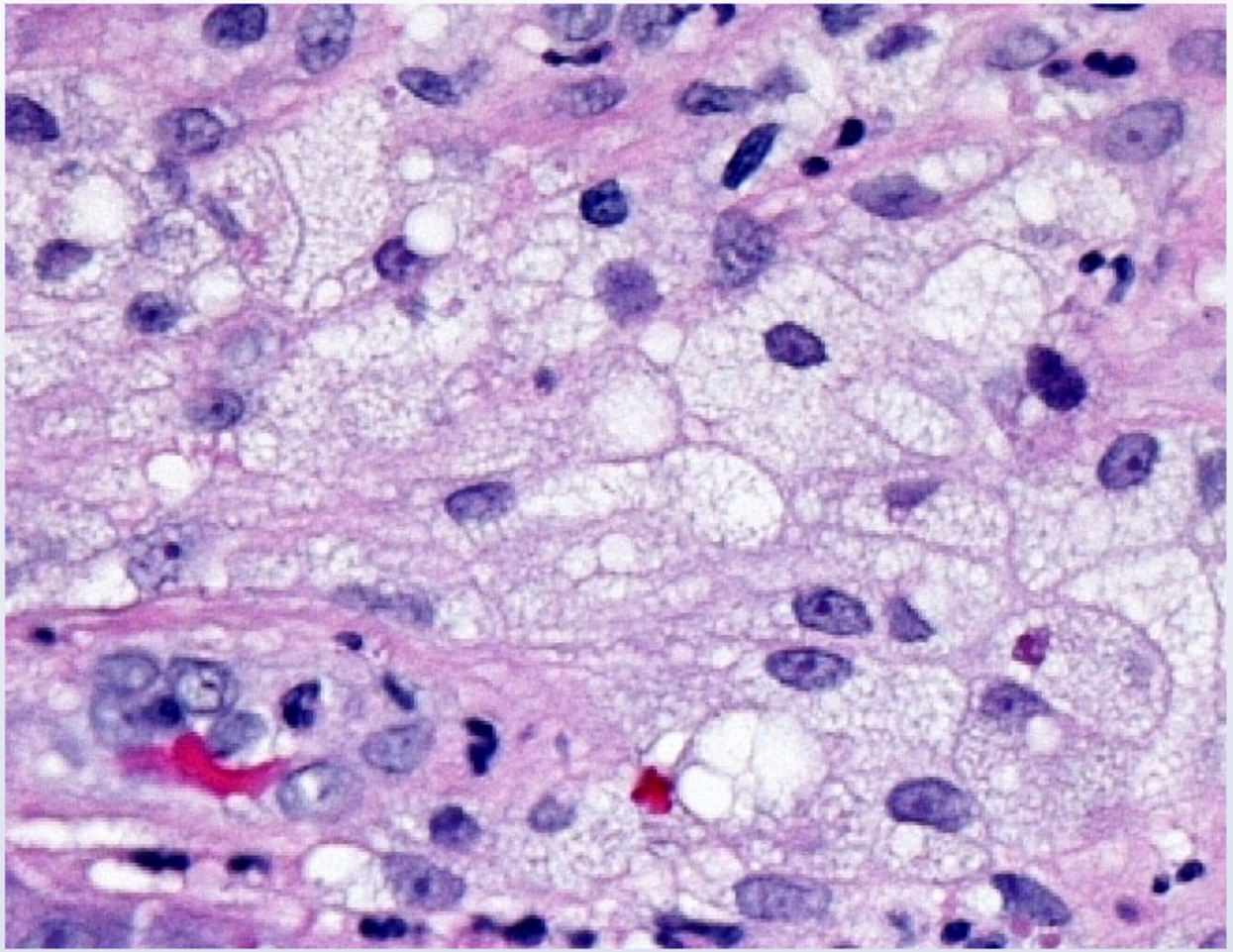

This lesion is most likely to be associated with which of the following conditions?

Settings

1 2 3 4 5 6 7 8 9 10 11 12 13 14 15 16 17 18 19 20 21 22 23 24 25 26 27 28 29 30

Item 8 of 40
Question Id: 1867

Mark | Previous | Next | Full Screen | Tutorial | Lab Values | Notes | Calculator | Reverse Color | Text Zoom | Settings

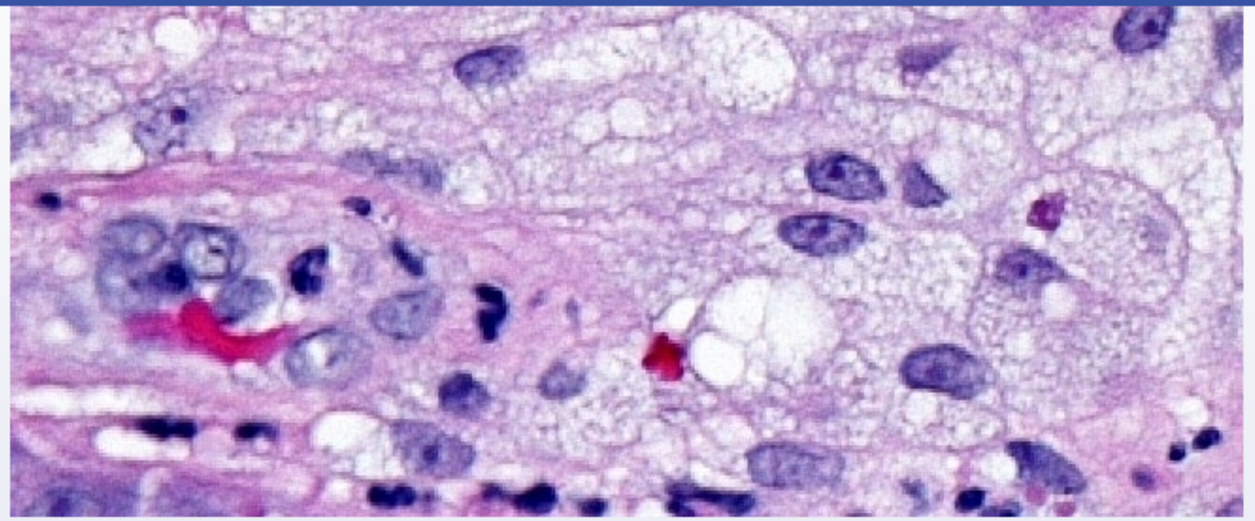

This lesion is most likely to be associated with which of the following conditions?

- A. Ankylosing spondylitis
- B. Hemochromatosis
- C. Hyperthyroidism
- D. Peptic ulcer disease
- E. Polycystic kidney disease
- F. Primary biliary cholangitis

Submit

Block Time Remaining: 00:00:35
TUTOR

4 | Feedback | Suspend | End Block

Settings

1 2 3 4 5 6 7 8 9 10 11 12 13 14 15 16 17 18 19 20 21 22 23 24 25 26 27 28 29 30

Item 8 of 40
Question Id: 1867

Mark | Previous | Next | Full Screen | Tutorial | Lab Values | Notes | Calculator | Reverse Color | Text Zoom | Settings

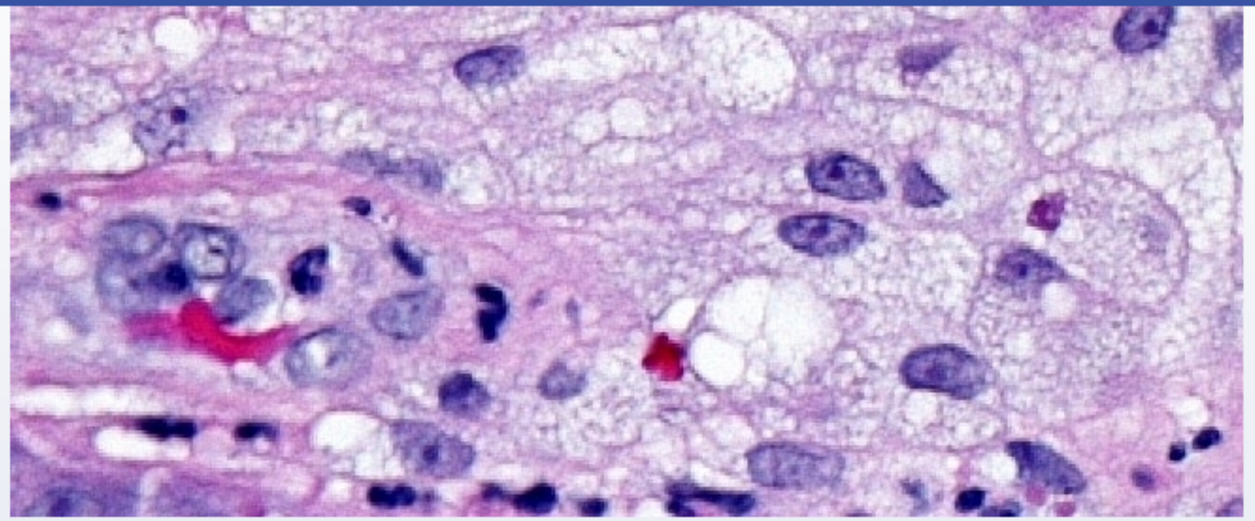

This lesion is most likely to be associated with which of the following conditions?

A. Ankylosing spondylitis (9%)
B. Hemochromatosis (7%)
C. Hyperthyroidism (20%)
D. Peptic ulcer disease (2%)
E. Polycystic kidney disease (7%)
✓ F. Primary biliary cholangitis (53%)

Omitted
Correct answer

53%
Answered correctly

06 secs
Time Spent

04/07/2020
Last Updated

Block Time Remaining: 00:00:36
TUTOR

4 | Feedback | Suspend | End Block

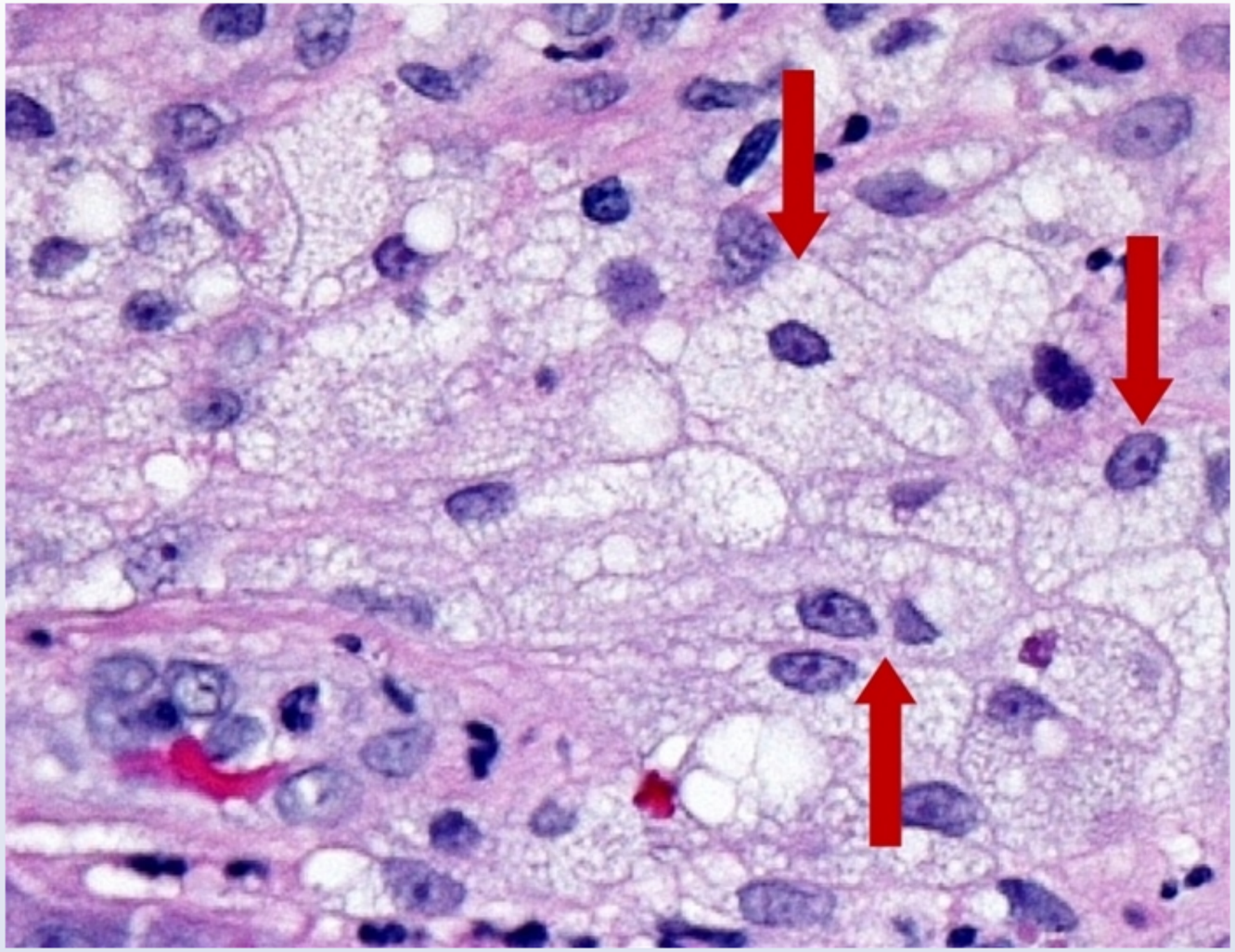

Xanthelasma is a cutaneous lesion commonly found on the eyelid that contains **lipid-laden macrophages** (foam cells, arrows). These papules are typically **yellow** due to the location of the foam cells in the superficial dermis. Xanthelasma and other forms of xanthoma (tuberous, eruptive, tendinous) are classically associated with primary or secondary **hyperlipidemia**. Chronic cholestatic processes including obstructive biliary

Xanthelasma is a cutaneous lesion commonly found on the eyelid that contains **lipid-laden macrophages** (foam cells, arrows). These papules are typically **yellow** due to the location of the foam cells in the superficial dermis. Xanthelasma and other forms of xanthoma (tuberous, eruptive, tendinous) are classically associated with primary or secondary **hyperlipidemia**. Chronic cholestatic processes including obstructive biliary lesions and **primary biliary cholangitis** result in hypercholesterolemia due to leakage of bile back into the circulation, leading to the formation of xanthelasmas. Correction of underlying lipid defects can lead to slow resolution of these lesions.

(Choice A) Ankylosing spondylitis is an HLA-B27-associated spondyloarthropathy that affects primarily young Caucasian males and causes debilitating pain and deformity of the spine and hips.

(Choice B) Hemochromatosis ("bronze diabetes") can cause generalized darkening of the skin due to hemosiderin deposition as well as cutaneous stigmata associated with chronic liver disease (eg, palmar erythema, gynecomastia, spider telangiectasias).

(Choice C) Graves' disease (the most common cause of hyperthyroidism) can present with pretibial myxedema and exophthalmos due to glycosaminoglycan accumulation. However, glycosaminoglycan accumulation occurs within the retroorbital space (not over the eyelids). In addition, hypothyroidism (not hyperthyroidism) is a common cause of hyperlipidemia.

(Choice D) Peptic ulcer disease may occur in multiple endocrine neoplasia 1.

(Choice E) Autosomal dominant polycystic kidney disease causes mild persistent proteinuria that can result in dyslipidemia. However, this is a less common cause of xanthelasma than biliary cirrhosis.

Educational objective:
A yellowish eyelid papule or plaque containing lipid-laden macrophages is most likely xanthelasma. Xanthelasma may occur in association with primary or secondary hyperlipidemia. Cholestatic conditions such as primary biliary cirrhosis are a potential cause of hypercholesterolemia leading to xanthelasma.

Pathology	Dermatology	Primary biliary cholangitis
Subject	System	Topic

Settings

1
2
3
4
5
6
7
8
9
10
11
12
13
14
15
16
17
18
19
20
21
22
23
24
25
26
27
28
29
30

Item 8 of 40
Question Id: 1867

Mark | Previous | Next | Full Screen | Tutorial | Lab Values | Notes | Calculator | Reverse Color | Text Zoom | Settings

Exhibit Display

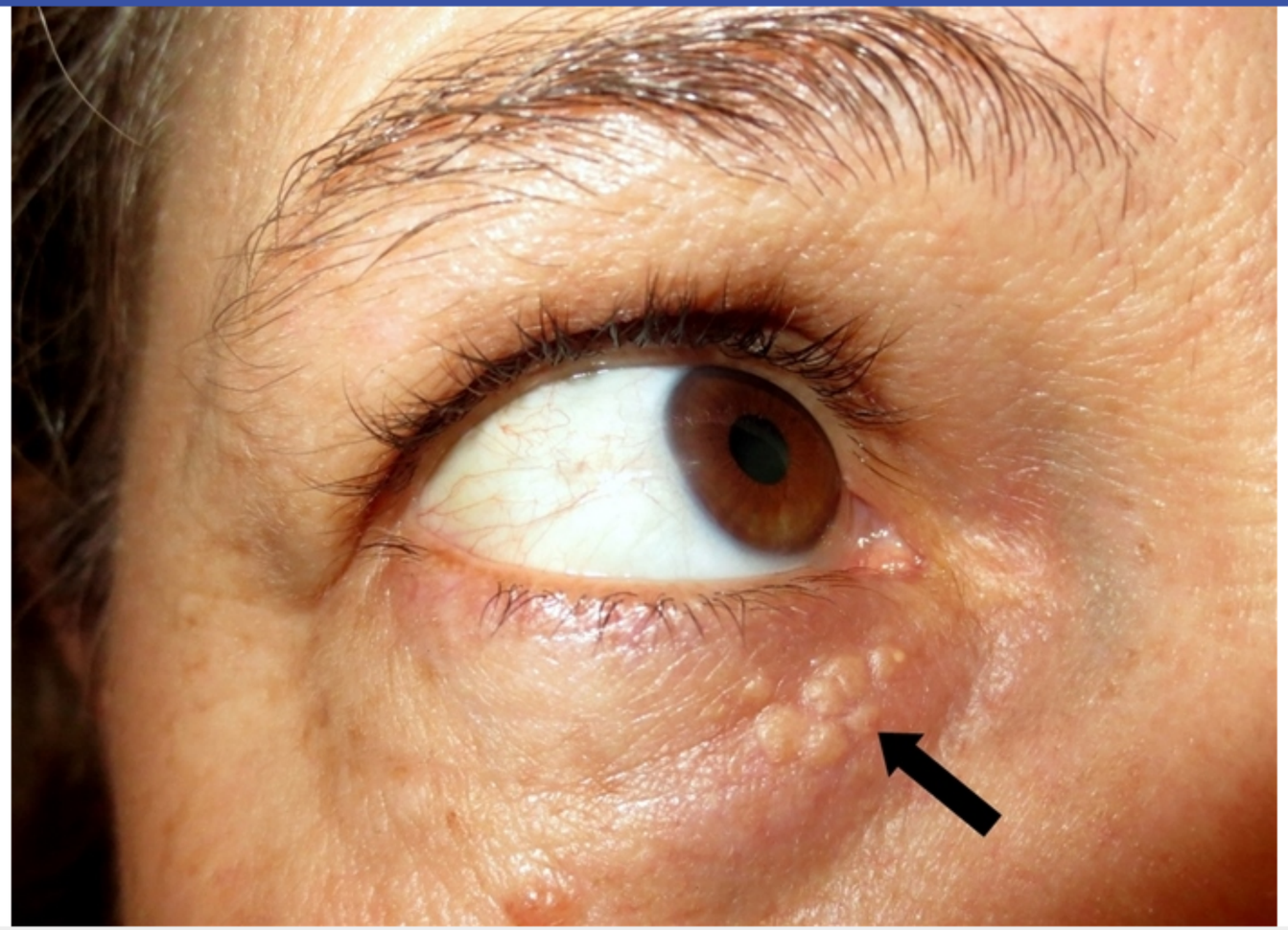

Zoom In | Zoom Out | Reset | Add To New Card | Existing Card

Block Time Remaining: 00:00:36
TUTOR

4 | Feedback | Suspend | End Block

Settings

1
2
3
4
5
6
7
8
9
10
11
12
13
14
15
16
17
18
19
20
21
22
23
24
25
26
27
28
29
30

Item 8 of 40
Question Id: 1867

Mark | Previous | Next | Full Screen | Tutorial | Lab Values | Notes | Calculator | Reverse Color | Text Zoom | Settings

Exhibit Display

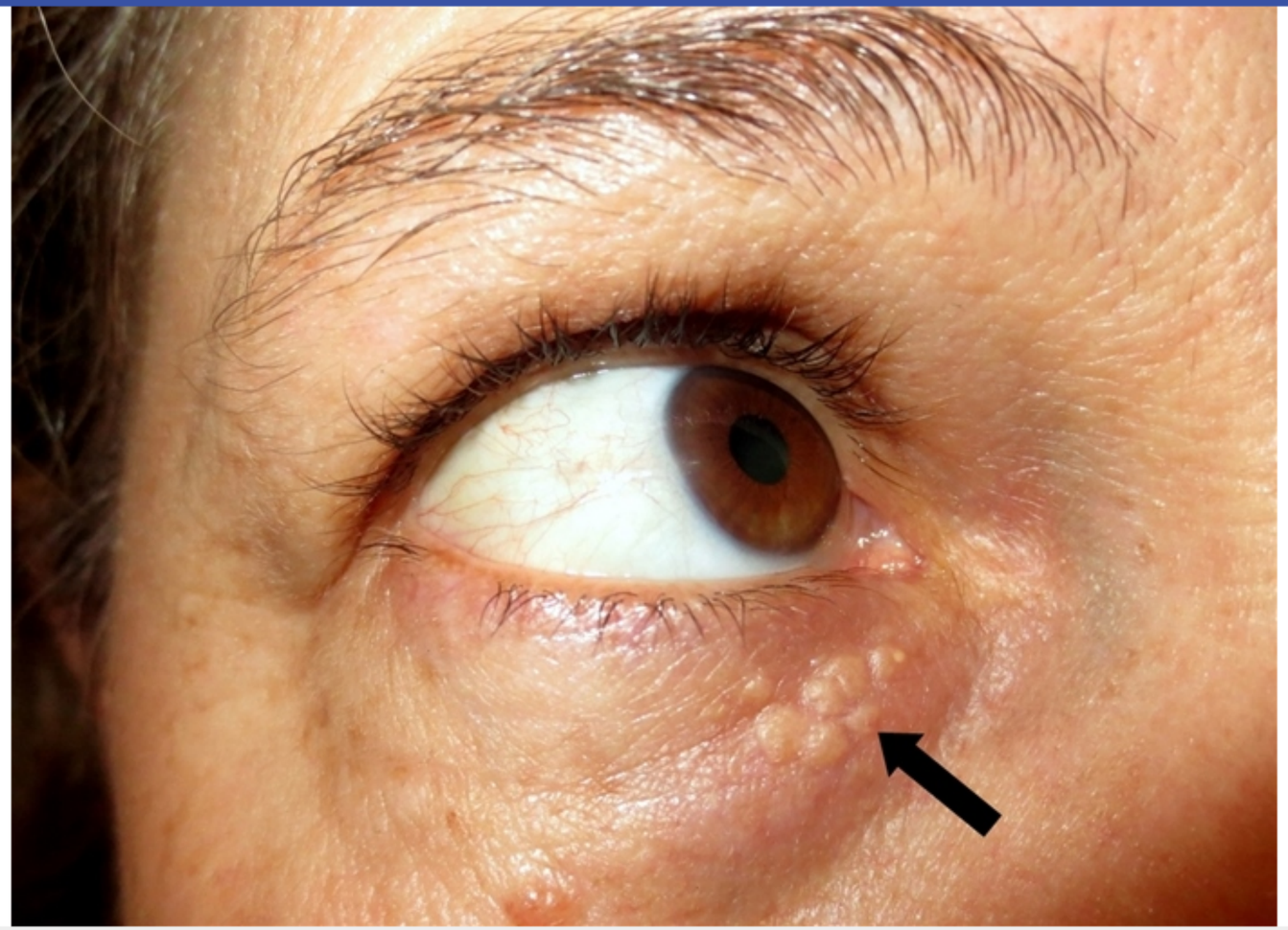

Zoom In | Zoom Out | Reset | Add To New Card | Existing Card

Block Time Remaining: 00:00:36
TUTOR

4 | Feedback | Suspend | End Block

A 25-year-old woman comes to the office due to a 4-week history of a pruritic skin rash. The patient has no chronic medical conditions and takes no medication. Vital signs are normal. On examination, there are pink papules distributed symmetrically over the anterior surfaces of the shins and ankles. Shave biopsy reveals prominent hyperkeratosis with a thickened granular layer. In addition, there is a bandlike infiltrate of mononuclear cells (predominantly lymphocytes) in the subjacent superficial dermis that involves the overlying epidermis. The rete ridges have a sharpened, sawtooth appearance. The basal layer of the epidermis is degenerated, with scattered colloid bodies. Which of the following is the most likely diagnosis?

A. Atopic dermatitis
B. Contact dermatitis
C. Erythema nodosum
D. Lichen planus
E. Psoriasis

Submit

A 25-year-old woman comes to the office due to a 4-week history of a pruritic skin rash. The patient has no chronic medical conditions and takes no medication. Vital signs are normal. On examination, there are pink papules distributed symmetrically over the anterior surfaces of the shins and ankles. Shave biopsy reveals prominent hyperkeratosis with a thickened granular layer. In addition, there is a bandlike infiltrate of mononuclear cells (predominantly lymphocytes) in the subjacent superficial dermis that involves the overlying epidermis. The rete ridges have a sharpened, sawtooth appearance. The basal layer of the epidermis is degenerated, with scattered colloid bodies. Which of the following is the most likely diagnosis?

- A. Atopic dermatitis (4%)
- B. Contact dermatitis (5%)
- C. Erythema nodosum (11%)
- ✓ D. Lichen planus (49%)
- E. Psoriasis (29%)

Omitted
Correct answer
D

49%
Answered correctly

01 sec
Time Spent

06/15/2020
Last Updated

Explanation

1 2 3 4 5 6 7 8 9 10 11 12 13 14 15 16 17 18 19 20 21 22 23 24 25 26 27 28 29 30

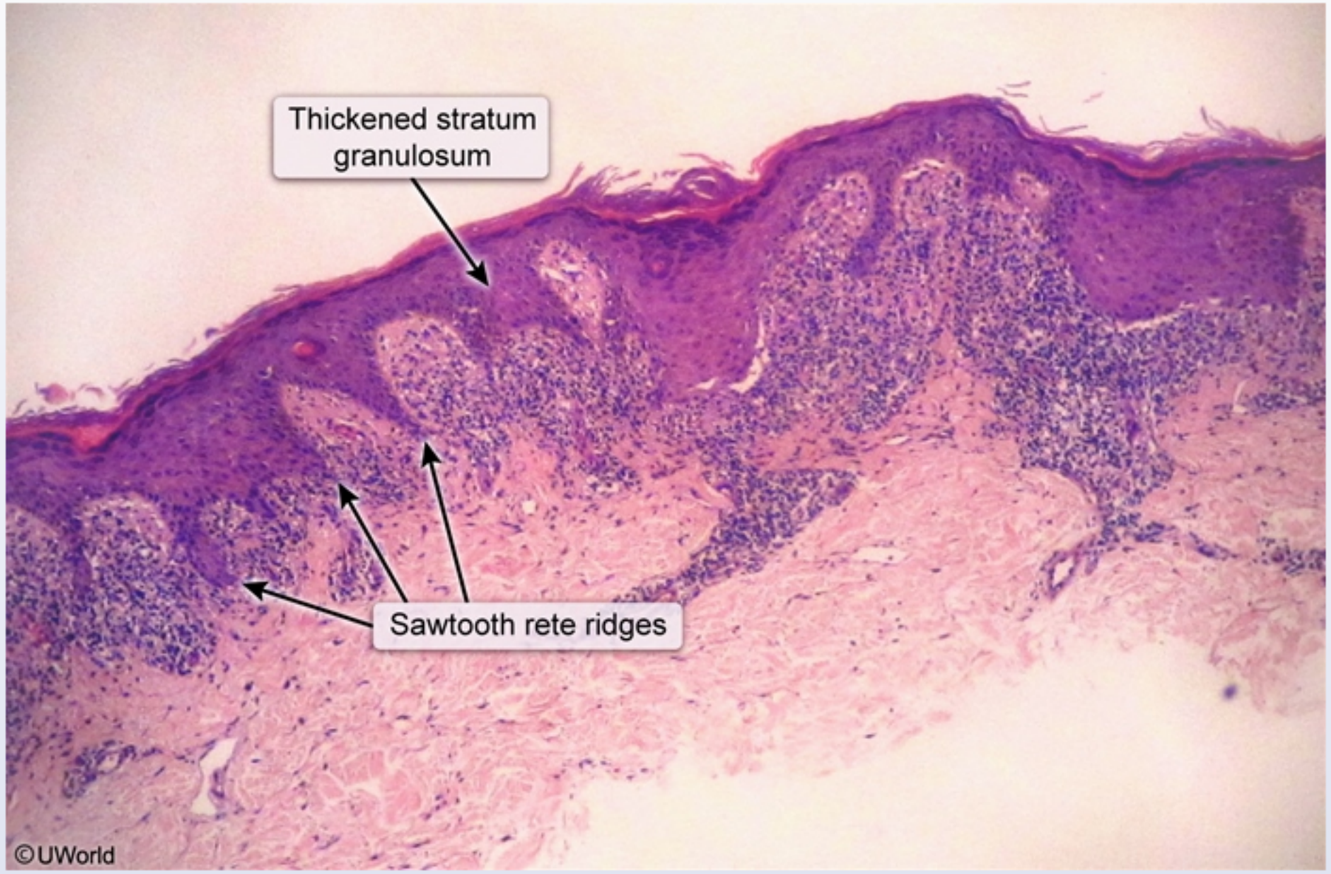

This patient has a pruritic rash consistent with **lichen planus** (LP), an immunologically mediated skin disorder primarily affecting middle-aged adults. The skin lesions typically occur symmetrically on the flexural surfaces of the wrists and ankles but can also involve the nails, oral mucous membranes, and genitalia. The characteristic skin lesions are described by the **5 Ps**: **p**ruritic, **p**urple/pink, **p**olygonal **p**apules and **p**laques and can form along lines of minor trauma (Koebner phenomenon). Chronic lesions often show white, lacy markings known as Wickham striae.

Although the etiology of LP is unknown, it is characterized by a (CD8+) T cell–mediated response to the cells along the junction of the dermis and

This patient has a pruritic rash consistent with **lichen planus** (LP), an immunologically mediated skin disorder primarily affecting middle-aged adults. The skin lesions typically occur symmetrically on the flexural surfaces of the wrists and ankles but can also involve the nails, oral mucous membranes, and genitalia. The characteristic skin lesions are described by the **5 Ps**: **p**ruritic, **p**urple/pink, **p**olygonal **p**apules and **p**laques and can form along lines of minor trauma (Koebner phenomenon). Chronic lesions often show white, lacy markings known as Wickham striae.

Although the etiology of LP is unknown, it is characterized by a (CD8+) T cell–mediated response to the cells along the junction of the dermis and epidermis, resulting in the following characteristic histologic findings:

- Chronic hyperkeratosis (thickening of stratum corneum)
- Lymphocytic infiltrates at the dermoepidermal junction (**interface dermatitis**)
- Scattered eosinophilic, **colloid (Civatte) bodies** in the papillary dermis (apoptotic keratinocytes)
- Thickened stratum granulosum with **sawtooth rete ridges**

(Choices A and B) Atopic dermatitis can cause a pruritic rash affecting the extremities, but it usually presents in childhood and most patients have a history of other atopic disorders (eg, allergic rhinitis, asthma). The lesions in contact dermatitis are also pruritic but occur in localized areas corresponding to the specific exposure (eg, waist with nickel belt buckle exposure). Biopsy in these conditions would show spongiosis (excessive extracellular fluid) in the acute phase and acanthosis (diffuse epidermal hyperplasia) in chronic disease.

(Choice C) Erythema nodosum is a delayed-type hypersensitivity reaction that presents with tender inflammatory nodules in the subcutaneous fat, primarily on the shins. The characteristic histopathology finding is septal panniculitis in the subcutaneous tissues, with a variable (lymphocytes, neutrophils, macrophages) infiltrate.

(Choice E) Psoriasis is an immune-mediated inflammatory disease characterized histologically by cytokine-driven acanthosis (with clubbed rete ridges), keratinocyte hyperproliferation, and parakeratosis (retention of nuclei in stratum corneum). It also demonstrates the Koebner phenomenon but usually presents with chronic erythematous plaques with silvery scales on the extensor surfaces of the knees and elbows, scalp, or neck.

Educational objective:
Lichen planus presents with pruritic, purple/pink, polygonal papules and plaques that can affect the flexural surfaces of the wrists and ankles, along with the nails, oral mucous membranes, and genitalia. Histologic findings include hyperkeratosis, lymphocytic infiltrates at the

Settings

1
2
3
4
5
6
7
8
9
10
11
12
13
14
15
16
17
18
19
20
21
22
23
24
25
26
27
28
29
30

Item 9 of 40
Question Id: 16395

Mark | Previous | Next | Full Screen | Tutorial | Lab Values | Notes | Calculator | Reverse Color | Text Zoom | Settings

Exhibit Display

Zoom In | Zoom Out | Reset | Add To New Card | Existing Card

along with the nails, oral mucous membranes, and genitalia. Histologic findings include hyperkeratosis, lymphocytic infiltrates at the

Block Time Remaining: 00:00:37
TUTOR

8 | Feedback | Suspend | End Block

Settings

1 2 3 4 5 6 7 8 9 10 11 12 13 14 15 16 17 18 19 20 21 22 23 24 25 26 27 28 29 30

Item 9 of 40
Question Id: 16395

Mark | Previous | Next | Full Screen | Tutorial | Lab Values | Notes | Calculator | Reverse Color | Text Zoom | Settings

Exhibit Display

Zoom In | Zoom Out | Reset | Add To New Card | Existing Card

along with the nails, oral mucous membranes, and genitalia. Histologic findings include hyperkeratosis, lymphocytic infiltrates at the

Block Time Remaining: 00:00:37
TUTOR

8 | Feedback | Suspend | End Block

Settings

1
2
3
4
5
6
7
8
9
10
11
12
13
14
15
16
17
18
19
20
21
22
23
24
25
26
27
28
29
30

Item 9 of 40
Question Id: 16395

Mark | Previous | Next | Full Screen | Tutorial | Lab Values | Notes | Calculator | Reverse Color | Text Zoom | Settings

Exhibit Display

Zoom In | Zoom Out | Reset | Add To New Card | Existing Card

along with the nails, oral mucous membranes, and genitalia. Histologic findings include hyperkeratosis, lymphocytic infiltrates at the

Block Time Remaining: 00:00:37
TUTOR

8 | Feedback | Suspend | End Block

Exhibit Display

Lichen planus

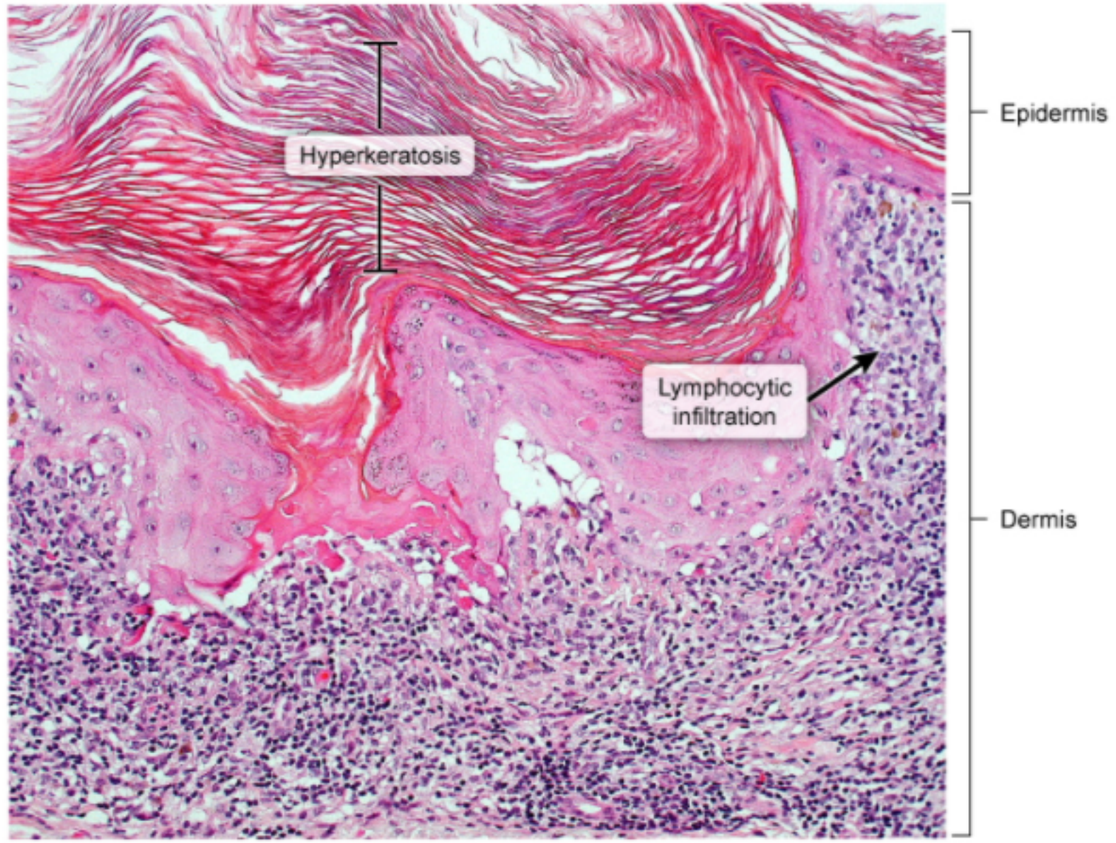

©UWorld

Zoom In Zoom Out Reset Add To New Card | Existing Card

along with the nails, oral mucous membranes, and genitalia. Histologic findings include hyperkeratosis, lymphocytic infiltrates at the

1 2 3 4 5 6 7 8 9 10 11 12 13 14 15 16 17 18 19 20 21 22 23 24 25 26 27 28 29 30

Exhibit Display

Zoom In | Zoom Out | Reset | Add To New Card | Existing Card

along with the nails, oral mucous membranes, and genitalia. Histologic findings include hyperkeratosis, lymphocytic infiltrates at the

1 2 3 4 5 6 7 8 9 10 11 12 13 14 15 16 17 18 19 20 21 22 23 24 25 26 27 28 29 30

Exhibit Display

Zoom In | Zoom Out | Reset | Add To New Card | Existing Card

along with the nails, oral mucous membranes, and genitalia. Histologic findings include hyperkeratosis, lymphocytic infiltrates at the

Exhibit Display

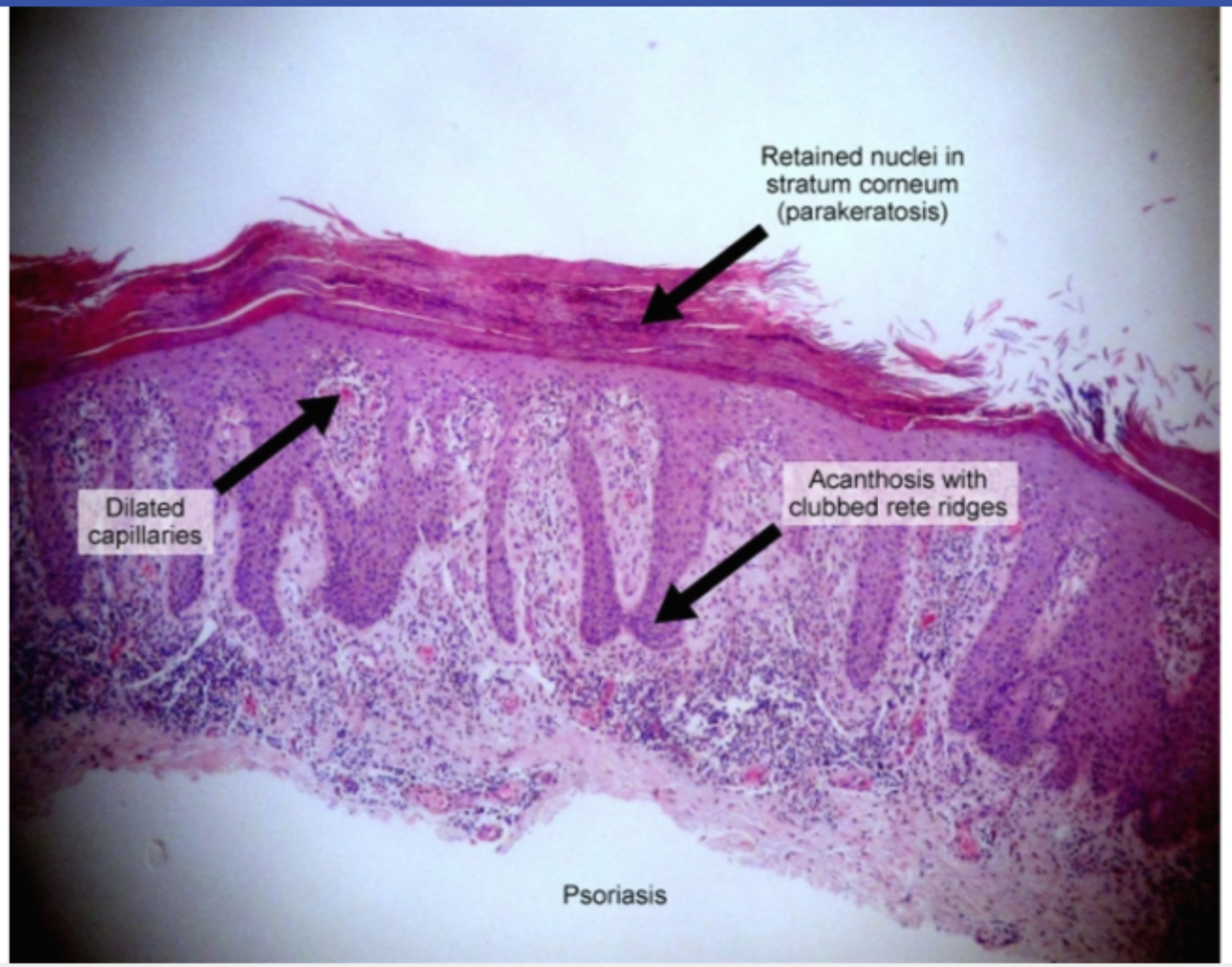

Zoom In | Zoom Out | Reset | Add To New Card | Existing Card

along with the nails, oral mucous membranes, and genitalia. Histologic findings include hyperkeratosis, lymphocytic infiltrates at the

- Scattered eosinophilic, **colloid (Civatte) bodies** in the papillary dermis (apoptotic keratinocytes)
- Thickened stratum granulosum with **sawtooth rete ridges**

(Choices A and B) Atopic dermatitis can cause a pruritic rash affecting the extremities, but it usually presents in childhood and most patients have a history of other atopic disorders (eg, allergic rhinitis, asthma). The lesions in contact dermatitis are also pruritic but occur in localized areas corresponding to the specific exposure (eg, waist with nickel belt buckle exposure). Biopsy in these conditions would show spongiosis (excessive extracellular fluid) in the acute phase and acanthosis (diffuse epidermal hyperplasia) in chronic disease.

(Choice C) Erythema nodosum is a delayed-type hypersensitivity reaction that presents with tender inflammatory nodules in the subcutaneous fat, primarily on the shins. The characteristic histopathology finding is septal panniculitis in the subcutaneous tissues, with a variable (lymphocytes, neutrophils, macrophages) infiltrate.

(Choice E) Psoriasis is an immune-mediated inflammatory disease characterized histologically by cytokine-driven acanthosis (with clubbed rete ridges), keratinocyte hyperproliferation, and parakeratosis (retention of nuclei in stratum corneum). It also demonstrates the Koebner phenomenon but usually presents with chronic erythematous plaques with silvery scales on the extensor surfaces of the knees and elbows, scalp, or neck.

Educational objective:
Lichen planus presents with pruritic, purple/pink, polygonal papules and plaques that can affect the flexural surfaces of the wrists and ankles, along with the nails, oral mucous membranes, and genitalia. Histologic findings include hyperkeratosis, lymphocytic infiltrates at the dermoepidermal junction, thickened stratum granulosum with sawtooth rete ridges, and eosinophilic colloid bodies in the papillary dermis.

References

- Lichen planus and lichenoid dermatoses: clinical overview and molecular basis.

Pathology	Dermatology	Lichen planus
Subject	System	Topic

Copyright © UWorld. All rights reserved.

A 65-year-old man comes to the office due to fatigue, decreased appetite, and weight loss. He has lost 5.4 kg (12 lb) over the last 3 months and eats only small portions of food because he feels full soon after he begins eating. The patient smokes a pack of cigarettes per day and drinks alcohol socially. Blood pressure is 152/90 mm Hg and pulse is 90/min. Physical examination shows a firm, 3-cm lymph node above the left clavicle. There are also numerous skin lesions on his trunk, as shown below, which the patient notes have developed since the onset of his other symptoms.

Settings

1
2
3
4
5
6
7
8
9
10
11
12
13
14
15
16
17
18
19
20
21
22
23
24
25
26
27
28
29
30

Item 10 of 40
Question Id: 7649

Mark | Previous | Next | Full Screen | Tutorial | Lab Values | Notes | Calculator | Reverse Color | Text Zoom | Settings

Block Time Remaining: 00:00:40
TUTOR

7 | Feedback | Suspend | End Block

Settings

1 2 3 4 5 6 7 8 9 10 11 12 13 14 15 16 17 18 19 20 21 22 23 24 25 26 27 28 29 30

Item 10 of 40
Question Id: 7649

Mark | Previous | Next | Full Screen | Tutorial | Lab Values | Notes | Calculator | Reverse Color | Text Zoom | Settings

This patient's skin lesions most likely represent which of the following conditions?

- A. Acanthosis nigricans
- B. Malignant melanoma
- C. Neurofibromatosis
- D. Psoriasis
- E. Seborrheic keratosis
- F. Tuberous sclerosis

Submit

Block Time Remaining: 00:00:42
TUTOR

7 | Feedback | Suspend | End Block

Settings

1
2
3
4
5
6
7
8
9
10
11
12
13
14
15
16
17
18
19
20
21
22
23
24
25
26
27
28
29
30

Item 10 of 40
Question Id: 7649

Mark | Previous | Next | Full Screen | Tutorial | Lab Values | Notes | Calculator | Reverse Color | Text Zoom | Settings

This patient's skin lesions most likely represent which of the following conditions?

- A. Acanthosis nigricans
- B. Malignant melanoma
- C. Neurofibromatosis
- D. Psoriasis
- E. Seborrheic keratosis
- F. Tuberous sclerosis

Submit

Block Time Remaining: 00:00:53
TUTOR

7 | Feedback | Suspend | End Block

This patient's skin lesions most likely represent which of the following conditions?

- A. Acanthosis nigricans (3%)
- B. Malignant melanoma (2%)
- C. Neurofibromatosis (20%)
- D. Psoriasis (0%)
- ✓ E. Seborrheic keratosis (70%)
- F. Tuberous sclerosis (3%)

Omitted
Correct answer

70%
Answered correctly

20 secs
Time Spent

03/01/2020
Last Updated

Explanation

Skin conditions & associated diseases	
Skin conditions	**Important associated conditions**
• Acanthosis nigricans • Multiple skin tags	• Insulin resistance
• Porphyria cutanea tarda • Cutaneous leukocytoclastic vasculitis (palpable purpura) secondary to cryoglobulinemia	• Hepatitis C
• Dermatitis herpetiformis	• Celiac disease
• Recurrent herpes zoster • Disseminated molluscum contagiosum	• Immunosuppression
• Explosive onset of numerous seborrheic keratoses	• Gastrointestinal malignancy
• Pyoderma gangrenosum	• Inflammatory bowel disease

This patient's weight loss, early satiety, positive smoking history, and left supraclavicular adenopathy are concerning for **gastric adenocarcinoma** (GA). Patients with GA can also have epigastric pain, hematemesis, and occult blood loss in the stool. Physical examination findings in advanced (metastatic) disease include left supraclavicular (Virchow node) or left axillary lymphadenopathy, or a periumbilical mass (Sister Mary Joseph nodule).

In addition, **rapid onset** of **numerous seborrheic keratoses** (pigmented macules or plaques with a greasy surface and well-demarcated borders) is a classic **indicator of internal malignancy** (Leser-Trélat sign), particularly GA, and is thought to occur in response to increased tumor production of cytokines or growth factors (eg, IGF-1, fibroblast growth factor). Acanthosis nigricans (a hyperpigmented skin disorder typically

(GA). Patients with GA can also have epigastric pain, hematemesis, and occult blood loss in the stool. Physical examination findings in advanced (metastatic) disease include left supraclavicular (Virchow node) or left axillary lymphadenopathy, or a periumbilical mass (Sister Mary Joseph nodule).

In addition, **rapid onset** of **numerous seborrheic keratoses** (pigmented macules or plaques with a greasy surface and well-demarcated borders) is a classic **indicator of internal malignancy** (Leser-Trélat sign), particularly GA, and is thought to occur in response to increased tumor production of cytokines or growth factors (eg, IGF-1, fibroblast growth factor). Acanthosis nigricans (a hyperpigmented skin disorder typically associated with insulin resistance) can also occur in malignancy due to a similar mechanism **(Choice A)**.

(Choice B) Melanoma characteristically presents as an asymmetric, pigmented lesion with an irregular border, variable coloration, and change in size and appearance over time. Lesions that are multifocal, monotonous, and otherwise asymptomatic are more typical of seborrheic keratoses.

(Choice C) Cutaneous neurofibromas are soft, mobile tumors that are occasionally hyperpigmented. They are often solitary and sporadic, although numerous lesions may occur in neurofibromatosis types 1 and 2. However, these inherited disorders typically present in childhood or young adulthood, and type 1 (the more common type) is also characterized by axillary freckling, café-au-lait macules, and iris hamartomas.

(Choice D) Psoriasis is an inflammatory dermatosis characterized by well-demarcated plaques with silvery scales. It can affect the trunk but is more common on extensor surfaces of the extremities. Explosive onset of psoriasis is associated with HIV infection.

(Choice F) Tuberous sclerosis is an inherited neurocutaneous syndrome. Cutaneous findings include hypopigmented macules, periungual fibromas, connective tissue nevi, forehead fibrous plaques, and facial angiofibromas.

Educational objective:
Seborrheic keratoses are pigmented macules or plaques with a greasy surface and well-demarcated borders. Rapid onset of numerous lesions is an indicator of internal malignancy (Leser-Trélat sign), especially gastric adenocarcinoma.

Pathology	Dermatology	Seborrheic keratosis
Subject	System	Topic

Copyright © UWorld. All rights reserved.

Settings

1 2 3 4 5 6 7 8 9 10 11 12 13 14 15 16 17 18 19 20 21 22 23 24 25 26 27 28 29 30

Item 10 of 40
Question Id: 7649

Mark | Previous | Next | Full Screen | Tutorial | Lab Values | Notes | Calculator | Reverse Color | Text Zoom | Settings

(GA). Patients with GA can also have epigastric pain, hematemesis, and occult blood loss in the stool. Physical examination findings in advanced

Exhibit Display

Zoom In | Zoom Out | Reset | Add To New Card | Existing Card

Block Time Remaining: 00:00:57
TUTOR

7 | Feedback | Suspend | End Block

Settings

1 2 3 4 5 6 7 8 9 10 11 12 13 14 15 16 17 18 19 20 21 22 23 24 25 26 27 28 29 30

Item 10 of 40
Question Id: 7649

Mark | Previous | Next | Full Screen | Tutorial | Lab Values | Notes | Calculator | Reverse Color | Text Zoom | Settings

(GA). Patients with GA can also have epigastric pain, hematemesis, and occult blood loss in the stool. Physical examination findings in advanced

Exhibit Display

Zoom In | Zoom Out | Reset | Add To New Card | Existing Card

Block Time Remaining: 00:00:57
TUTOR

7 | Feedback | Suspend | End Block

Settings

1 2 3 4 5 6 7 8 9 10 11 12 13 14 15 16 17 18 19 20 21 22 23 24 25 26 27 28 29 30

Item 10 of 40
Question Id: 7649

Mark | Previous | Next | Full Screen | Tutorial | Lab Values | Notes | Calculator | Reverse Color | Text Zoom | Settings

(GA). Patients with GA can also have epigastric pain, hematemesis, and occult blood loss in the stool. Physical examination findings in advanced

Exhibit Display

Zoom In | Zoom Out | Reset | Add To New Card | Existing Card

Block Time Remaining: 00:00:57
TUTOR

7 | Feedback | Suspend | End Block

Settings

1 2 3 4 5 6 7 8 9 10 11 12 13 14 15 16 17 18 19 20 21 22 23 24 25 26 27 28 29 30

Item 10 of 40
Question Id: 7649

Mark | Previous | Next | Full Screen | Tutorial | Lab Values | Notes | Calculator | Reverse Color | Text Zoom | Settings

(GA). Patients with GA can also have epigastric pain, hematemesis, and occult blood loss in the stool. Physical examination findings in advanced

Exhibit Display

Zoom In | Zoom Out | Reset | Add To New Card | Existing Card

Block Time Remaining: 00:00:57
TUTOR

7 | Feedback | Suspend | End Block

Settings

1 2 3 4 5 6 7 8 9 10 11 12 13 14 15 16 17 18 19 20 21 22 23 24 25 26 27 28 29 30

Item 10 of 40
Question Id: 7649

Mark | Previous | Next | Full Screen | Tutorial | Lab Values | Notes | Calculator | Reverse Color | Text Zoom | Settings

(GA). Patients with GA can also have epigastric pain, hematemesis, and occult blood loss in the stool. Physical examination findings in advanced

Exhibit Display

Zoom In | Zoom Out | Reset | Add To New Card | Existing Card

Block Time Remaining: 00:00:57
TUTOR

7 | Feedback | Suspend | End Block

A 14-month-old girl is brought to the clinic by her parents due to sores on her feet. Since she took her first steps 3 months ago, she has had blisters involving the soles of the feet, which subsequently break down and heal slowly. The patient had failure to thrive as an infant due to frequent oral ulcerations but otherwise has been healthy and has achieved normal developmental milestones. Examination shows small bullae at the soles with faint erythema and no scarring. Biopsy taken at the margin of a blister shows an intraepidermal cleavage plane. Which of the following most likely contributes to the pathogenesis of this patient's condition?

A. Autoantibodies against tissue transglutaminase

B. Impaired keratin filament assembly

C. Loss of function mutation in filaggrin

D. T-cell–mediated hypersensitivity reaction

Submit

A 14-month-old girl is brought to the clinic by her parents due to sores on her feet. Since she took her first steps 3 months ago, she has had blisters involving the soles of the feet, which subsequently break down and heal slowly. The patient had failure to thrive as an infant due to frequent oral ulcerations but otherwise has been healthy and has achieved normal developmental milestones. Examination shows small bullae at the soles with faint erythema and no scarring. Biopsy taken at the margin of a blister shows an intraepidermal cleavage plane. Which of the following most likely contributes to the pathogenesis of this patient's condition?

- A. Autoantibodies against tissue transglutaminase (15%)
- ✓ B. Impaired keratin filament assembly (38%)
- C. Loss of function mutation in filaggrin (27%)
- D. T-cell–mediated hypersensitivity reaction (18%)

Omitted
Correct answer
B

38%
Answered correctly

02 secs
Time Spent

06/09/2020
Last Updated

Explanation

Epidermolysis bullosa	
Etiology	• Inherited disorders • Mutations involving intraepidermal & dermoepidermal adhesion complexes
	• Onset in infancy/childhood

Epidermolysis bullosa	
Etiology	• Inherited disorders • Mutations involving intraepidermal & dermoepidermal adhesion complexes
Clinical features	• Onset in infancy/childhood • Bullae, erosions & ulcers • Lesions triggered by friction or minor trauma • Histopathology: intraepidermal cleavage most common
Complications	• Malnutrition • Infection

Epidermolysis bullosa (EB) is a group of inherited disorders caused by mutations involving intraepidermal and dermoepidermal adhesion complexes in the basement membrane zone. It is characterized by epithelial fragility (eg, bullae, erosions, ulcers) triggered by minor trauma. Light microscopy of skin biopsy typically shows intraepidermal cleavage, although the plane of cleavage can vary based on subtype.

The most common form of EB, EB simplex, is caused by **mutations in keratin genes** that impair the assembly of keratin into filaments. It presents early in life with **friction-induced blisters** at the palms and soles and other exposed areas. Lesions typically heal with no residual scarring, although patients may have chronic thickening of the skin of the feet. Infants with EB simplex may develop **oral blisters** with bottle-feeding.

(Choice A) Dermatitis herpetiformis is caused by autoantibodies against tissue transglutaminase. It presents with small, intensely pruritic vesicles on the elbows, knees, and buttocks and is typically seen in patients with gluten-sensitive enteropathy (ie, celiac disease).

(Choice C) Atopic dermatitis is a multifactorial disorder but is commonly seen in association with loss of function mutations in filaggrin and other epidermal barrier proteins. Infants have red, crusted lesions at the extensor surfaces and face, whereas older children and adults have pruritic patches and lichenification at flexural areas.

(Choice D) A delayed T-cell–mediated hypersensitivity reaction is responsible for allergic contact dermatitis (eg, poison ivy/rhus dermatitis), which

complexes in the basement membrane zone. It is characterized by epithelial fragility (eg, bullae, erosions, ulcers) triggered by minor trauma. Light microscopy of skin biopsy typically shows intraepidermal cleavage, although the plane of cleavage can vary based on subtype.

The most common form of EB, EB simplex, is caused by **mutations in keratin genes** that impair the assembly of keratin into filaments. It presents early in life with **friction-induced blisters** at the palms and soles and other exposed areas. Lesions typically heal with no residual scarring, although patients may have chronic thickening of the skin of the feet. Infants with EB simplex may develop **oral blisters** with bottle-feeding.

(Choice A) Dermatitis herpetiformis is caused by autoantibodies against tissue transglutaminase. It presents with small, intensely pruritic vesicles on the elbows, knees, and buttocks and is typically seen in patients with gluten-sensitive enteropathy (ie, celiac disease).

(Choice C) Atopic dermatitis is a multifactorial disorder but is commonly seen in association with loss of function mutations in filaggrin and other epidermal barrier proteins. Infants have red, crusted lesions at the extensor surfaces and face, whereas older children and adults have pruritic patches and lichenification at flexural areas.

(Choice D) A delayed T-cell–mediated hypersensitivity reaction is responsible for allergic contact dermatitis (eg, poison ivy/rhus dermatitis), which presents acutely with pruritic vesicles at sites of contact.

Educational objective:
Epidermolysis bullosa is a group of inherited disorders characterized by epithelial fragility (eg, bullae, erosions, ulcers) triggered by minor trauma. It is caused by mutations affecting proteins in the intraepidermal and dermoepidermal adhesion complexes; keratin mutations are responsible for the most common form (EB simplex).

References

- Hereditary epidermolysis bullosa.

Pathology	Dermatology	Epidermolysis bullosa
Subject	System	Topic

Copyright © UWorld. All rights reserved.

Settings

1 2 3 4 5 6 7 8 9 10 11 12 13 14 15 16 17 18 19 20 21 22 23 24 25 26 27 28 29 30

Item 11 of 40
Question Id: 16852

Mark | Previous | Next | Full Screen | Tutorial | Lab Values | Notes | Calculator | Reverse Color | Text Zoom | Settings

- Onset in infancy/childhood

Exhibit Display

Zoom In | Zoom Out | Reset | Add To Flash Card

It is caused by mutations affecting proteins in the intraepidermal and dermoepidermal adhesion complexes; keratin mutations are responsible for

Block Time Remaining: 00:00:59
TUTOR

0 | Feedback | Suspend | End Block

A 58-year-old man comes to the physician for evaluation of skin lesions on his forehead. He says that he first noticed the lesions when he was rubbing his forehead because of their roughness. His medical problems include hypertension that is well controlled with chlorthalidone. He has worked as a construction foreman for 32 years. Physical examination shows the findings seen in the image below.

Which of the following is the most likely diagnosis?

- A. Actinic keratosis
- B. Atopic dermatitis
- C. Pityriasis rosea
- D. Psoriasis
- E. Seborrheic keratosis

Submit

A 58-year-old man comes to the physician for evaluation of skin lesions on his forehead. He says that he first noticed the lesions when he was rubbing his forehead because of their roughness. His medical problems include hypertension that is well controlled with chlorthalidone. He has worked as a construction foreman for 32 years. Physical examination shows the findings seen in the image below.

1
2
3
4
5
6
7
8
9
10
11
12
13
14
15
16
17
18
19
20
21
22
23
24
25
26
27
28
29
30

worked as a construction foreman for 32 years. Physical examination shows the findings seen in the image below.

Which of the following is the most likely diagnosis?

A. Actinic keratosis

Settings

1
2
3
4
5
6
7
8
9
10
11
12
13
14
15
16
17
18
19
20
21
22
23
24
25
26
27
28
29
30

Item 12 of 40
Question Id: 935

Mark | Previous | Next | Full Screen | Tutorial | Lab Values | Notes | Calculator | Reverse Color | Text Zoom | Settings

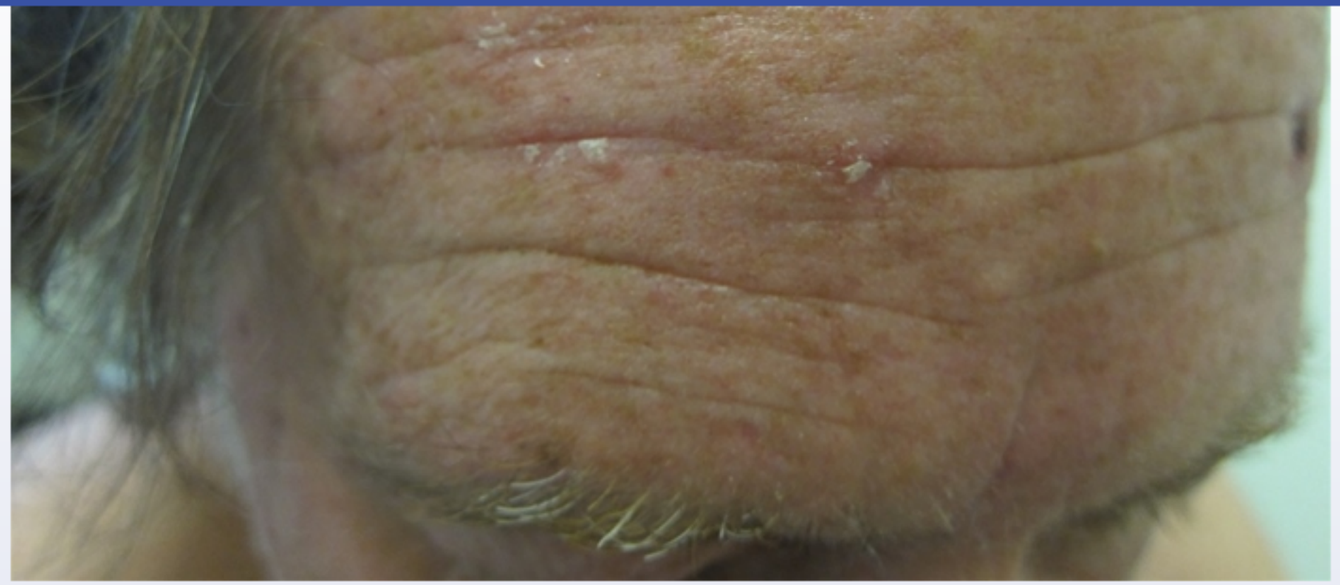

Which of the following is the most likely diagnosis?

A. Actinic keratosis

B. Atopic dermatitis

C. Pityriasis rosea

D. Psoriasis

E. Seborrheic keratosis

Submit

Block Time Remaining: 00:01:07
TUTOR

12 | Feedback | Suspend | End Block

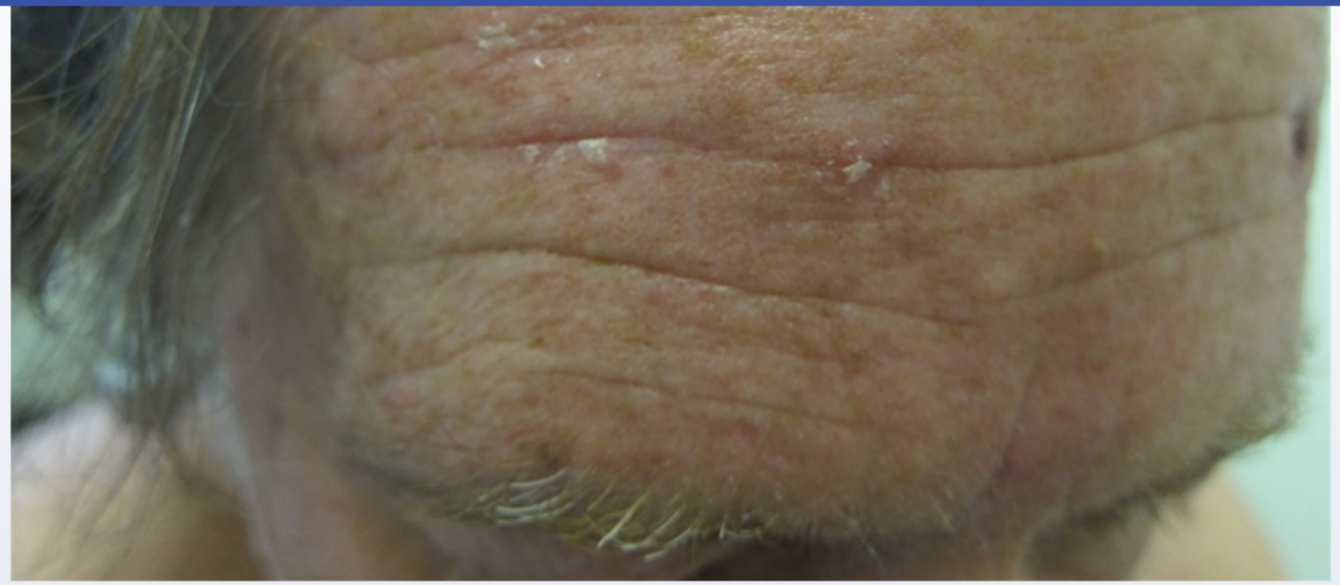

Which of the following is the most likely diagnosis?

- ✓ A. Actinic keratosis (82%)
- B. Atopic dermatitis (3%)
- C. Pityriasis rosea (1%)
- D. Psoriasis (3%)
- E. Seborrheic keratosis (9%)

Omitted
Correct answer

82%
Answered correctly

10 secs
Time Spent

06/26/2020
Last Updated

Explanation

This patient has **actinic keratoses (AKs)**, which most commonly present as **erythematous papules** with overlying **whitish scale**. They are often "felt more than seen" and have a rough, **sandpaper-like texture** on palpation. The lesions are small and flat at first, but may enlarge and become elevated. Usually their size does not exceed 10 mm in diameter. Hyperkeratosis in such lesions may become prominent and form cutaneous horns.

AKs develop in genetically predisposed individuals age 40-60 under the influence of **excessive sun exposure**. The most commonly affected areas are the face, ears, scalp, and the dorsa of the arms and hands, but any other chronically sun-exposed site (legs, back, upper chest) can be involved. AK is regarded as a **premalignant condition**, but less than 1% of AKs per year will evolve into invasive squamous cell carcinoma.

(Choice B) Acute atopic dermatitis occurs most often in infants and children and manifests with highly pruritic erythematous papules and plaques. Light microscopy demonstrates spongiosis (edema of the epidermis).

(Choice C) Pityriasis rosea often begins as a solitary pink or brown scaly plaque with central clearing on the trunk, neck, or extremities (herald patch). It is followed by development of an ovoid maculopapular rash with lesions classically oriented in an oblique direction along the skin tension lines on the back (Christmas tree pattern).

(Choice D) Psoriasis presents with well-circumscribed raised papules and plaques covered with a thick silvery scale. The lesions are located on the scalp, trunk, and extensor areas of the extremities (elbows and knees).

(Choice E) Seborrheic keratoses occur in elderly individuals and present with "stuck-on", deeply pigmented or flesh-colored lesions with a velvety or "greasy" surface.

Educational objective:
Actinic keratosis (AK) develops on chronically sun-exposed areas of the skin in predisposed individuals. The lesions consist of erythematous papules with a central scale and a rough "sandpaper-like" texture. AKs are considered premalignant lesions and have the potential to progress to squamous cell carcinoma.

Pathology	Dermatology	Actinic keratoses
Subject	System	Topic

Settings

1
2
3
4
5
6
7
8
9
10
11
12
13
14
15
16
17
18
19
20
21
22
23
24
25
26
27
28
29
30

Item 12 of 40
Question Id: 935

Mark | Previous | Next | Full Screen | Tutorial | Lab Values | Notes | Calculator | Reverse Color | Text Zoom | Settings

Explanation

Exhibit Display

Cutaneous horns Cutaneous horns

Zoom In | Zoom Out | Reset | Add To New Card | Existing Card

Block Time Remaining: 00:01:09
TUTOR

12 | Feedback | Suspend | End Block

Settings

1
2
3
4
5
6
7
8
9
10
11
12
13
14
15
16
17
18
19
20
21
22
23
24
25
26
27
28
29
30

Item 12 of 40
Question Id: 935

Mark | Previous | Next | Full Screen | Tutorial | Lab Values | Notes | Calculator | Reverse Color | Text Zoom | Settings

Explanation

Exhibit Display

Cutaneous horns Cutaneous horns

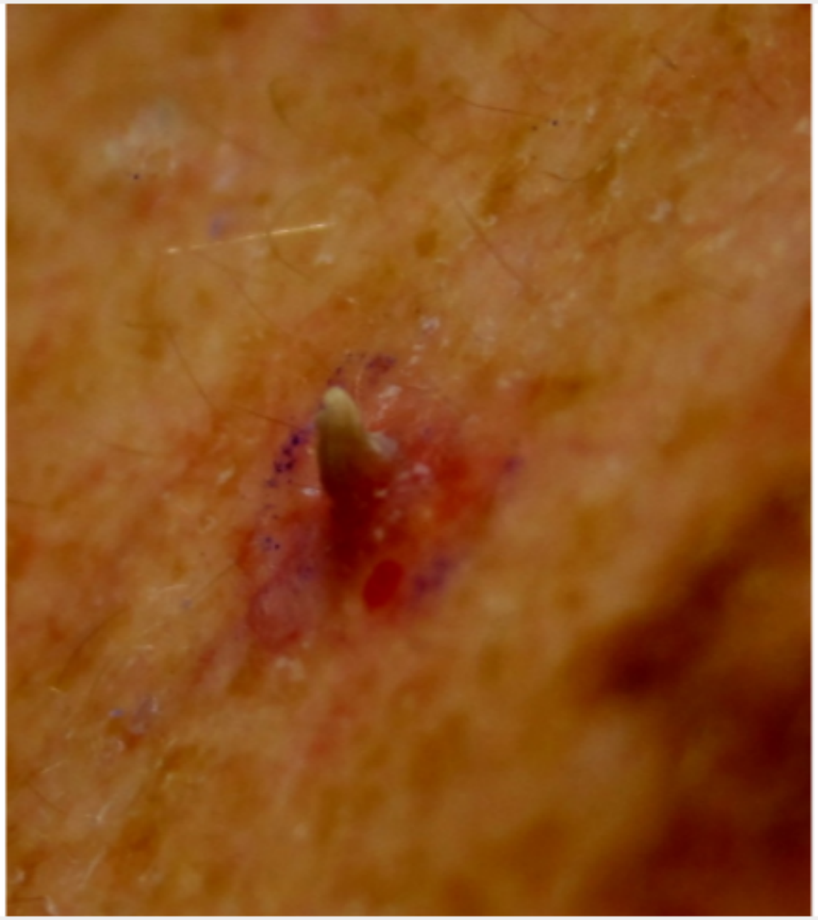

Zoom In | Zoom Out | Reset | Add To New Card | Existing Card

Block Time Remaining: 00:01:09
TUTOR

12 | Feedback | Suspend | End Block

1 2 3 4 5 6 7 8 9 10 11 12 13 14 15 16 17 18 19 20 21 22 23 24 25 26 27 28 29 30

"felt more than seen" and have a rough, **sandpaper-like texture** on palpation. The lesions are small and flat at first, but may enlarge and become

Exhibit Display

Severe eczema exacerbation Eczema (atopic dermatitis)

Zoom In | Zoom Out | Reset | Add To New Card | Existing Card

Settings

1 2 3 4 5 6 7 8 9 10 11 12 13 14 15 16 17 18 19 20 21 22 23 24 25 26 27 28 29 30

Item 12 of 40
Question Id: 935

Mark | Previous | Next | Full Screen | Tutorial | Lab Values | Notes | Calculator | Reverse Color | Text Zoom | Settings

"felt more than seen" and have a rough, **sandpaper-like texture** on palpation. The lesions are small and flat at first, but may enlarge and become

Exhibit Display

Severe eczema exacerbation Eczema (atopic dermatitis)

Zoom In | Zoom Out | Reset | Add To New Card | Existing Card

Block Time Remaining: 00:01:09
TUTOR

12 | Feedback | Suspend | End Block

Settings

1 2 3 4 5 6 7 8 9 10 11 12 13 14 15 16 17 18 19 20 21 22 23 24 25 26 27 28 29 30

Item 12 of 40
Question Id: 935

Mark | Previous | Next | Full Screen | Tutorial | Lab Values | Notes | Calculator | Reverse Color | Text Zoom | Settings

"felt more than seen" and have a rough, **sandpaper-like texture** on palpation. The lesions are small and flat at first, but may enlarge and become

Exhibit Display

Zoom In | Zoom Out | Reset | Add To New Card | Existing Card

Block Time Remaining: 00:01:09
TUTOR

12 | Feedback | Suspend | End Block

1 2 3 4 5 6 7 8 9 10 11 12 13 14 15 16 17 18 19 20 21 22 23 24 25 26 27 28 29 30

"felt more than seen" and have a rough, **sandpaper-like texture** on palpation. The lesions are small and flat at first, but may enlarge and become

Exhibit Display

Psoriasis Plaque psoriasis

Zoom In | Zoom Out | Reset | Add To New Card | Existing Card

Settings

1 2 3 4 5 6 7 8 9 10 11 12 13 14 15 16 17 18 19 20 21 22 23 24 25 26 27 28 29 30

Item 12 of 40
Question Id: 935

Mark | Previous | Next | Full Screen | Tutorial | Lab Values | Notes | Calculator | Reverse Color | Text Zoom | Settings

"felt more than seen" and have a rough, **sandpaper-like texture** on palpation. The lesions are small and flat at first, but may enlarge and become

Exhibit Display

Seborrheic Keratoses Seborrheic keratosis, irritated

Zoom In | Zoom Out | Reset | Add To New Card | Existing Card

Block Time Remaining: 00:01:09
TUTOR

12 | Feedback | Suspend | End Block

1 2 3 4 5 6 7 8 9 10 11 12 13 14 15 16 17 18 19 20 21 22 23 24 25 26 27 28 29 30

"felt more than seen" and have a rough, **sandpaper-like texture** on palpation. The lesions are small and flat at first, but may enlarge and become

Exhibit Display

Seborrheic Keratoses Seborrheic keratosis, irritated

Zoom In | Zoom Out | Reset | Add To New Card | Existing Card

A 36-year-old man comes to the office due to a 2-month history of pruritic skin rash over the elbows and knees. The patient has been using skin emollients, but the lesions have not improved. He also has a prolonged history of episodic abdominal discomfort, flatulence, and voluminous greasy stools. Cardiopulmonary examination is normal. The abdomen is soft and nontender. Skin examination shows a papulovesicular skin rash in groups with erosion and excoriations. Which of the following is most likely to be seen in this patient?

A. Crypt abscesses in colonic mucosa

B. IgG-mediated skin disruption

C. Increased intestinal intraepithelial lymphocytes

D. Increased urinary porphyrins

E. Pancreatic beta-cell dysfunction

Submit

A 36-year-old man comes to the office due to a 2-month history of pruritic skin rash over the elbows and knees. The patient has been using skin emollients, but the lesions have not improved. He also has a prolonged history of episodic abdominal discomfort, flatulence, and voluminous greasy stools. Cardiopulmonary examination is normal. The abdomen is soft and nontender. Skin examination shows a papulovesicular skin rash in groups with erosion and excoriations. Which of the following is most likely to be seen in this patient?

- A. Crypt abscesses in colonic mucosa (20%)
- B. IgG-mediated skin disruption (11%)
- ✓ C. Increased intestinal intraepithelial lymphocytes (62%)
- D. Increased urinary porphyrins (3%)
- E. Pancreatic beta-cell dysfunction (2%)

Omitted
Correct answer
C

62%
Answered correctly

02 secs
Time Spent

01/22/2020
Last Updated

Explanation

Explanation

Dermatitis herpetiformis (DH) is characterized by erythematous pruritic papules, vesicles, and bullae that appear bilaterally and symmetrically on the extensor surfaces (eg, elbows, knees), upper back, and buttocks. The term "herpetiformis" refers to the resemblance of the clustered vesicular lesions to those seen in herpes simplex virus infections. Histologically, dermatitis herpetiformis is characterized by **microabscesses** containing fibrin and neutrophils at the **dermal papillae tips**. The overlying basal cells become vacuolated, and coalescing blisters form at the tips of the

Dermatitis herpetiformis (DH) is characterized by erythematous pruritic papules, vesicles, and bullae that appear bilaterally and symmetrically on the extensor surfaces (eg, elbows, knees), upper back, and buttocks. The term "herpetiformis" refers to the resemblance of the clustered vesicular lesions to those seen in herpes simplex virus infections. Histologically, dermatitis herpetiformis is characterized by **microabscesses** containing fibrin and neutrophils at the **dermal papillae tips**. The overlying basal cells become vacuolated, and coalescing blisters form at the tips of the involved papillae.

The pathogenesis of DH involves the formation of **IgA antibodies** against **gliadin** (a protein unique to the gluten portion of wheat) or a gliadin/tissue transglutaminase complex in the intestine. These antibodies appear to cause clinical disease by cross-reacting with epidermal transglutaminase. DH is strongly associated with **celiac disease**, which is characterized by **increased intraepithelial lymphocytes**, a variable loss of villus height, and crypt hyperplasia, leading to clinical features of malabsorption (eg, steatorrhea). A gluten-free diet tends to improve both the enteropathy and dermatitis.

(Choice A) Ulcerative colitis is characterized by mucosal inflammation, crypt abscesses, and ulcerations. Common dermal associations of ulcerative colitis include erythema nodosum and pyoderma gangrenosum.

(Choice B) IgG-mediated skin disruption is seen in pemphigus vulgaris and bullous pemphigoid. These conditions are characterized by bullous and often ulcerating lesions. Pemphigus vulgaris may involve the pharynx and esophagus, but neither condition is associated with steatorrhea.

(Choice D) Elevated urinary porphyrin levels (uroporphyrin, heptacarboxyl porphyrin) are seen in porphyria cutanea tarda. This condition is characterized by skin fragility and blistering lesions in sun-exposed areas.

(Choice E) Common dermatologic manifestations of diabetes mellitus include skin tags, acanthosis nigricans, and necrobiosis lipoidica diabeticorum.

Educational objective:
Dermatitis herpetiformis is characterized by erythematous pruritic papules, vesicles, and bullae that appear bilaterally and symmetrically on the

involved papillae.

The pathogenesis of DH involves the formation of **IgA antibodies** against **gliadin** (a protein unique to the gluten portion of wheat) or a gliadin/tissue transglutaminase complex in the intestine. These antibodies appear to cause clinical disease by cross-reacting with epidermal transglutaminase. DH is strongly associated with **celiac disease**, which is characterized by **increased intraepithelial lymphocytes**, a variable loss of villus height, and crypt hyperplasia, leading to clinical features of malabsorption (eg, steatorrhea). A gluten-free diet tends to improve both the enteropathy and dermatitis.

(Choice A) Ulcerative colitis is characterized by mucosal inflammation, crypt abscesses, and ulcerations. Common dermal associations of ulcerative colitis include erythema nodosum and pyoderma gangrenosum.

(Choice B) IgG-mediated skin disruption is seen in pemphigus vulgaris and bullous pemphigoid. These conditions are characterized by bullous and often ulcerating lesions. Pemphigus vulgaris may involve the pharynx and esophagus, but neither condition is associated with steatorrhea.

(Choice D) Elevated urinary porphyrin levels (uroporphyrin, heptacarboxyl porphyrin) are seen in porphyria cutanea tarda. This condition is characterized by skin fragility and blistering lesions in sun-exposed areas.

(Choice E) Common dermatologic manifestations of diabetes mellitus include skin tags, acanthosis nigricans, and necrobiosis lipoidica diabeticorum.

Educational objective:
Dermatitis herpetiformis is characterized by erythematous pruritic papules, vesicles, and bullae that appear bilaterally and symmetrically on the extensor surfaces. Dermatitis herpetiformis is strongly associated with celiac disease.

References

- Dermatitis herpetiformis.

Pathology	Dermatology	Dermatitis herpetiformis
Subject	System	Topic

Copyright © UWorld. All rights reserved.

Settings

1 2 3 4 5 6 7 8 9 10 11 12 13 14 15 16 17 18 19 20 21 22 23 24 25 26 27 28 29 30

Item 13 of 40
Question Id: 1111

Mark | Previous | Next | Full Screen | Tutorial | Lab Values | Notes | Calculator | Reverse Color | Text Zoom | Settings

Exhibit Display

Zoom In | Zoom Out | Reset | Add To New Card | Existing Card

Dermatitis herpetiformis is characterized by erythematous pruritic papules, vesicles, and bullae that appear bilaterally and symmetrically on the

Block Time Remaining: 00:01:11
TUTOR

10 | Feedback | Suspend | End Block

Settings

1 2 3 4 5 6 7 8 9 10 11 12 13 14 15 16 17 18 19 20 21 22 23 24 25 26 27 28 29 30

Item 13 of 40
Question Id: 1111

Mark | Previous | Next | Full Screen | Tutorial | Lab Values | Notes | Calculator | Reverse Color | Text Zoom | Settings

Exhibit Display

Zoom In | Zoom Out | Reset | Add To New Card | Existing Card

Dermatitis herpetiformis is characterized by erythematous pruritic papules, vesicles, and bullae that appear bilaterally and symmetrically on the

Block Time Remaining: 00:01:11
TUTOR

10 | Feedback | Suspend | End Block

Settings

1 2 3 4 5 6 7 8 9 10 11 12 13 14 15 16 17 18 19 20 21 22 23 24 25 26 27 28 29 30

Item 13 of 40
Question Id: 1111

Mark | Previous | Next | Full Screen | Tutorial | Lab Values | Notes | Calculator | Reverse Color | Text Zoom | Settings

Exhibit Display

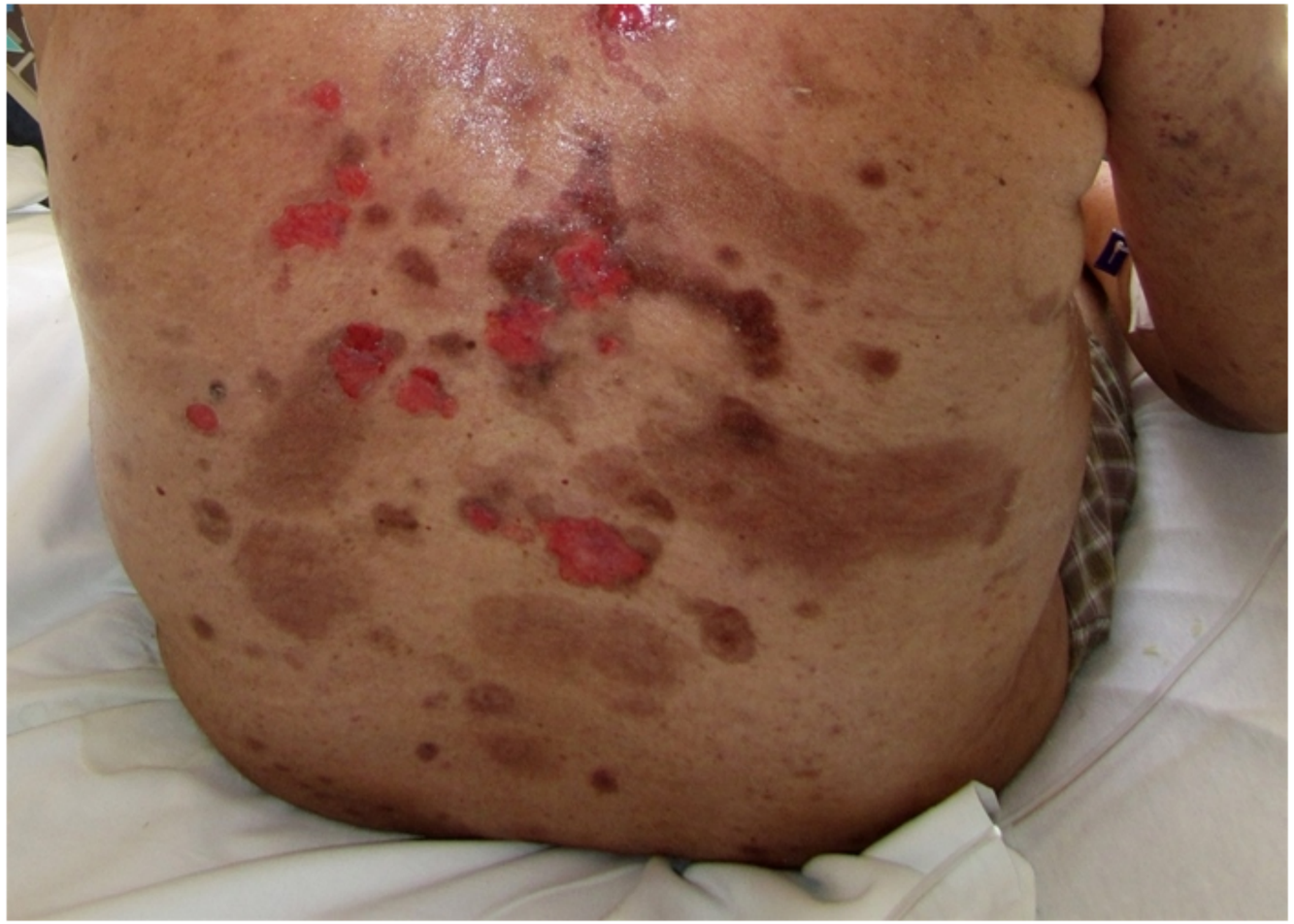

Zoom In | Zoom Out | Reset | Add To New Card | Existing Card

Dermatitis herpetiformis is characterized by erythematous pruritic papules, vesicles, and bullae that appear bilaterally and symmetrically on the

Block Time Remaining: 00:01:11
TUTOR

10 | Feedback | Suspend | End Block

Settings

1
2
3
4
5
6
7
8
9
10
11
12
13
14
15
16
17
18
19
20
21
22
23
24
25
26
27
28
29
30

Item 13 of 40
Question Id: 1111

Mark | Previous | Next | Full Screen | Tutorial | Lab Values | Notes | Calculator | Reverse Color | Text Zoom | Settings

Exhibit Display

Zoom In | Zoom Out | Reset | Add To New Card | Existing Card

Dermatitis herpetiformis is characterized by erythematous pruritic papules, vesicles, and bullae that appear bilaterally and symmetrically on the

Block Time Remaining: 00:01:11
TUTOR

10 | Feedback | Suspend | End Block

Settings

1 2 3 4 5 6 7 8 9 10 11 12 13 14 15 16 17 18 19 20 21 22 23 24 25 26 27 28 29 30

Item 13 of 40
Question Id: 1111

Mark | Previous | Next | Full Screen | Tutorial | Lab Values | Notes | Calculator | Reverse Color | Text Zoom | Settings

Exhibit Display

Zoom In | Zoom Out | Reset | Add To New Card | Existing Card

Dermatitis herpetiformis is characterized by erythematous pruritic papules, vesicles, and bullae that appear bilaterally and symmetrically on the

Block Time Remaining: 00:01:11
TUTOR

10 | Feedback | Suspend | End Block

Settings

1
2
3
4
5
6
7
8
9
10
11
12
13
14
15
16
17
18
19
20
21
22
23
24
25
26
27
28
29
30

Item 13 of 40
Question Id: 1111

Mark | Previous | Next | Full Screen | Tutorial | Lab Values | Notes | Calculator | Reverse Color | Text Zoom | Settings

Exhibit Display

Zoom In | Zoom Out | Reset | Add To New Card | Existing Card

Dermatitis herpetiformis is characterized by erythematous pruritic papules, vesicles, and bullae that appear bilaterally and symmetrically on the

Block Time Remaining: 00:01:11
TUTOR

10 | Feedback | Suspend | End Block

Settings

1 2 3 4 5 6 7 8 9 10 11 12 13 14 15 16 17 18 19 20 21 22 23 24 25 26 27 28 29 30

Item 13 of 40
Question Id: 1111

Mark | Previous | Next | Full Screen | Tutorial | Lab Values | Notes | Calculator | Reverse Color | Text Zoom | Settings

Exhibit Display

Zoom In | Zoom Out | Reset | Add To New Card | Existing Card

Dermatitis herpetiformis is characterized by erythematous pruritic papules, vesicles, and bullae that appear bilaterally and symmetrically on the

Block Time Remaining: 00:01:11
TUTOR

10 | Feedback | Suspend | End Block

The pathogenesis of DH involves the formation of **IgA antibodies** against **gliadin** (a protein unique to the gluten portion of wheat) or a gliadin/tissue transglutaminase complex in the intestine. These antibodies appear to cause clinical disease by cross-reacting with epidermal transglutaminase. DH is strongly associated with **celiac disease**, which is characterized by **increased intraepithelial lymphocytes**, a variable loss of villus height, and crypt hyperplasia, leading to clinical features of malabsorption (eg, steatorrhea). A gluten-free diet tends to improve both the enteropathy and dermatitis.

(Choice A) Ulcerative colitis is characterized by mucosal inflammation, crypt abscesses, and ulcerations. Common dermal associations of ulcerative colitis include erythema nodosum and pyoderma gangrenosum.

(Choice B) IgG-mediated skin disruption is seen in pemphigus vulgaris and bullous pemphigoid. These conditions are characterized by bullous and often ulcerating lesions. Pemphigus vulgaris may involve the pharynx and esophagus, but neither condition is associated with steatorrhea.

(Choice D) Elevated urinary porphyrin levels (uroporphyrin, heptacarboxyl porphyrin) are seen in porphyria cutanea tarda. This condition is characterized by skin fragility and blistering lesions in sun-exposed areas.

(Choice E) Common dermatologic manifestations of diabetes mellitus include skin tags, acanthosis nigricans, and necrobiosis lipoidica diabeticorum.

Educational objective:
Dermatitis herpetiformis is characterized by erythematous pruritic papules, vesicles, and bullae that appear bilaterally and symmetrically on the extensor surfaces. Dermatitis herpetiformis is strongly associated with celiac disease.

References

- Dermatitis herpetiformis.

Pathology	Dermatology	Dermatitis herpetiformis
Subject	System	Topic

Copyright © UWorld. All rights reserved.

A 37-year-old man comes to the office due to a rash. For the last several months, he has had numerous small lesions on the hands. The lesions are associated with occasional mild itching and bleed slightly if inadvertently struck against furniture or a wall. Examination findings are as shown in the exhibit. Which of the following is the most likely diagnosis?

A. Atopic dermatitis

B. Cutaneous warts

C. Lichen planus

D. Psoriasis

E. Tinea infection

Submit

A 37-year-old man comes to the office due to a rash. For the last several months, he has had numerous small lesions on the hands. The lesions are associated with occasional mild itching and bleed slightly if inadvertently struck against furniture or a wall. Examination findings are as shown in the exhibit. Which of the following is the most likely diagnosis?

- A. Atopic dermatitis (1%)
- B. Cutaneous warts (7%)
- C. Lichen planus (12%)
- ✓ D. Psoriasis (74%)
- E. Tinea infection (3%)

Omitted
Correct answer
D

74%
Answered correctly

02 secs
Time Spent

04/15/2020
Last Updated

Explanation

This patient has chronic, well-demarcated, erythematous plaques with a thick scale consistent with **plaque psoriasis**. Psoriasis is a common inflammatory skin disorder characterized by hyperkeratosis (overgrowth of the stratum corneum) and epidermal hyperplasia. It has a strong genetic predisposition and is often seen in patients with a family history of the disorder; other risk factors include smoking, heavy alcohol consumption, and obesity.

Psoriasis has multiple variants (eg, guttate, pustular); however, up to 75% of cases are due to chronic plaque psoriasis. Plaques are well-defined and **erythematous** and may appear raised above the surrounding skin. They are typically covered in a coarse **silver scale**, which, when

This patient has chronic, well-demarcated, erythematous plaques with a thick scale consistent with **plaque psoriasis**. Psoriasis is a common inflammatory skin disorder characterized by hyperkeratosis (overgrowth of the stratum corneum) and epidermal hyperplasia. It has a strong genetic predisposition and is often seen in patients with a family history of the disorder; other risk factors include smoking, heavy alcohol consumption, and obesity.

Psoriasis has multiple variants (eg, guttate, pustular); however, up to 75% of cases are due to chronic plaque psoriasis. Plaques are well-defined and **erythematous** and may appear raised above the surrounding skin. They are typically covered in a coarse **silver scale**, which, when removed, results in **pinpoint bleeding** (Auspitz sign) of the underlying dilated capillaries.

Plaques usually form in locations subject to trauma or friction **(Köbner phenomenon)**; the extensor surfaces of the elbows and knees are most classic, but the dorsal surface of the hands, as in this patient, is also common. Other typical locations include the scalp, back, and gluteal cleft. They are often **mildly pruritic** but may be asymptomatic.

(Choice A) Atopic dermatitis can present with erythematous, scaly plaques, but it is more common in flexural areas, shows less prominent scaling, and is usually associated with more prominent itching.

(Choice B) Cutaneous warts (verruca vulgaris) are caused by human papillomavirus infection and present as discrete, hyperkeratotic papules. Although patients can have multiple warts, numerous scaly plaques are more consistent with psoriasis.

(Choice C) Lichen planus presents with pink or purple plaques and papules. It is usually associated with severe pruritis and typically affects the volar surface of the wrists rather than the dorsum of the hands.

(Choice E) Tinea manuum presents with scaly plaques on the hands. The lesions are typically very pruritic and often have an annular appearance with central clearing.

Educational objective:
Psoriasis is a common inflammatory skin disorder characterized by hyperkeratosis (overgrowth of the stratum corneum) and epidermal hyperplasia. Plaque psoriasis is the most common form and presents with chronic, well-demarcated, erythematous plaques with a thick, silver scale.

1 2 3 4 5 6 7 8 9 10 11 12 13 14 15 16 17 18 19 20 21 22 23 24 25 26 27 28 29 30

This patient has chronic, well-demarcated, erythematous plaques with a thick scale consistent with **plaque psoriasis**. Psoriasis is a common

Exhibit Display

Zoom In | Zoom Out | Reset | Add To New Card | Existing Card

Pathology Dermatology Psoriasis

Settings

1 2 3 4 5 6 7 8 9 10 11 12 13 14 15 16 17 18 19 20 21 22 23 24 25 26 27 28 29 30

Item 14 of 40
Question Id: 17062

Mark | Previous | Next | Full Screen | Tutorial | Lab Values | Notes | Calculator | Reverse Color | Text Zoom | Settings

This patient has chronic, well-demarcated, erythematous plaques with a thick scale consistent with **plaque psoriasis**. Psoriasis is a common

Exhibit Display

Zoom In | Zoom Out | Reset | Add To New Card | Existing Card

Pathology Dermatology Psoriasis

Block Time Remaining: 00:01:13
TUTOR

5 | Feedback | Suspend | End Block

Settings

1 2 3 4 5 6 7 8 9 10 11 12 13 14 15 16 17 18 19 20 21 22 23 24 25 26 27 28 29 30

Item 14 of 40
Question Id: 17062

Mark | Previous | Next | Full Screen | Tutorial | Lab Values | Notes | Calculator | Reverse Color | Text Zoom | Settings

This patient has chronic, well-demarcated, erythematous plaques with a thick scale consistent with **plaque psoriasis**. Psoriasis is a common

Exhibit Display

Zoom In | Zoom Out | Reset | Add To New Card | Existing Card

Pathology Dermatology Psoriasis

Block Time Remaining: 00:01:13
TUTOR

5 | Feedback | Suspend | End Block

Settings

1 2 3 4 5 6 7 8 9 10 11 12 13 14 15 16 17 18 19 20 21 22 23 24 25 26 27 28 29 30

Item 14 of 40
Question Id: 17062

Mark | Previous | Next | Full Screen | Tutorial | Lab Values | Notes | Calculator | Reverse Color | Text Zoom | Settings

This patient has chronic, well-demarcated, erythematous plaques with a thick scale consistent with **plaque psoriasis**. Psoriasis is a common

Exhibit Display

Zoom In | Zoom Out | Reset | Add To New Card | Existing Card

Pathology Dermatology Psoriasis

Block Time Remaining: 00:01:13
TUTOR

5 | Feedback | Suspend | End Block

Settings

1 2 3 4 5 6 7 8 9 10 11 12 13 14 15 16 17 18 19 20 21 22 23 24 25 26 27 28 29 30

Item 14 of 40
Question Id: 17062

Mark | Previous | Next | Full Screen | Tutorial | Lab Values | Notes | Calculator | Reverse Color | Text Zoom | Settings

This patient has chronic, well-demarcated, erythematous plaques with a thick scale consistent with **plaque psoriasis**. Psoriasis is a common

Exhibit Display

Zoom In | Zoom Out | Reset | Add To New Card | Existing Card

Pathology Dermatology Psoriasis

Block Time Remaining: 00:01:13
TUTOR

5 | Feedback | Suspend | End Block

A 47-year-old woman comes to the office due to an itchy rash. For the last 3 months, she has had a gradual onset of multiple pruritic lesions at her wrists, legs, and ankles. The patient tried treating the lesions with emollients and topical over-the-counter hydrocortisone but had no relief. Examination shows scattered, scaly, pink papules and plaques as shown in the exhibit. Which of the following is the most likely diagnosis?

A. Actinic keratosis

B. Atopic dermatitis

C. Irritant contact dermatitis

D. Lichen planus

E. Psoriasis

Submit

A 47-year-old woman comes to the office due to an itchy rash. For the last 3 months, she has had a gradual onset of multiple pruritic lesions at her wrists, legs, and ankles. The patient tried treating the lesions with emollients and topical over-the-counter hydrocortisone but had no relief. Examination shows scattered, scaly, pink papules and plaques as shown in the exhibit. Which of the following is the most likely diagnosis?

- A. Actinic keratosis (8%)
- B. Atopic dermatitis (3%)
- C. Irritant contact dermatitis (2%)
- ✓ D. Lichen planus (61%)
- E. Psoriasis (25%)

Omitted
Correct answer
D

61%
Answered correctly

02 secs
Time Spent

05/22/2020
Last Updated

Explanation

Lichen planus	
Clinical findings	• **5 "Ps":** pruritic, purple/pink, polygonal, papules & plaques • Lacy, white network of lines (Wickham striae) • **Locations:** ◦ Skin (eg, ankles, wrists)

Lichen planus	

Clinical findings	• **5 "Ps":** pruritic, purple/pink, polygonal, papules & plaques
	• Lacy, white network of lines (Wickham striae)
	• **Locations:**
	  ◦ Skin (eg, ankles, wrists)
	  ◦ Oral mucosa (white papules & plaques ± erythema, mucosal atrophy, ulcers)
	  ◦ Genitalia

Pathologic findings	• Hyperkeratosis • Lymphocytic interface dermatitis • Eosinophilic colloid (Civatte) bodies • Thickened stratum granulosum, sawtooth rete ridges
Natural history	• Chronic symptoms • Formation of lesions at sites of trauma (Köbner phenomenon) • Resolution within 2 yr (mucosal lesions may persist/recur)

This patient has **lichen planus (LP)**, an immune-mediated condition that typically presents with **pruritic**, **pink papules** and plaques. LP lesions often have lacy, scaly, **white markings** (Wickham striae) and can form at sites of minor trauma (Köbner phenomenon). The skin lesions typically occur symmetrically on the flexural surfaces of the wrists and ankles but can also involve the nails, oral mucous membranes, and genitalia.

The pathologic process in LP is characterized by a ($CD8^+$) **T cell–mediated response** to cells along the junction of the dermis and epidermis. Although the etiology is unknown, the risk may be increased in patients with hepatitis C and those taking certain medications (eg, ACE inhibitors, thiazide diuretics). LP typically follows a chronic course with gradual, spontaneous remission within 2 years.

(Choice A) Actinic keratosis presents with small, hyperkeratotic plaques in sun-exposed areas (eg, forehead, cheeks). It is most common in patients age >60, and itching is atypical.

This patient has **lichen planus (LP)**, an immune-mediated condition that typically presents with **pruritic**, **pink papules** and plaques. LP lesions often have lacy, scaly, **white markings** (Wickham striae) and can form at sites of minor trauma (Köbner phenomenon). The skin lesions typically occur symmetrically on the flexural surfaces of the wrists and ankles but can also involve the nails, oral mucous membranes, and genitalia.

The pathologic process in LP is characterized by a ($CD8^+$) **T cell–mediated response** to cells along the junction of the dermis and epidermis. Although the etiology is unknown, the risk may be increased in patients with hepatitis C and those taking certain medications (eg, ACE inhibitors, thiazide diuretics). LP typically follows a chronic course with gradual, spontaneous remission within 2 years.

(Choice A) Actinic keratosis presents with small, hyperkeratotic plaques in sun-exposed areas (eg, forehead, cheeks). It is most common in patients age >60, and itching is atypical.

(Choice B) Atopic dermatitis typically occurs in large patches at the flexural surfaces of the extremities, especially the elbows; it usually presents in childhood, and most patients have a history of other atopic disorders (eg, allergic rhinitis, asthma).

(Choice C) Irritant contact dermatitis is due to repeated exposure to irritants (eg, detergents, solvents, oxidizing agents). It presents as hyperkeratotic patches with fissuring and scaling, most commonly on the hands.

(Choice E) Psoriasis is an immune-mediated inflammatory disease that usually presents with thick, erythematous plaques with silvery scales on the extensor surfaces of the knees and elbows, scalp, or neck.

Educational objective:
Lichen planus (LP) is an immune-mediated condition that presents with pruritic, pink papules and plaques, often with lacy, scaly, white markings (Wickham striae). The lesions typically occur on the flexural surfaces of the wrists and ankles but can also involve the nails, oral mucous membranes, and genitalia.

References

- Update on lichen planus and its clinical variants.

Pathology	Dermatology	Lichen planus
Subject	System	Topic

often have lacy, scaly, **white markings** (Wickham striae) and can form at sites of minor trauma (Köbner phenomenon). The skin lesions typically occur symmetrically on the flexural surfaces of the wrists and ankles but can also involve the nails, oral mucous membranes, and genitalia.

The pathologic process in LP is characterized by a ($CD8^+$) **T cell–mediated response** to cells along the junction of the dermis and epidermis. Although the etiology is unknown, the risk may be increased in patients with hepatitis C and those taking certain medications (eg, ACE inhibitors, thiazide diuretics). LP typically follows a chronic course with gradual, spontaneous remission within 2 years.

(Choice A) Actinic keratosis presents with small, hyperkeratotic plaques in sun-exposed areas (eg, forehead, cheeks). It is most common in patients age >60, and itching is atypical.

(Choice B) Atopic dermatitis typically occurs in large patches at the flexural surfaces of the extremities, especially the elbows; it usually presents in childhood, and most patients have a history of other atopic disorders (eg, allergic rhinitis, asthma).

(Choice C) Irritant contact dermatitis is due to repeated exposure to irritants (eg, detergents, solvents, oxidizing agents). It presents as hyperkeratotic patches with fissuring and scaling, most commonly on the hands.

(Choice E) Psoriasis is an immune-mediated inflammatory disease that usually presents with thick, erythematous plaques with silvery scales on the extensor surfaces of the knees and elbows, scalp, or neck.

Educational objective:
Lichen planus (LP) is an immune-mediated condition that presents with pruritic, pink papules and plaques, often with lacy, scaly, white markings (Wickham striae). The lesions typically occur on the flexural surfaces of the wrists and ankles but can also involve the nails, oral mucous membranes, and genitalia.

References

- Update on lichen planus and its clinical variants.

Pathology	Dermatology	Lichen planus
Subject	System	Topic

Copyright © UWorld. All rights reserved.

often have lacy, scaly, **white markings** (Wickham striae) and can form at sites of minor trauma (Köbner phenomenon). The skin lesions typically

Exhibit Display

Lichen planus

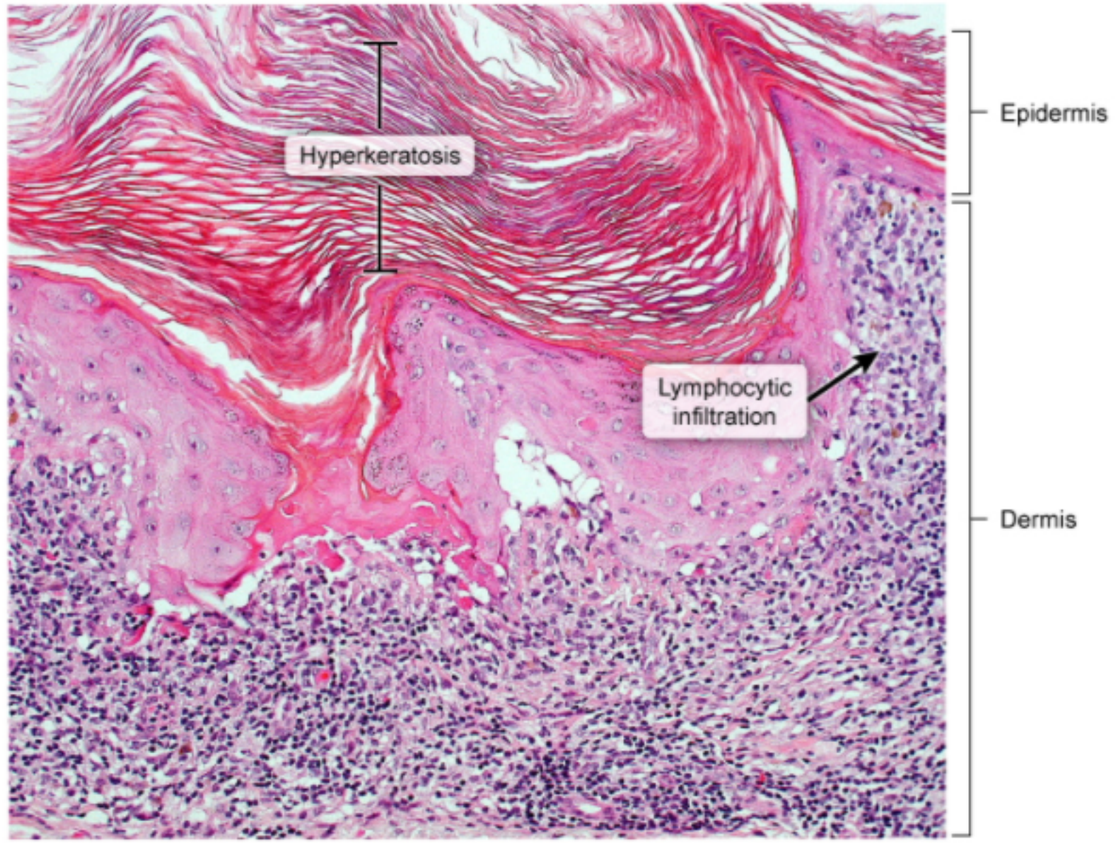

©UWorld

Zoom In | Zoom Out | Reset | Add To Flash Card

Copyright © UWorld. All rights reserved.

1 2 3 4 5 6 7 8 9 10 11 12 13 14 15 16 17 18 19 20 21 22 23 24 25 26 27 28 29 30

often have lacy, scaly, **white markings** (Wickham striae) and can form at sites of minor trauma (Köbner phenomenon). The skin lesions typically

Exhibit Display

Zoom In | Zoom Out | Reset | Add To Flash Card

Copyright © UWorld. All rights reserved.

1 2 3 4 5 6 7 8 9 10 11 12 13 14 15 16 17 18 19 20 21 22 23 24 25 26 27 28 29 30

often have lacy, scaly, **white markings** (Wickham striae) and can form at sites of minor trauma (Köbner phenomenon). The skin lesions typically

Exhibit Display

Zoom In | Zoom Out | Reset | Add To Flash Card

Copyright © UWorld. All rights reserved.

often have lacy, scaly, **white markings** (Wickham striae) and can form at sites of minor trauma (Köbner phenomenon). The skin lesions typically

Exhibit Display

Zoom In | Zoom Out | Reset | Add To Flash Card

Copyright © UWorld. All rights reserved.

1 2 3 4 5 6 7 8 9 10 11 12 13 14 15 16 17 18 19 20 21 22 23 24 25 26 27 28 29 30

often have lacy, scaly, **white markings** (Wickham striae) and can form at sites of minor trauma (Köbner phenomenon). The skin lesions typically

Exhibit Display

Zoom In | Zoom Out | Reset | Add To Flash Card

Copyright © UWorld. All rights reserved.

A 17-year-old boy comes to the office for evaluation of a rash. For the past 2 years, the patient has had recurrent skin bumps that are frequently red and painful. He has no other medical conditions and takes no medications. Vital signs are within normal limits. Skin examination findings are shown below.

Settings

1
2
3
4
5
6
7
8
9
10
11
12
13
14
15
16
17
18
19
20
21
22
23
24
25
26
27
28
29
30

Item 16 of 40
Question Id: 15374

Mark | Previous | Next | Full Screen | Tutorial | Lab Values | Notes | Calculator | Reverse Color | Text Zoom | Settings

Block Time Remaining: 00:01:19
TUTOR

7 | Feedback | Suspend | End Block

This patient's skin condition primarily affects which of the following structures?

- A. Dermal papillae
- B. Eccrine sweat glands
- C. Epidermal-dermal junction
- D. Melanocytes
- E. Pilosebaceous follicles
- F. Subcutaneous adipose tissue

Submit

1 2 3 4 5 6 7 8 9 10 11 12 13 14 15 16 17 18 19 20 21 22 23 24 25 26 27 28 29 30

This patient's skin condition primarily affects which of the following structures?

- A. Dermal papillae (5%)
- B. Eccrine sweat glands (7%)
- C. Epidermal-dermal junction (3%)
- D. Melanocytes (0%)
- ✓ E. Pilosebaceous follicles (82%)
- F. Subcutaneous adipose tissue (1%)

Omitted
Correct answer

82%
Answered correctly

07 secs
Time Spent

03/22/2020
Last Updated

Explanation

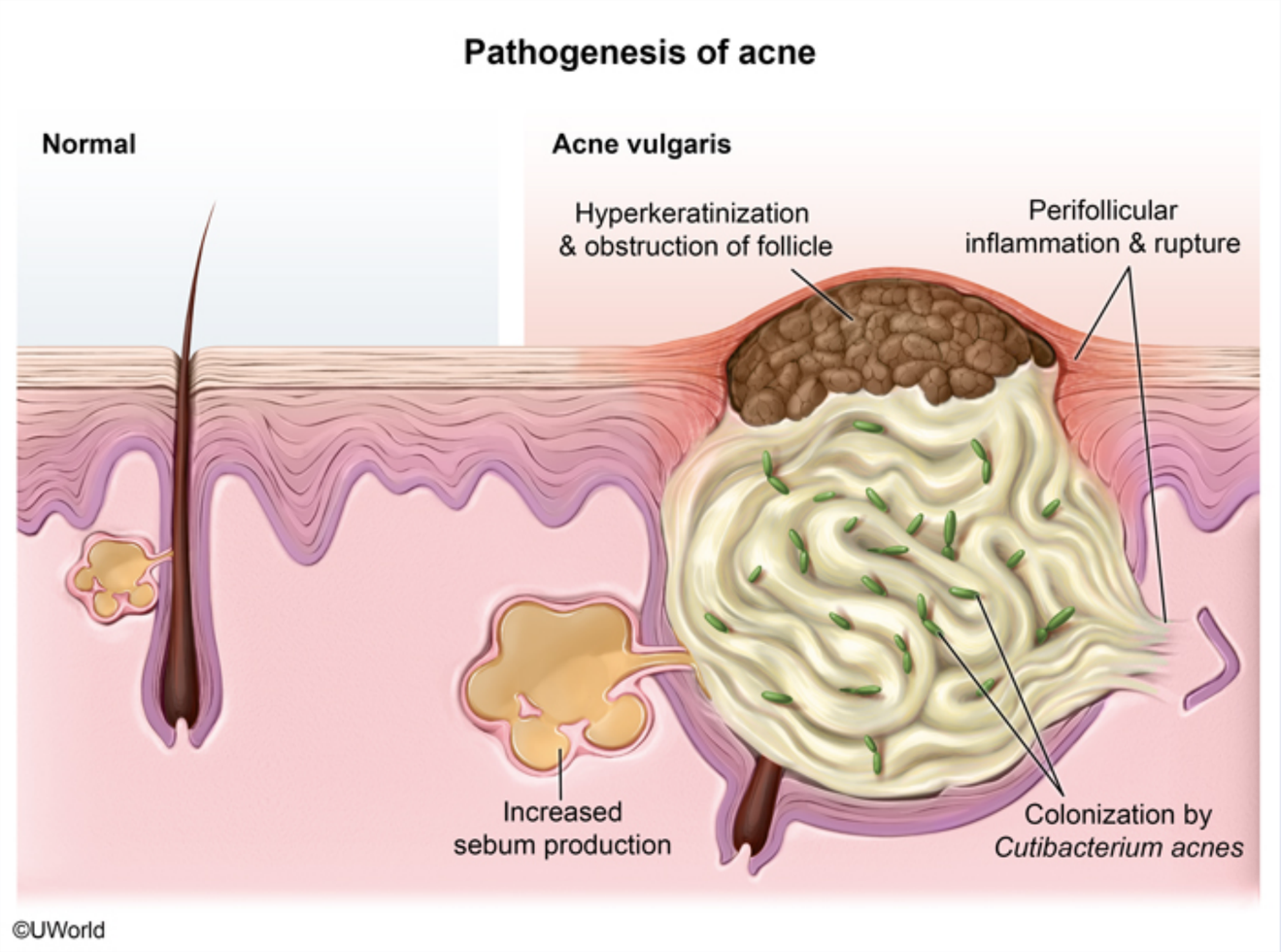

This patient has typical features of **acne vulgaris**. Acne usually appears in adolescence and can present with a variety of lesions, including comedones, papules, pustules, or inflammatory nodules, often with lesions in different stages concurrently. Nodular (sometimes called

This patient has typical features of **acne vulgaris**. Acne usually appears in adolescence and can present with a variety of lesions, including comedones, papules, pustules, or inflammatory nodules, often with lesions in different stages concurrently. Nodular (sometimes called nodulocystic) acne, as in this patient, is often painful, difficult to treat, and can lead to the formation of sinus tracts and residual scarring.

Acne vulgaris is characterized by **inflammation of pilosebaceous follicles**. Contributing factors include **hyperkeratinization** and obstruction of follicles; sebaceous gland enlargement with **increased sebum secretion**; colonization of the gland by *Propionibacterium* (***Cutibacterium***) ***acnes***, which metabolizes lipids in sebum and produces proinflammatory factors; and follicular and perifollicular inflammation with follicular rupture.

(Choice A) Dermatitis herpetiformis most commonly occurs in patients with celiac disease and is characterized by microabscesses containing fibrin and neutrophils at the dermal papillae tips. Clinical manifestations include pruritic papules, vesicles, and bullae that appear symmetrically on the extensor surfaces (eg, elbows, knees), upper back, and buttocks.

(Choice B) Eccrine sweat glands produce watery sweat in response to exertion, high ambient temperature, and emotional stress. The secretions from eccrine glands have little lipid content and do not support heavy colonization by *P acnes*; therefore, these glands do not have a prominent role in the pathogenesis of acne.

(Choice C) Bullous pemphigoid is characterized by an autoimmune process that causes the epidermis to separate from the dermis, forming subepidermal blisters. It presents with tense, fluid-filled bullae on the inner thighs, forearms, axillae, groin, and abdomen.

(Choice D) Melanocyte disorders typically present with hyperpigmentation (eg, melasma) or hypopigmentation (eg, vitiligo).

(Choice F) Erythema nodosum—characterized by painful, subcutaneous nodules, typically in the lower legs—is a form of panniculitis (inflammation of the subcutaneous adipose tissue) caused by a delayed hypersensitivity reaction to antigens associated with various conditions (eg, herpes simplex).

Educational objective:
Acne vulgaris is an inflammatory disorder of pilosebaceous follicles. Contributing factors include hyperkeratinization and obstruction of follicles; sebaceous gland enlargement with increased secretion of sebum; colonization and proliferation in the gland by *Propionibacterium* (*Cutibacterium*) *acnes*; and follicular and perifollicular inflammation.

References

Settings

1
2
3
4
5
6
7
8
9
10
11
12
13
14
15
16
17
18
19
20
21
22
23
24
25
26
27
28
29
30

Item 16 of 40
Question Id: 15374

Mark | Previous | Next | Full Screen | Tutorial | Lab Values | Notes | Calculator | Reverse Color | Text Zoom | Settings

This patient has typi
comedones, papule
nodulocystic) acne,

Acne vulgaris is cha
follicles; sebaceous
which metabolizes li

(Choice A) Dermat
fibrin and neutrophil
the extensor surface

(Choice B) Eccrine
from eccrine glands
role in the pathogen

(Choice C) Bullous
subepidermal blister

(Choice D) Melano

(Choice F) Erythen
(inflammation of the
(eg, herpes simplex

Educational object
Acne vulgaris is an i
sebaceous gland er
acnes; and follicular

References

Exhibit Display

Zoom In | Zoom Out | Reset | Add To New Card | Existing Card

Block Time Remaining: 00:01:22
TUTOR

7 | Feedback | Suspend | End Block

Settings

1 2 3 4 5 6 7 8 9 10 11 12 13 14 15 16 17 18 19 20 21 22 23 24 25 26 27 28 29 30

Item 16 of 40
Question Id: 15374

Mark | Previous | Next | Full Screen | Tutorial | Lab Values | Notes | Calculator | Reverse Color | Text Zoom | Settings

comedones, papules, pustules, or inflammatory nodules, often with lesions in different stages concurrently. Nodular (sometimes called

Exhibit Display

Zoom In | Zoom Out | Reset | Add To New Card | Existing Card

Block Time Remaining: 00:01:22
TUTOR

7 | Feedback | Suspend | End Block

A 53-year-old woman comes to the clinic due to a skin rash. For the last 3 weeks, she has had a pruritic rash of worsening severity involving the posterior thighs. The patient recently began an exercise program to lose weight and has been applying a topical analgesic cream to her thighs and buttocks after her workouts. Her past medical history is unremarkable, and she does not use tobacco, alcohol, or illicit drugs. On physical examination, there is an erythematous rash with blisters, ulcers, and weeping drainage involving the posterior thighs bilaterally, as shown in the image below.

Settings

1 2 3 4 5 6 7 8 9 10 11 12 13 14 15 16 17 18 19 20 21 22 23 24 25 26 27 28 29 30

Item 17 of 40
Question Id: 1115

Mark | Previous | Next | Full Screen | Tutorial | Lab Values | Notes | Calculator | Reverse Color | Text Zoom | Settings

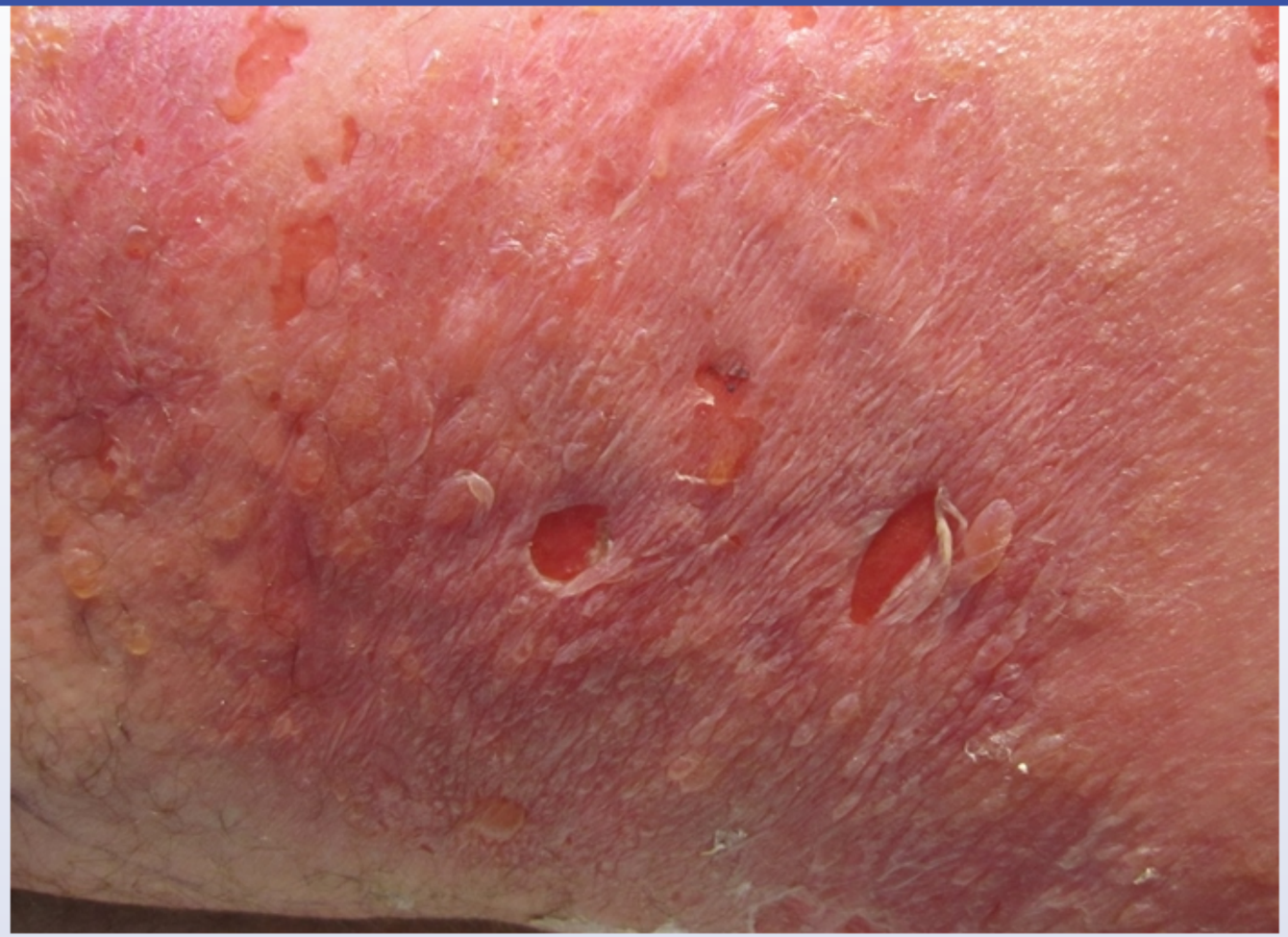

Which of the following is the most likely finding on skin biopsy?

A. Acanthosis

B. Dyskeratosis

Block Time Remaining: 00:01:24
TUTOR

5 | Feedback | Suspend | End Block

Settings

1 2 3 4 5 6 7 8 9 10 11 12 13 14 15 16 17 18 19 20 21 22 23 24 25 26 27 28 29 30

Item 17 of 40
Question Id: 1115

Mark | Previous | Next | Full Screen | Tutorial | Lab Values | Notes | Calculator | Reverse Color | Text Zoom | Settings

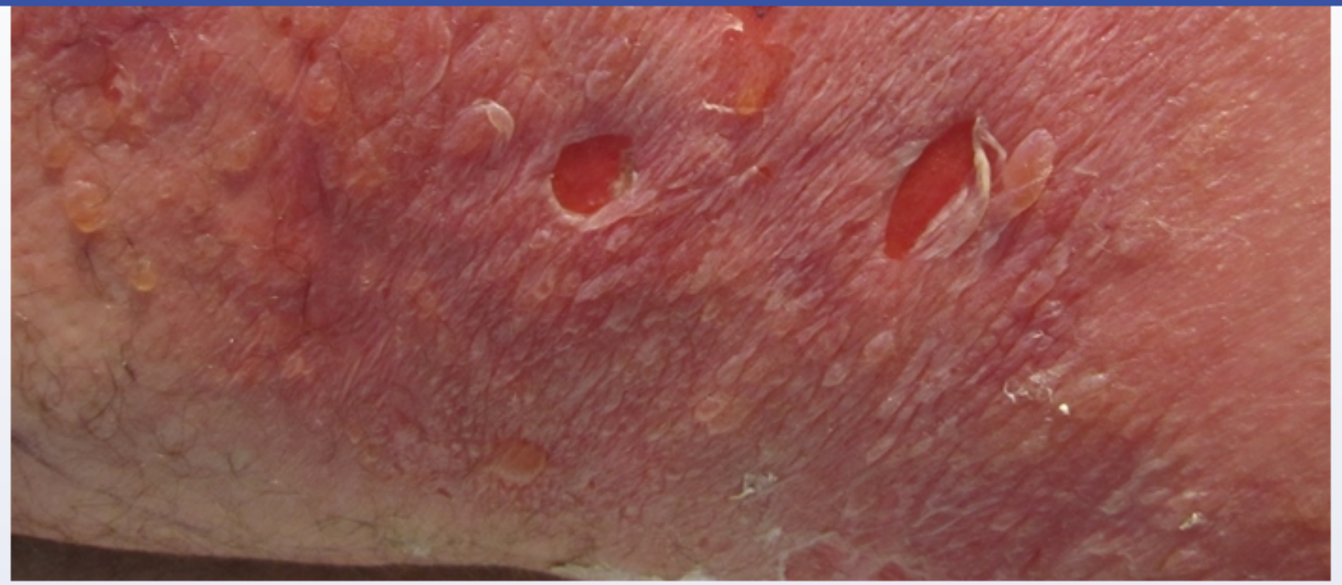

Which of the following is the most likely finding on skin biopsy?

- A. Acanthosis
- B. Dyskeratosis
- C. Hypergranulosis
- D. Hyperkeratosis
- E. Spongiosis

Submit

Block Time Remaining: 00:01:26
TUTOR

5 | Feedback | Suspend | End Block

1 2 3 4 5 6 7 8 9 10 11 12 13 14 15 16 17 18 19 20 21 22 23 24 25 26 27 28 29 30

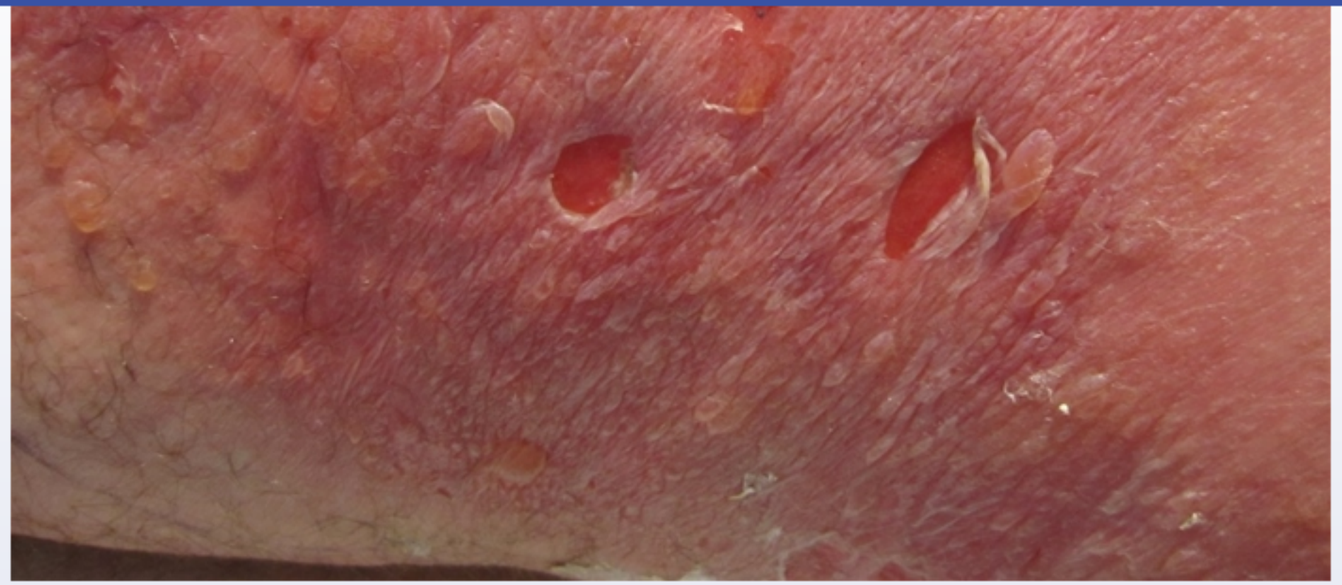

Which of the following is the most likely finding on skin biopsy?

A. Acanthosis (16%)

B. Dyskeratosis (22%)

C. Hypergranulosis (8%)

D. Hyperkeratosis (7%)

✓ E. Spongiosis (44%)

Omitted
Correct answer

44%
Answered correctly

06 secs
Time Spent

06/20/2020
Last Updated

Explanation

Eczematous dermatitis (eczema) is a group of conditions characterized by erythematous, papulovesicular, weeping lesions. This patient has **acute allergic contact dermatitis** (ACD), a form of eczema caused by a **type IV (delayed) hypersensitivity** reaction to an antigen on the skin surface. In ACD, antigens are taken up by antigen-presenting Langerhans cells and presented to CD4+ T cells in regional lymph nodes. The T cells are activated and migrate to the skin, where they incite an inflammatory response within 24 hours of antigen re-exposure.

Acute eczematous dermatitis is characterized histologically by **spongiosis**, an accumulation of **edema fluid** in the intercellular spaces of the epidermis. The intercellular bridges become more distinctive in an edematous background, and the epidermis is often described as "spongy." Eventually, the edema can become so marked as to form intraepidermal vesicles. A perivascular infiltrate of lymphocytes and eosinophils may also be seen; this may involve only the superficial dermis (if due to exposure to a surface antigen) or extend to include the deeper vessels (if due to a systemic antigen exposure [eg, drugs]).

With persistent antigen exposure, lesions may become less edematous and weepy. Thickening of the stratum spinosum (acanthosis) and stratum corneum (hyperkeratosis) produces raised, scaly plaques**(Choices A and D)**.

(Choice B) Dyskeratosis is abnormal, premature keratinization of individual keratinocytes below the stratum granulosum. Dyskeratosis can be due to genetic mutations (dyskeratosis congenita) or may be found in diseases such as squamous cell carcinoma.

(Choice C) Hypergranulosis is increased thickness of the stratum granulosum of the epidermis and is seen in conditions such as lichen planus.

Educational objective:
Acute allergic contact dermatitis is caused by a type IV (delayed) hypersensitivity reaction to an antigen on the skin surface. Gross findings include erythematous, papulovesicular, weeping lesions. Histology is characterized by spongiosis, an accumulation of edema fluid in the intercellular spaces of the epidermis. With chronic exposure, lesions become less edematous, with thickening of the stratum spinosum and stratum corneum.

Pathology	Dermatology	Contact dermatitis
Subject	System	Topic

Copyright © UWorld. All rights reserved.

Explanation

Exhibit Display

Epidermis of the skin

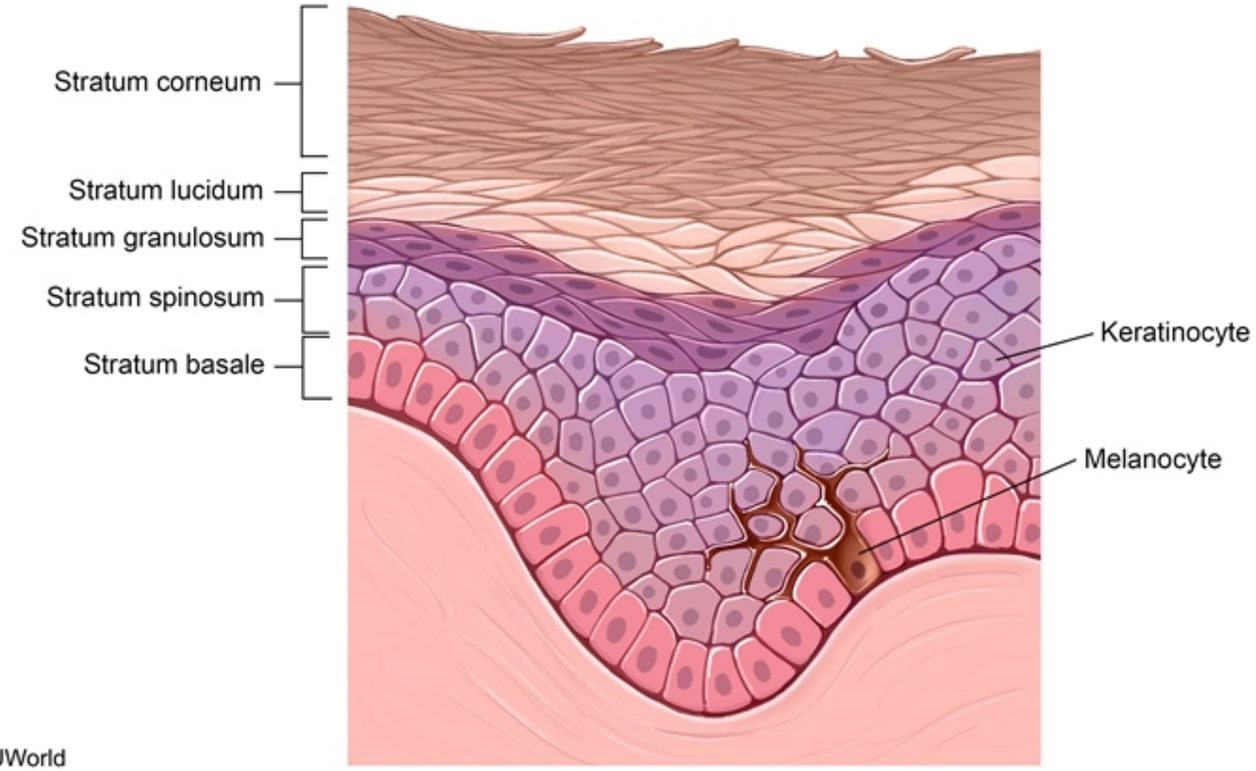

©UWorld

Zoom In | Zoom Out | Reset | Add To New Card | Existing Card

Copyright © UWorld. All rights reserved.

Settings

1
2
3
4
5
6
7
8
9
10
11
12
13
14
15
16
17
18
19
20
21
22
23
24
25
26
27
28
29
30

Item 17 of 40
Question Id: 1115

Mark | Previous | Next | Full Screen | Tutorial | Lab Values | Notes | Calculator | Reverse Color | Text Zoom | Settings

Explanation

Exhibit Display

Zoom In | Zoom Out | Reset | Add To New Card | Existing Card

Copyright © UWorld. All rights reserved.

Block Time Remaining: 00:01:28
TUTOR

5 | Feedback | Suspend | End Block

Settings

1
2
3
4
5
6
7
8
9
10
11
12
13
14
15
16
17
18
19
20
21
22
23
24
25
26
27
28
29
30

Item 17 of 40
Question Id: 1115

Mark | Previous | Next | Full Screen | Tutorial | Lab Values | Notes | Calculator | Reverse Color | Text Zoom | Settings

Explanation

Exhibit Display

Zoom In | Zoom Out | Reset | Add To New Card | Existing Card

Copyright © UWorld. All rights reserved.

Block Time Remaining: 00:01:28
TUTOR

5 | Feedback | Suspend | End Block

Settings

1
2
3
4
5
6
7
8
9
10
11
12
13
14
15
16
17
18
19
20
21
22
23
24
25
26
27
28
29
30

Item 17 of 40
Question Id: 1115

Mark | Previous | Next | Full Screen | Tutorial | Lab Values | Notes | Calculator | Reverse Color | Text Zoom | Settings

Explanation

Exhibit Display

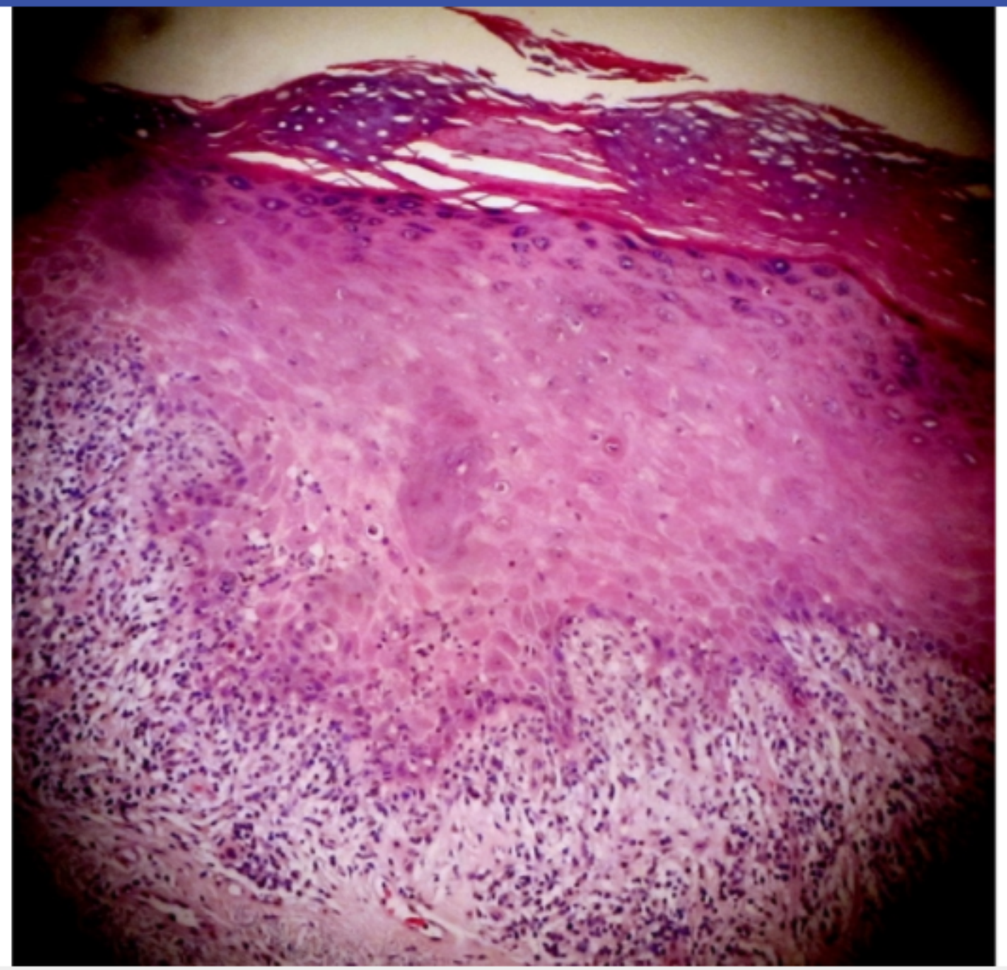

Zoom In | Zoom Out | Reset | Add To New Card | Existing Card

Copyright © UWorld. All rights reserved.

Block Time Remaining: 00:01:28
TUTOR

5 | Feedback | Suspend | End Block

A 38-year-old woman comes to the urgent care clinic with a 2-day history of sore throat. It is associated with fever and cervical lymphadenopathy, but not rhinorrhea, sneezing, or coughing. On examination, erythema and edema involving the posterior pharynx and a purulent tonsillar exudate are present. Rapid bedside streptococcal antigen testing is positive, and the patient is started on oral penicillin V. She returns the following day with a pruritic skin rash that came on suddenly after starting the antibiotic. The skin lesions observed on physical examination are shown in the image below.

Settings

4
5
6
7
8
9
10
11
12
13
14
15
16
17
18
19
20
21
22
23
24
25
26
27
28
29
30
31
32
33

Item 18 of 40
Question Id: 1114

Mark | Previous | Next | Full Screen | Tutorial | Lab Values | Notes | Calculator | Reverse Color | Text Zoom | Settings

What is the most likely finding on biopsy of these lesions?

A. Acantholysis

B. Acanthosis

C. Dermal edema

D. Dyskeratosis

Block Time Remaining: 00:01:34
TUTOR

3 | Feedback | Suspend | End Block

Settings

4
5
6
7
8
9
10
11
12
13
14
15
16
17
18
19
20
21
22
23
24
25
26
27
28
29
30
31
32
33

Item 18 of 40
Question Id: 1114

Mark | Previous | Next | Full Screen | Tutorial | Lab Values | Notes | Calculator | Reverse Color | Text Zoom | Settings

What is the most likely finding on biopsy of these lesions?

- A. Acantholysis
- B. Acanthosis
- C. Dermal edema
- D. Dyskeratosis
- E. Epidermal spongiosis

Submit

Block Time Remaining: 00:01:35
TUTOR

3 | Feedback | Suspend | End Block

4
5
6
7
8
9
10
11
12
13
14
15
16
17
18
19
20
21
22
23
24
25
26
27
28
29
30
31
32
33

What is the most likely finding on biopsy of these lesions?

A. Acantholysis (7%)

B. Acanthosis (4%)

✓ C. Dermal edema (60%)

D. Dyskeratosis (1%)

E. Epidermal spongiosis (25%)

Omitted
Correct answer

60%
Answered correctly

09 secs
Time Spent

01/22/2020
Last Updated

4
5
6
7
8
9
10
11
12
13
14
15
16
17
18
19
20
21
22
23
24
25
26
27
28
29
30
31
32
33

Explanation

Urticaria ("hives") is a common, transient **hypersensitivity** disorder characterized by intensely pruritic, raised, erythematous plaques (**wheals**) that arise suddenly and resolve over several hours. They are most often caused by **IgE-mediated degranulation** of mast cells. They can also be due to non-IgE-mediated degranulation (eg, opiates, radiocontrast agents, physical urticaria) or mast cell-independent mechanisms (eg, aspirin, hereditary angioneurotic edema).

Urticaria is due to increased permeability of the microvasculature, leading to **edema** of the **superficial dermis**. Involvement of the deep dermis and subcutaneous tissue is termed angioedema. Biopsy is rarely required for diagnosis. Findings on histopathology would typically include a mixed inflammatory infiltrate (mononuclear cells, neutrophils, and eosinophils) surrounding superficial dermal venules. Lymphatic channels may be engorged with transudative fluid. The overlying epidermis typically appears normal.

(Choice A) Acantholysis is the loss of cohesion between keratinocytes in the epidermis. It is a characteristic finding in the pemphigus family of disorders.

(Choice B) Acanthosis is a diffuse increase in thickness of the stratum spinosum (prickle cell layer) between the granular cell layer and the basal layer of the epidermis. Common conditions displaying acanthosis include psoriasis, seborrheic dermatitis, and acanthosis nigricans.

(Choice D) Dyskeratosis describes the abnormal, premature keratinization of individual keratinocytes. Dyskeratotic cells are strongly eosinophilic and may have a small, basophilic nuclear remnant. Dyskeratosis can be found in diseases such as squamous cell carcinoma.

(Choice E) Spongiosis is intercellular epidermal edema that histologically appears as an increase in the width of spaces between cells. Spongiosis is often associated with spongiotic dermatitis, which encompasses a number of conditions (eg, eczematous dermatitis).

Educational objective:
Urticaria is a transient hypersensitivity disorder characterized by pruritic erythematous plaques that arise suddenly and resolve over hours. They are most often caused by IgE-mediated degranulation of mast cells, leading to increased permeability of the microvasculature with edema of the superficial dermis.

References

- Pathogenic intracellular and autoimmune mechanisms in urticaria and angioedema.

4 5 6 7 8 9 10 11 12 13 14 15 16 17 18 19 20 21 22 23 24 25 26 27 28 29 30 31 32 33

A 64-year-old man comes to the office with a 4-day history of severe left-sided chest discomfort. The pain is constant and has a burning quality. Over the last day, the patient has developed a rash in the area of discomfort. He has not had similar symptoms before. Past medical history is unremarkable. The patient is afebrile and vital signs are normal. Physical examination shows a vesicular rash at the 5th left intercostal space. Which of the following pathologic findings is most likely to be found in the affected area?

- A. Acantholysis and intercellular IgG deposits
- B. Eosinophilic cytoplasmic inclusions
- C. Koilocytosis of the superficial epidermal layers
- D. Microabscesses at the tips of dermal papillae
- E. Multinucleated cells with intranuclear inclusions

Submit

4
5
6
7
8
9
10
11
12
13
14
15
16
17
18
19
20
21
22
23
24
25
26
27
28
29
30
31
32
33

A 64-year-old man comes to the office with a 4-day history of severe left-sided chest discomfort. The pain is constant and has a burning quality. Over the last day, the patient has developed a rash in the area of discomfort. He has not had similar symptoms before. Past medical history is unremarkable. The patient is afebrile and vital signs are normal. Physical examination shows a vesicular rash at the 5th left intercostal space. Which of the following pathologic findings is most likely to be found in the affected area?

- A. Acantholysis and intercellular IgG deposits (4%)
- B. Eosinophilic cytoplasmic inclusions (11%)
- C. Koilocytosis of the superficial epidermal layers (6%)
- D. Microabscesses at the tips of dermal papillae (6%)
- ✓ E. Multinucleated cells with intranuclear inclusions (71%)

Omitted
Correct answer
E

71%
Answered correctly

02 secs
Time Spent

01/30/2020
Last Updated

Explanation

Varicella zoster virus (VZV) is an enveloped, double-stranded DNA virus transmitted via respiratory droplets or direct contact. Initial infection typically occurs in childhood and causes varicella (chicken pox), which is characterized by fever and a self-limited, diffuse vesicular rash. VZV then travels via sensory fibers to the **dorsal root ganglia** (or trigeminal ganglia), where it remains dormant for years. Weakening of cellular immunity leads to reactivation of the virus, which manifests as herpes zoster (**shingles**). Shingles is characterized by unilateral burning pain and a papular or vesicular rash in a dermatomal distribution. The lesions coalesce, rupture, crust over, and heal within a few weeks although the discomfort may linger for several weeks.

4
5
6
7
8
9
10
11
12
13
14
15
16
17
18
19
20
21
22
23
24
25
26
27
28
29
30
31
32
33

Varicella zoster virus (VZV) is an enveloped, double-stranded DNA virus transmitted via respiratory droplets or direct contact. Initial infection typically occurs in childhood and causes varicella (chicken pox), which is characterized by fever and a self-limited, diffuse vesicular rash. VZV then travels via sensory fibers to the **dorsal root ganglia** (or trigeminal ganglia), where it remains dormant for years. Weakening of cellular immunity leads to reactivation of the virus, which manifests as herpes zoster (**shingles**). Shingles is characterized by unilateral burning pain and a papular or vesicular rash in a dermatomal distribution. The lesions coalesce, rupture, crust over, and heal within a few weeks although the discomfort may linger for several weeks.

Light microscopy of a sample from a vesicle base reveals **intranuclear inclusions** in keratinocytes and **multinucleated giant cells** (positive Tzanck smear). Skin biopsy would show acantholysis (loss of intercellular connections) of keratinocytes and intraepidermal vesicles.

(Choice A) Acantholysis forming suprabasal blisters is characteristic of pemphigus vulgaris (PV). Immunofluorescence reveals deposition of IgG-containing deposits in a reticular pattern around keratinocytes. The immune target in PV is the desmosome protein desmoglein 3.

(Choice B) Infection by molluscum contagiosum, a poxvirus, causes eosinophilic cytoplasmic inclusions (molluscum bodies) in infected cells and dome-shaped, umbilicated papules on examination.

(Choice C) Human papillomavirus (HPV) infection of the skin presents with warts (verruca vulgaris) or squamous cell carcinoma of the penis or vulva, depending on the serotype. Light microscopy reveals cytoplasmic vacuoles in keratinocytes (koilocytosis) and hyperplasia of the epidermis.

(Choice D) Dermatitis herpetiformis presents with pruritic, grouped vesicles on the extensor surfaces. Light microscopy reveals accumulations of neutrophils on the tips of dermal papillae (microabscesses).

Educational objective:
Herpes zoster (shingles) develops due to reactivation of varicella zoster virus in the dorsal root ganglia (sensory neurons). It presents with a painful vesicular rash in a dermatomal distribution. Intranuclear inclusions in keratinocytes and multinucleated giant cells are seen on light microscopy.

Pathology	Dermatology	Herpes zoster
Subject	System	Topic

Settings

Item 19 of 40
Question Id: 1042

Mark | Previous | Next | Full Screen | Tutorial | Lab Values | Notes | Calculator | Reverse Color | Text Zoom | Settings

typically occurs in childhood and causes varicella (chicken pox), which is characterized by fever and a self-limited, diffuse vesicular rash. VZV

Exhibit Display

Zoom In | Zoom Out | Reset | Add To New Card | Existing Card

Block Time Remaining: 00:01:39
TUTOR

8 | Feedback | Suspend | End Block

4
5
6
7
8
9
10
11
12
13
14
15
16
17
18
19
20
21
22
23
24
25
26
27
28
29
30
31
32
33

typically occurs in childhood and causes varicella (chicken pox), which is characterized by fever and a self-limited, diffuse vesicular rash. VZV

Exhibit Display

Zoom In | Zoom Out | Reset | Add To New Card | Existing Card

4
5
6
7
8
9
10
11
12
13
14
15
16
17
18
19
20
21
22
23
24
25
26
27
28
29
30
31
32
33

typically occurs in childhood and causes varicella (chicken pox), which is characterized by fever and a self-limited, diffuse vesicular rash. VZV

Exhibit Display

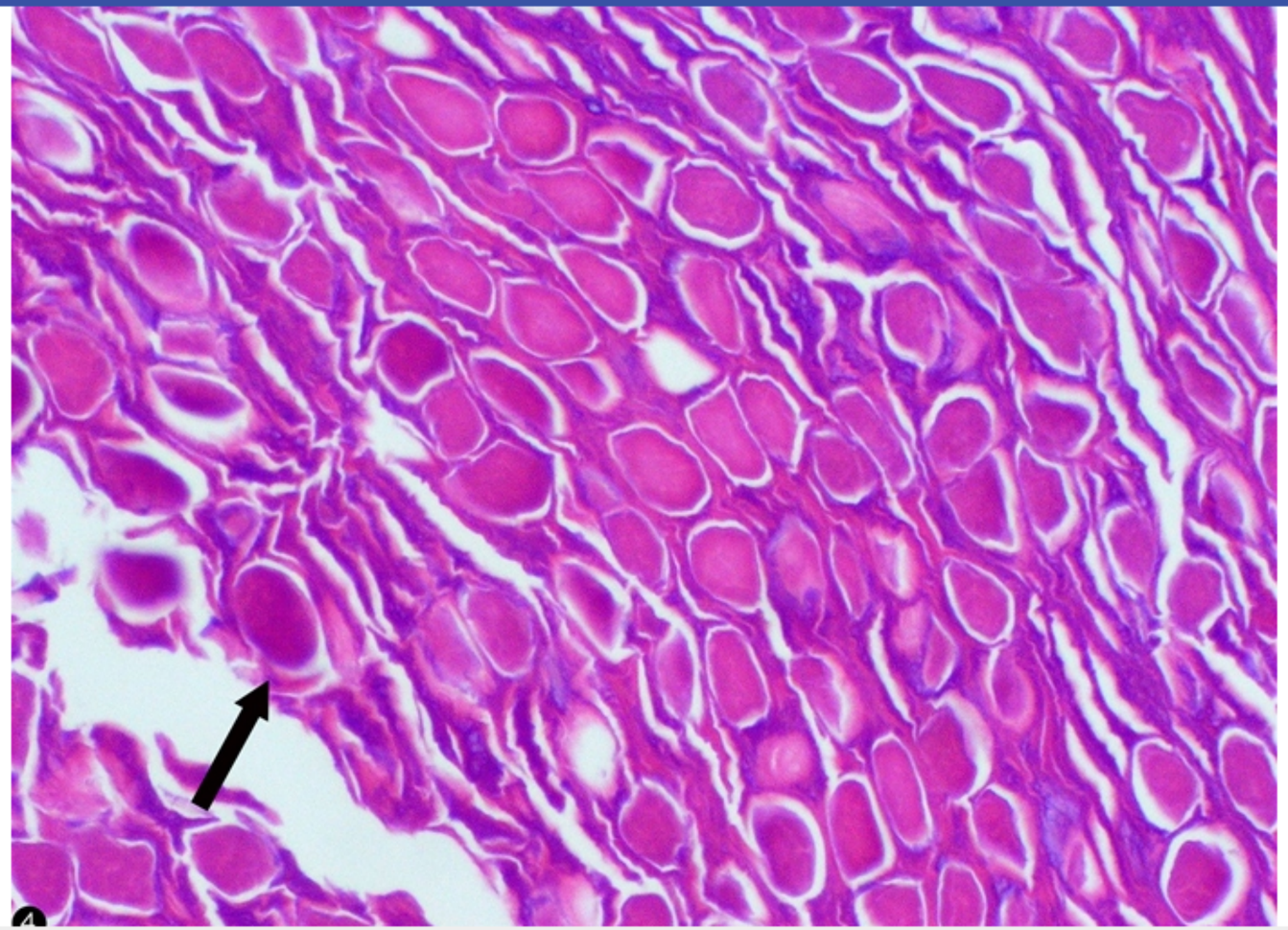

Zoom In | Zoom Out | Reset | Add To New Card | Existing Card

4
5
6
7
8
9
10
11
12
13
14
15
16
17
18
19
20
21
22
23
24
25
26
27
28
29
30
31
32
33

typically occurs in childhood and causes varicella (chicken pox), which is characterized by fever and a self-limited, diffuse vesicular rash. VZV

Exhibit Display

Zoom In | Zoom Out | Reset | Add To New Card | Existing Card

4
5
6
7
8
9
10
11
12
13
14
15
16
17
18
19
20
21
22
23
24
25
26
27
28
29
30
31
32
33

typically occurs in childhood and causes varicella (chicken pox), which is characterized by fever and a self-limited, diffuse vesicular rash. VZV

Exhibit Display

Zoom In | Zoom Out | Reset | Add To New Card | Existing Card

4
5
6
7
8
9
10
11
12
13
14
15
16
17
18
19
20
21
22
23
24
25
26
27
28
29
30
31
32
33

typically occurs in childhood and causes varicella (chicken pox), which is characterized by fever and a self-limited, diffuse vesicular rash. VZV

Exhibit Display

Zoom In | Zoom Out | Reset | Add To New Card | Existing Card

typically occurs in childhood and causes varicella (chicken pox), which is characterized by fever and a self-limited, diffuse vesicular rash. VZV

Exhibit Display

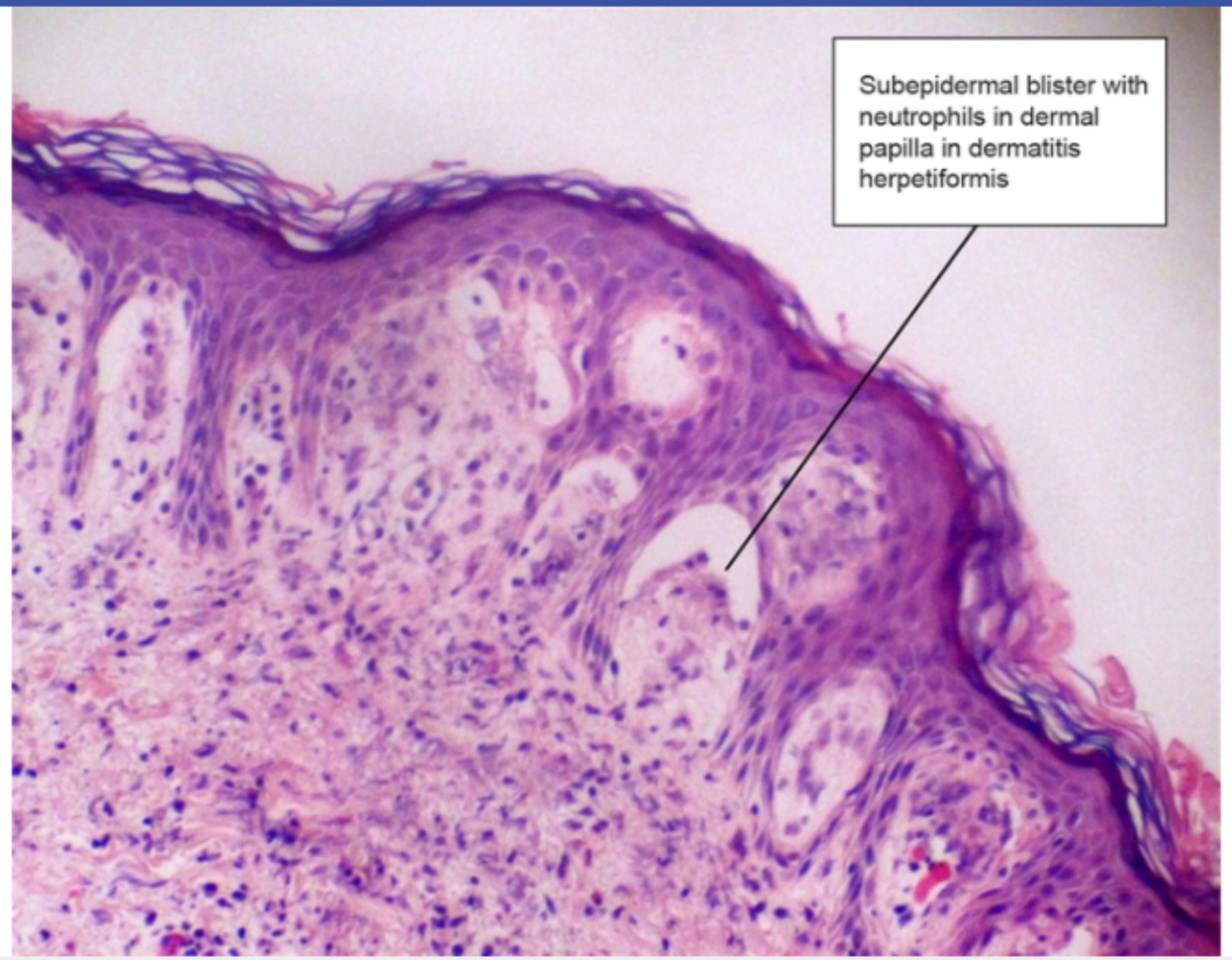

Zoom In | Zoom Out | Reset | Add To New Card | Existing Card

4 5 6 7 8 9 10 11 12 13 14 15 16 17 18 19 20 21 22 23 24 25 26 27 28 29 30 31 32 33

A 24-year-old woman comes to the office due to worsening acne. Over the past 3 months, the patient has had frequent breakouts on the shoulders and upper back. She had acne on her face during puberty, which cleared spontaneously after several years, but has never before had symptoms on her trunk. The patient has no other medical conditions, and her only medication is a combination oral contraceptive. She has been training for a half-marathon for the past 4 months and has lost 6.8 kg (15 lb) during this period. She does not use tobacco, alcohol, or illicit drugs, and she relocated from California to Wisconsin for work a year ago. Vital signs are within normal limits. Physical examination shows acneiform eruptions on the shoulders and mid-back. Which of the following is most likely contributing to worsening of this patient's acne?

A. Exposure to colder temperatures

B. Exposure to contaminated water

C. Rapid loss of body weight

D. Use of hormonal contraceptive

E. Use of tight-fitting sports clothing

Submit

4
5
6
7
8
9
10
11
12
13
14
15
16
17
18
19
20
21
22
23
24
25
26
27
28
29
30
31
32
33

A 24-year-old woman comes to the office due to worsening acne. Over the past 3 months, the patient has had frequent breakouts on the shoulders and upper back. She had acne on her face during puberty, which cleared spontaneously after several years, but has never before had symptoms on her trunk. The patient has no other medical conditions, and her only medication is a combination oral contraceptive. She has been training for a half-marathon for the past 4 months and has lost 6.8 kg (15 lb) during this period. She does not use tobacco, alcohol, or illicit drugs, and she relocated from California to Wisconsin for work a year ago. Vital signs are within normal limits. Physical examination shows acneiform eruptions on the shoulders and mid-back. Which of the following is most likely contributing to worsening of this patient's acne?

A. Exposure to colder temperatures (2%)

B. Exposure to contaminated water (1%)

C. Rapid loss of body weight (16%)

D. Use of hormonal contraceptive (37%)

✓ E. Use of tight-fitting sports clothing (42%)

Omitted
Correct answer
E

42%
Answered correctly

02 secs
Time Spent

03/20/2020
Last Updated

Explanation

Acne vulgaris	
	• **Comedonal acne:** closed or open comedones on forehead, nose & chin

4
5
6
7
8
9
10
11
12
13
14
15
16
17
18
19
20
21
22
23
24
25
26
27
28
29
30
31
32
33

Acne vulgaris	
Clinical features	• **Comedonal acne:** closed or open comedones on forehead, nose & chin • **Inflammatory acne:** small, erythematous papules & pustules • **Nodular acne:** large, painful nodules; sinus tracts & scarring
Pathogenesis	• Hyperkeratinization & obstruction of pilosebaceous follicle • Sebaceous gland enlargement & increased sebum production • Metabolism of sebaceous lipids by *Cutibacterium acnes* & release of inflammatory fatty acids • Follicular inflammation & rupture
Risk factors	• Increased circulating androgens (eg, puberty, polycystic ovary syndrome) • Mechanical trauma/friction (eg, excessive scrubbing, tight clothing) • Comedogenic oil-based skin & hair products • Excessive heat • Obesity

Acne vulgaris is a disorder of the **pilosebaceous follicle**. Hyperkeratinization and obstruction of the follicle in combination with glandular enlargement and increased sebum production provides an optimal environment for *Cutibacterium* (*Propionibacterium*) *acnes*. This organism metabolizes sebaceous lipids, releasing inflammatory factors that lead to follicular and perifollicular inflammation. Acne is most common in areas with a high concentration of sebaceous follicles, including the face, back, chest, and upper arms.

Androgens stimulate production of sebum, and increased androgen levels (eg, puberty, polycystic ovary syndrome) increase the incidence of acne. Obstruction of the glands, such as by **oil-based hair products** (pomade acne), also promotes acne. In addition, **mechanical irritation** can promote acne by increasing glandular occlusion and disruption of follicles (acne mechanica). **Sports participation**, as in this patient, frequently triggers acne due to the use of tight-fitting clothing (eg, sports bras) and protective gear (eg, helmets).

4
5
6
7
8
9
10
11
12
13
14
15
16
17
18
19
20
21
22
23
24
25
26
27
28
29
30
31
32
33

Acne vulgaris is a disorder of the **pilosebaceous follicle**. Hyperkeratinization and obstruction of the follicle in combination with glandular enlargement and increased sebum production provides an optimal environment for *Cutibacterium* (*Propionibacterium*) *acnes*. This organism metabolizes sebaceous lipids, releasing inflammatory factors that lead to follicular and perifollicular inflammation. Acne is most common in areas with a high concentration of sebaceous follicles, including the face, back, chest, and upper arms.

Androgens stimulate production of sebum, and increased androgen levels (eg, puberty, polycystic ovary syndrome) increase the incidence of acne. Obstruction of the glands, such as by **oil-based hair products** (pomade acne), also promotes acne. In addition, **mechanical irritation** can promote acne by increasing glandular occlusion and disruption of follicles (acne mechanica). **Sports participation**, as in this patient, frequently triggers acne due to the use of tight-fitting clothing (eg, sports bras) and protective gear (eg, helmets).

(Choice A) High ambient temperatures can worsen acne, leading to formation of painful nodules on the trunk (tropical acne). Colder temperatures are not associated with acne.

(Choice B) Exposure to water contaminated with *Pseudomonas aeruginosa* can cause erythematous papules and pustules around hair follicles (hot-tub folliculitis). This condition begins acutely, resolves spontaneously within 1-2 weeks, and typically involves the skin under a bathing suit (eg, buttocks) or on the extremities.

(Choice C) Obesity is associated with an increased risk of acne, but weight loss generally does not worsen acne.

(Choice D) Typical oral contraceptives do not promote acne. Rather, many commonly used contraceptives can reduce acne due to decreased synthesis of androgens.

Educational objective:
Risk factors for acne include increased androgen levels; obstruction of pilosebaceous glands by oil-based hair products; and mechanical irritation of skin follicles. Sports participation frequently triggers acne due to the use of tight-fitting clothing and protective gear.

Pathology	Dermatology	Acne vulgaris
Subject	System	Topic

Copyright © UWorld. All rights reserved.

4
5
6
7
8
9
10
11
12
13
14
15
16
17
18
19
20
21
22
23
24
25
26
27
28
29
30
31
32
33

A 34-year-old man comes to the office due to a persistent skin rash. He has a 6-month history of a scaly rash involving the upper and lower extremities that is associated with mild pruritus. The patient has attempted treatment with topical antihistamines and emollients without relief. Medical history is notable for childhood asthma and orolabial herpes simplex virus infection. He does not use tobacco or alcohol and works as a sales associate for a home improvement store. On examination, the patient has skin lesions as shown in the image below.

Settings

4
5
6
7
8
9
10
11
12
13
14
15
16
17
18
19
20
21
22
23
24
25
26
27
28
29
30
31
32
33

Item 21 of 40
Question Id: 1116

Mark | Previous | Next | Full Screen | Tutorial | Lab Values | Notes | Calculator | Reverse Color | Text Zoom | Settings

This patient's disorder is most likely associated with which of the following extradermal complications?

A. Chronic glomerulonephritis

B. Deforming joint disease

C. Medullary thyroid cancer

D. Peripheral neuropathy

E. Pulmonary fibrosis

Block Time Remaining: 00:01:44
TUTOR

6 | Feedback | Suspend | End Block

4
5
6
7
8
9
10
11
12
13
14
15
16
17
18
19
20
21
22
23
24
25
26
27
28
29
30
31
32
33

This patient's disorder is most likely associated with which of the following extradermal complications?

A. Chronic glomerulonephritis

B. Deforming joint disease

C. Medullary thyroid cancer

D. Peripheral neuropathy

E. Pulmonary fibrosis

Submit

4
5
6
7
8
9
10
11
12
13
14
15
16
17
18
19
20
21
22
23
24
25
26
27
28
29
30
31
32
33

This patient's disorder is most likely associated with which of the following extradermal complications?

- A. Chronic glomerulonephritis (6%)
- ✓ B. Deforming joint disease (81%)
- C. Medullary thyroid cancer (1%)
- D. Peripheral neuropathy (4%)
- E. Pulmonary fibrosis (5%)

Omitted
Correct answer

81%
Answered correctly

06 secs
Time Spent

02/03/2020
Last Updated

4
5
6
7
8
9
10
11
12
13
14
15
16
17
18
19
20
21
22
23
24
25
26
27
28
29
30
31
32
33

This patient with well-demarcated, scaly, erythematous plaques involving extensor surfaces of the extremities has typical features of **psoriasis**. Patients with psoriasis frequently develop additional complications, including:

- Psoriatic arthritis
- Nail changes: yellow-brown discoloration, **pitting**, thickening, or crumbling
- Inflammatory disorders of the eye: conjunctivitis, blepharitis, or **uveitis**

Psoriatic arthritis is an inflammatory disorder affecting the synovium and often the insertion of tendons and ligaments (ie, enthesopathy). It typically manifest as asymmetric oligoarthritis or symmetric polyarthritis (resembling rheumatoid arthritis) that often affects the distal interphalangeal joints. In severe cases, patients can develop an aggressive and destructive arthritis mutilans. The risk is increased in patients who are human leukocyte antigen B27–positive.

(Choice A) Chronic glomerulonephritis frequently occurs in systemic lupus erythematosus. However, lupus is typically associated with an erythematous malar rash.

(Choice C) Medullary thyroid cancer is frequently linked to multiple endocrine neoplasia type 2.

(Choice D) Skin lesions, renal insufficiency, and peripheral neuropathy (eg, mononeuropathy multiplex) are frequent findings in polyarteritis nodosa, a vasculitis affecting medium-sized arteries.

(Choice E) Pulmonary fibrosis is a common extradermal manifestation of systemic sclerosis (scleroderma).

Educational objective:
Common complications of psoriasis include psoriatic arthritis, nail changes, and uveitis.

References

- Clinical features and diagnostic considerations in psoriatic arthritis.

Pathology	Dermatology	Psoriasis
Subject	System	Topic

Copyright © UWorld. All rights reserved.

4
5
6
7
8
9
10
11
12
13
14
15
16
17
18
19
20
21
22
23
24
25
26
27
28
29
30
31
32
33

This patient with well-demarcated, scaly, erythematous plaques involving extensor surfaces of the extremities has typical features of **psoriasis**.

Exhibit Display

Zoom In | Zoom Out | Reset | Add To New Card | Existing Card

Copyright © UWorld. All rights reserved.

4
5
6
7
8
9
10
11
12
13
14
15
16
17
18
19
20
21
22
23
24
25
26
27
28
29
30
31
32
33

This patient with well-demarcated, scaly, erythematous plaques involving extensor surfaces of the extremities has typical features of **psoriasis**.

Exhibit Display

Zoom In | Zoom Out | Reset | Add To New Card | Existing Card

Copyright © UWorld. All rights reserved.

Settings

Item 21 of 40
Question Id: 1116

Mark | Previous | Next | Full Screen | Tutorial | Lab Values | Notes | Calculator | Reverse Color | Text Zoom | Settings

This patient with well-demarcated, scaly, erythematous plaques involving extensor surfaces of the extremities has typical features of **psoriasis**.

Exhibit Display

Zoom In | Zoom Out | Reset | Add To New Card | Existing Card

Copyright © UWorld. All rights reserved.

Block Time Remaining: 00:01:47
TUTOR

6 | Feedback | Suspend | End Block

4
5
6
7
8
9
10
11
12
13
14
15
16
17
18
19
20
21
22
23
24
25
26
27
28
29
30
31
32
33

4 5 6 7 8 9 10 11 12 13 14 15 16 17 18 19 20 21 22 23 24 25 26 27 28 29 30 31 32 33

A 54-year-old woman comes to the physician because of multiple firm violaceous nodules on her right upper arm. She was diagnosed with right-sided breast carcinoma twelve years ago and was treated with radical mastectomy. Extensive axillary lymph node dissection performed at that time revealed no lymph node metastases. Post-operatively, the patient developed chronic lymphedema involving her right arm. Which of the following is the most likely etiology of her current skin lesions?

A. Venous thrombosis

B. Angiosarcoma

C. Metastatic breast cancer

D. Neurofibromas

E. Cavernous hemangiomas

Submit

4
5
6
7
8
9
10
11
12
13
14
15
16
17
18
19
20
21
22
23
24
25
26
27
28
29
30
31
32
33

A 54-year-old woman comes to the physician because of multiple firm violaceous nodules on her right upper arm. She was diagnosed with right-sided breast carcinoma twelve years ago and was treated with radical mastectomy. Extensive axillary lymph node dissection performed at that time revealed no lymph node metastases. Post-operatively, the patient developed chronic lymphedema involving her right arm. Which of the following is the most likely etiology of her current skin lesions?

A. Venous thrombosis (19%)
✓ B. Angiosarcoma (46%)
C. Metastatic breast cancer (10%)
D. Neurofibromas (5%)
E. Cavernous hemangiomas (18%)

Omitted
Correct answer
B

46%
Answered correctly

02 secs
Time Spent

04/07/2020
Last Updated

Explanation

Chronic lymphedema is a risk factor for the development of cutaneous angiosarcoma, also known as Stewart-Treves syndrome. Radical mastectomy with axillary lymph node dissection is a classic predisposing procedure, although any form of chronic lymphedema can be implicated. Histopathologically, angiosarcoma will show infiltration of the dermis with slit-like abnormal vascular spaces. The prognosis for patients with angiosarcoma is poor because the tumor is usually widespread by the time of diagnosis. There is controversy regarding use of the term angiosarcoma versus lymphangiosarcoma, as it appears that this entity arises from blood vessels rather than from lymphatic vessels.

4
5
6
7
8
9
10
11
12
13
14
15
16
17
18
19
20
21
22
23
24
25
26
27
28
29
30
31
32
33

Chronic lymphedema is a risk factor for the development of cutaneous angiosarcoma, also known as Stewart-Treves syndrome. Radical mastectomy with axillary lymph node dissection is a classic predisposing procedure, although any form of chronic lymphedema can be implicated. Histopathologically, angiosarcoma will show infiltration of the dermis with slit-like abnormal vascular spaces. The prognosis for patients with angiosarcoma is poor because the tumor is usually widespread by the time of diagnosis. There is controversy regarding use of the term angiosarcoma versus lymphangiosarcoma, as it appears that this entity arises from blood vessels rather than from lymphatic vessels.

(Choice A) Thrombosis of the subclavian or axillary vein most frequently occurs as a complication of a chronic indwelling catheter.

(Choice C) Metastatic breast cancer is most likely to travel to bone, liver, and lung tissue. While it can have cutaneous metastases (usually affecting the anterior chest wall), the absence of lymphatic metastases on initial lymph node dissection makes this diagnosis less likely in this patient.

(Choice D) Neurofibromas are soft, rubbery, asymptomatic cutaneous nodules that commonly appear during the second and third decades of life.

(Choice E) Hemangiomas are benign congenital vascular neoplasms that affect infants. Hemangiomas often enlarge in the months following birth before spontaneously involuting. A cavernous hemangioma is a deep hemangioma.

Educational objective:
Axillary lymph node dissection is a risk factor for the development of chronic lymphedema involving the ipsilateral arm. Chronic lymphedema predisposes to the development of angiosarcoma (Stewart-Treves syndrome).

References

- MRI of angiosarcoma associated with chronic lymphoedema: Stewart Treves syndrome.
- Images in clinical medicine. The Stewart-Treves syndrome.

Pathology	Dermatology	Lymphedema
Subject	System	Topic

Copyright © UWorld. All rights reserved.

4
5
6
7
8
9
10
11
12
13
14
15
16
17
18
19
20
21
22
23
24
25
26
27
28
29
30
31
32
33

A 28-year-old previously healthy woman comes to the office for evaluation of a raised, pigmented skin lesion on her leg. The patient has had no itching or pain and cannot remember how long she has had the lesion. She has used tanning machines a few times in the past but denies excessive sun exposure. She is particularly concerned about the risk of malignancy as her father was recently diagnosed with skin cancer. Skin examination shows the nodule seen in the image below.

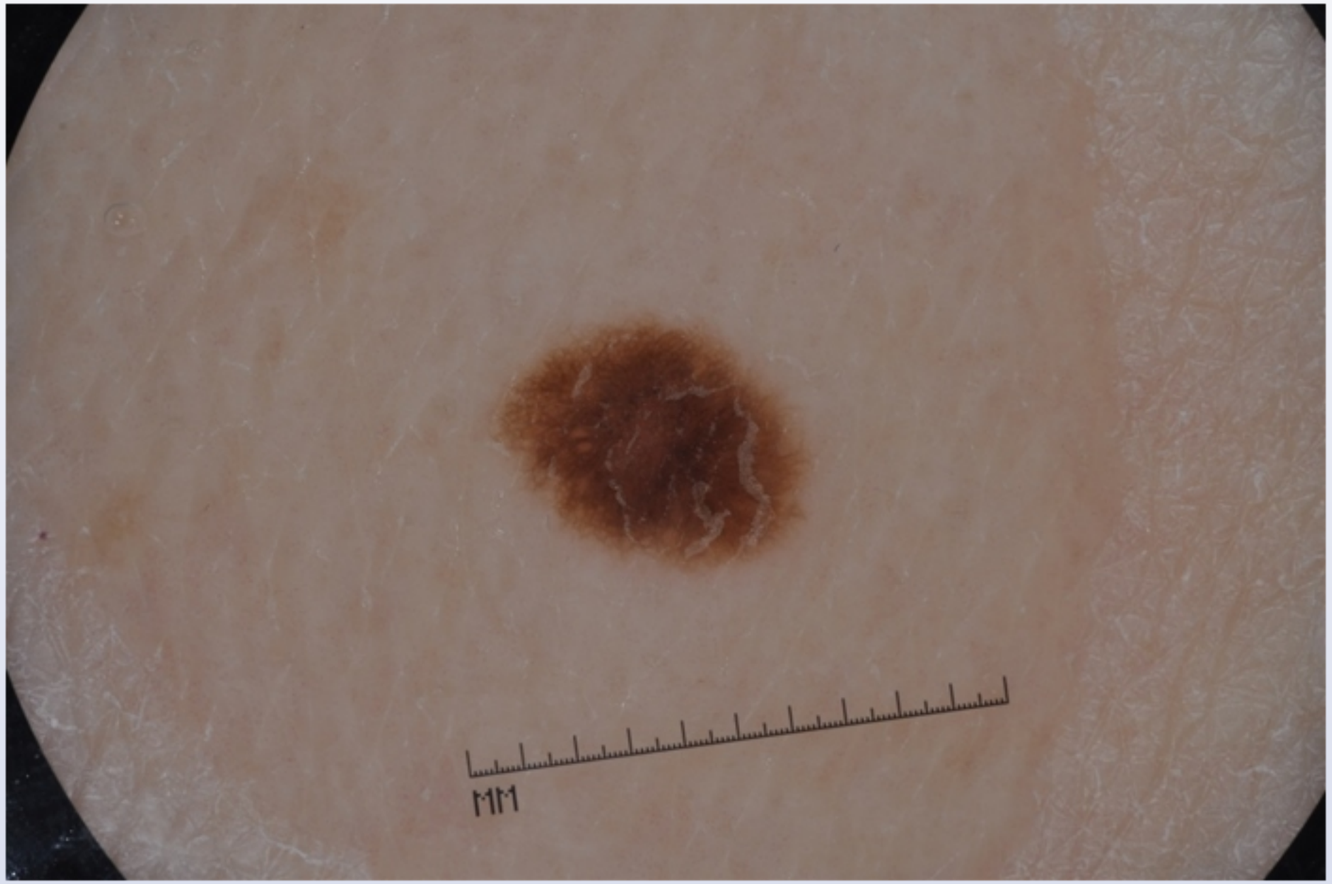

A biopsy of the lesion reveals nests of uniform round cells at the basal portion of the epidermis that extend into the underlying dermis. The cells

4
5
6
7
8
9
10
11
12
13
14
15
16
17
18
19
20
21
22
23
24
25
26
27
28
29
30
31
32
33

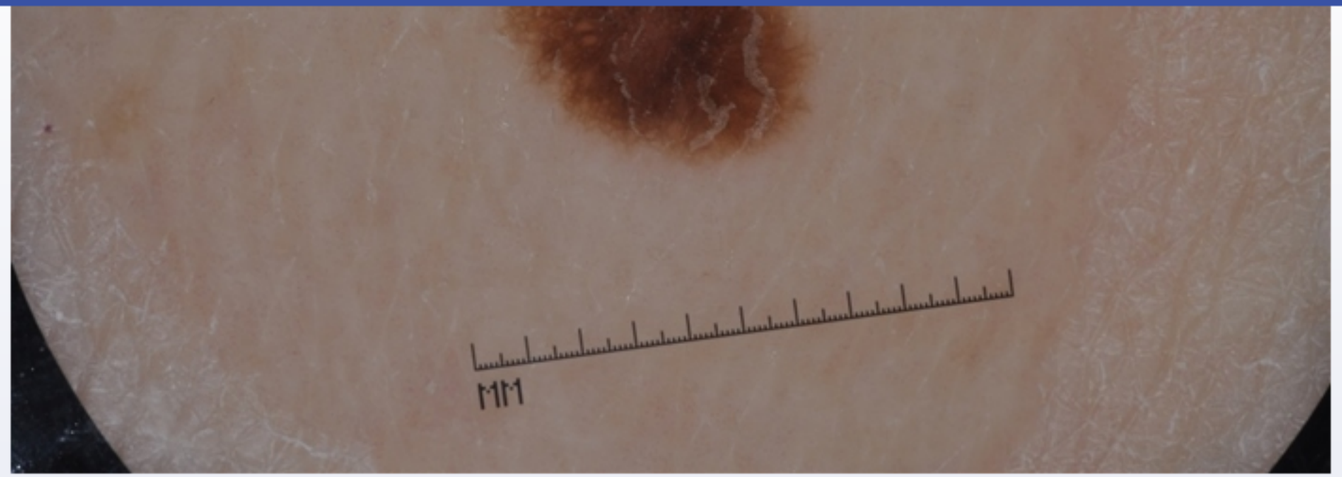

A biopsy of the lesion reveals nests of uniform round cells at the basal portion of the epidermis that extend into the underlying dermis. The cells contain inconspicuous nucleoli and show no mitotic activity. Which of the following is the most likely diagnosis?

- A. Atypical skin mole
- B. Compound melanocytic nevus
- C. Junctional nevus
- D. Malignant melanoma
- E. Pigmented basal cell carcinoma
- F. Seborrheic keratosis

Submit

4
5
6
7
8
9
10
11
12
13
14
15
16
17
18
19
20
21
22
23
24
25
26
27
28
29
30
31
32
33

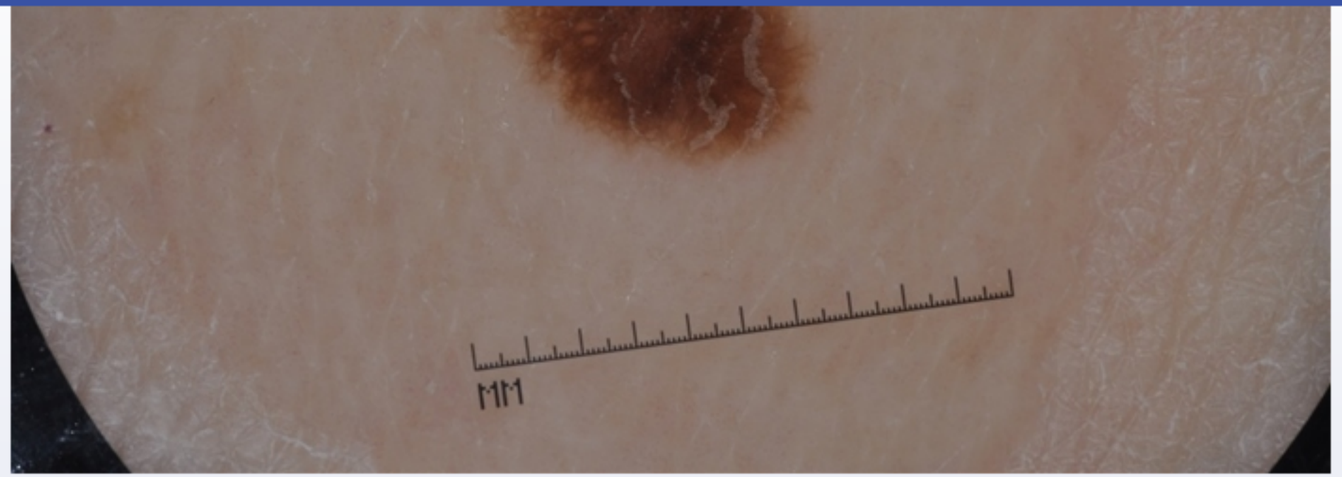

A biopsy of the lesion reveals nests of uniform round cells at the basal portion of the epidermis that extend into the underlying dermis. The cells contain inconspicuous nucleoli and show no mitotic activity. Which of the following is the most likely diagnosis?

- A. Atypical skin mole (5%)
- ✓ B. Compound melanocytic nevus (40%)
- C. Junctional nevus (35%)
- D. Malignant melanoma (10%)
- E. Pigmented basal cell carcinoma (4%)
- F. Seborrheic keratosis (2%)

Omitted
Correct answer

40%
Answered correctly

04 secs
Time Spent

04/27/2020
Last Updated

4
5
6
7
8
9
10
11
12
13
14
15
16
17
18
19
20
21
22
23
24
25
26
27
28
29
30
31
32
33

Histology of nevi

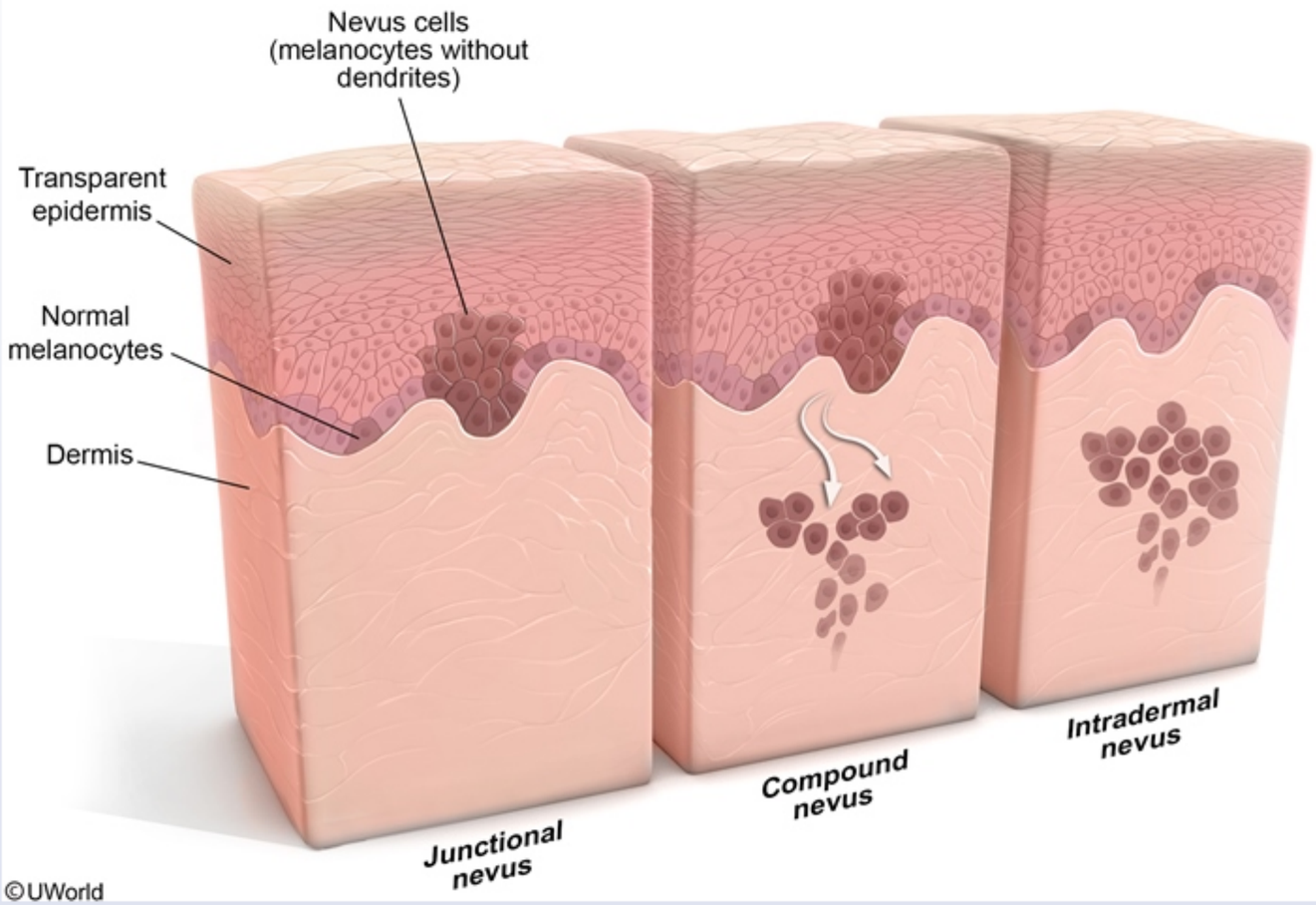

Melanocytic nevi are benign neoplasms composed of round, uniform melanocytes (nevus cells) that are mitotically quiescent. They are typically ≤6 mm in diameter, and have a regular outline with a symmetrical, sharply demarcated border and a homogenous surface. Melanocytic nevi are progressive lesions that typically mature through the following phases:

1. Junctional nevi are characterized by aggregates of nevus cells limited to the dermoepidermal junction (Choice C). They typically appear as

4
5
6
7
8
9
10
11
12
13
14
15
16
17
18
19
20
21
22
23
24
25
26
27
28
29
30
31
32
33

Melanocytic nevi are benign neoplasms composed of round, uniform melanocytes (nevus cells) that are mitotically quiescent. They are typically ≤6 mm in diameter, and have a regular outline with a symmetrical, sharply demarcated border and a homogenous surface. Melanocytic nevi are progressive lesions that typically mature through the following phases:

1. Junctional nevi are characterized by aggregates of nevus cells limited to the dermoepidermal junction **(Choice C)**. They typically appear as flat, black- to brown-pigmented macules with darker coloration in the center than the periphery and preserved skin markings.
2. **Compound nevi** form as the aggregates of nevus cells extend into the dermis. Compound nevi are raised papules with uniform brown to tan pigmentation. This patient's lesion is a compound nevus as it has **both dermal** and **epidermal** involvement.
3. Intradermal nevi are considered to be older lesions in which the epidermal nests of nevus cells have been lost. The remaining dermal nevus cells lose tyrosinase activity and produce little to no pigment. Intradermal nevi are skin- to tan-colored, dome-shaped, and sometimes pedunculated.

(Choices A and D) Malignant melanoma is characterized by irregular and asymmetrical borders with variable coloration, diameter >5 mm, and evolution over time. Melanomas typically expand superficially at first but may extend vertically into the dermis and subcutaneous tissues, portending a poor prognosis. Compared to nevus cells, melanoma cells are larger, contain larger nuclei with prominent nucleoli, and have greater mitotic activity. Atypical (dysplastic) nevi can resemble melanoma but typically have less extreme features. The melanocytes commonly show cellular atypia and form coalescing nests that may fuse into a continuous layer at the dermoepidermal border.

(Choice E) Pigmented basal cell carcinoma can present as papules, nodules, or plaques with rolled borders on sun-exposed areas. They can have varying degrees of pigmentation due to functional melanocytes within the lesion. The tumor cells resemble basal epidermal cells but extend into the dermis and form clusters with a palisade arrangement of peripheral cells.

(Choice F) Seborrheic keratosis forms a hyperpigmented lesion with well-circumscribed borders, a dull surface, and a "stuck-on" appearance. On microscopic examination, the lesions are composed of small cells resembling basal cells, with variable pigmentation, hyperkeratosis, and keratin-containing cysts.

Educational objective:
Compound nevi are benign proliferations of melanocytes that involve both the dermis and epidermis. The lesions appear as slightly raised papules with uniform pigmentation and symmetrical sharp borders.

Settings

Item 23 of 40
Question Id: 11502

Mark | Previous | Next | Full Screen | Tutorial | Lab Values | Notes | Calculator | Reverse Color | Text Zoom | Settings

Exhibit Display

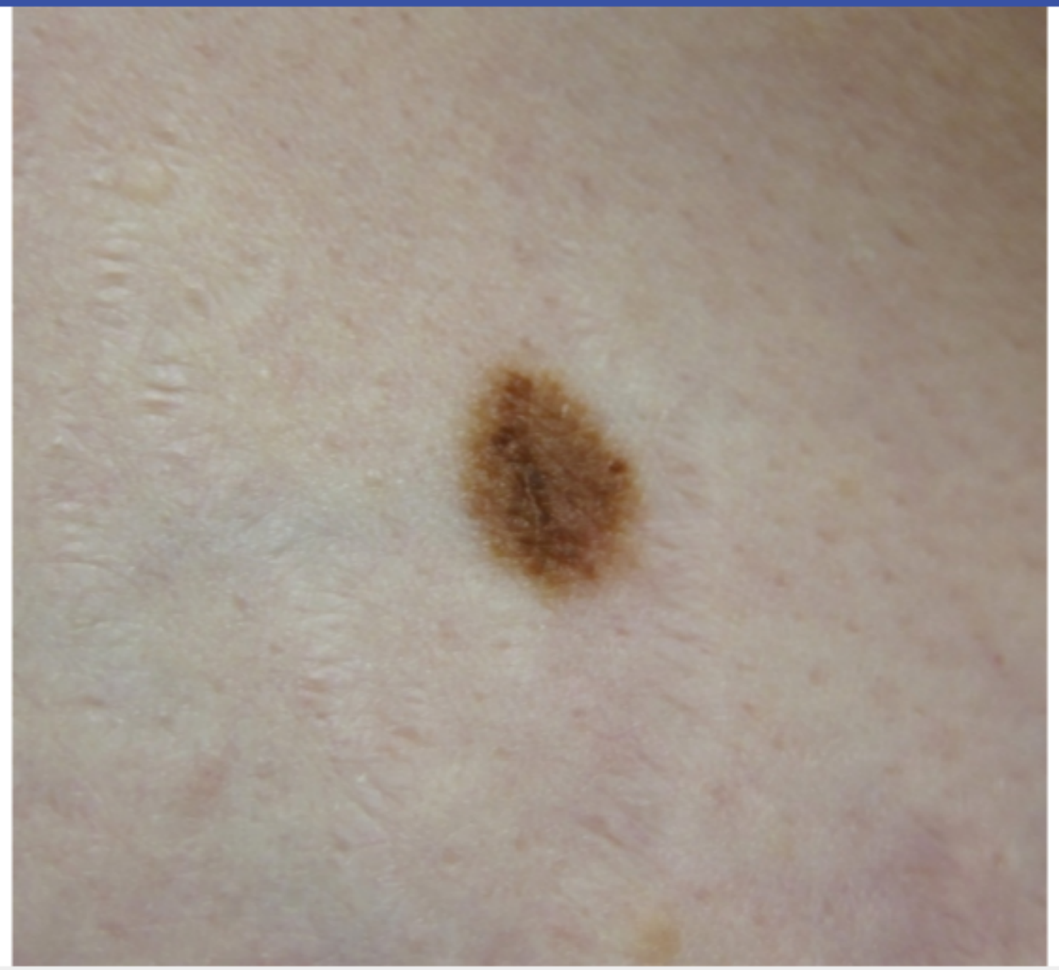

Zoom In | Zoom Out | Reset | Add To New Card | Existing Card

Block Time Remaining: 00:01:53
TUTOR

10 | Feedback | Suspend | End Block

Settings

Item 23 of 40
Question Id: 11502

Mark | Previous | Next | Full Screen | Tutorial | Lab Values | Notes | Calculator | Reverse Color | Text Zoom | Settings

Exhibit Display

Zoom In | Zoom Out | Reset | Add To New Card | Existing Card

Block Time Remaining: 00:01:53
TUTOR

10 | Feedback | Suspend | End Block

Settings

Item 23 of 40
Question Id: 11502

Mark | Previous | Next | Full Screen | Tutorial | Lab Values | Notes | Calculator | Reverse Color | Text Zoom | Settings

Exhibit Display

Zoom In | Zoom Out | Reset | Add To New Card | Existing Card

Block Time Remaining: 00:01:53
TUTOR

10 | Feedback | Suspend | End Block

Settings

Item 23 of 40
Question Id: 11502

Mark | Previous | Next | Full Screen | Tutorial | Lab Values | Notes | Calculator | Reverse Color | Text Zoom | Settings

Exhibit Display

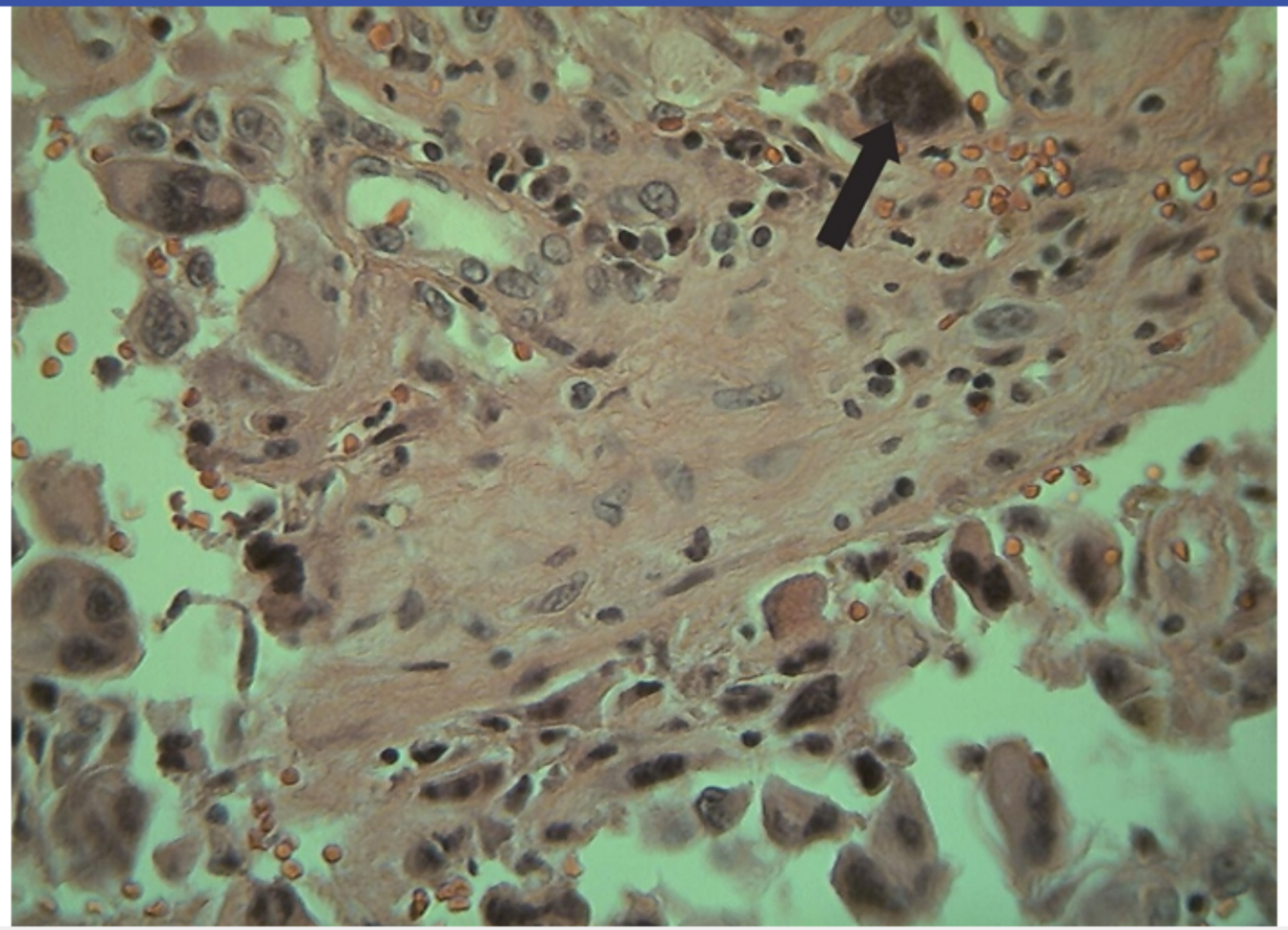

Zoom In | Zoom Out | Reset | Add To New Card | Existing Card

Block Time Remaining: 00:01:53
TUTOR

10 | Feedback | Suspend | End Block

Settings

Item 23 of 40
Question Id: 11502

Mark | Previous | Next | Full Screen | Tutorial | Lab Values | Notes | Calculator | Reverse Color | Text Zoom | Settings

Exhibit Display

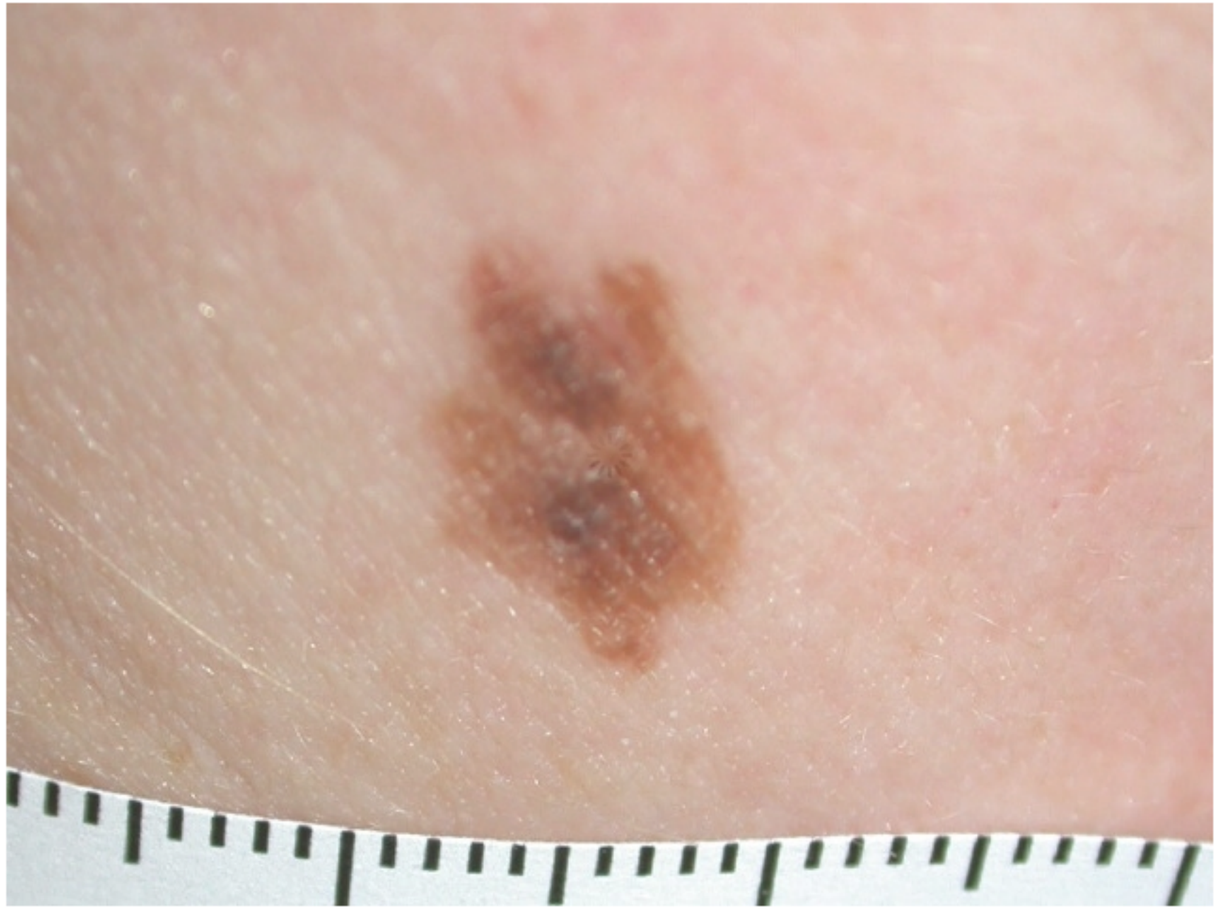

Zoom In | Zoom Out | Reset | Add To New Card | Existing Card

Block Time Remaining: 00:01:53
TUTOR

10 | Feedback | Suspend | End Block

Settings

4
5
6
7
8
9
10
11
12
13
14
15
16
17
18
19
20
21
22
23
24
25
26
27
28
29
30
31
32
33

Item 23 of 40
Question Id: 11502

Mark | Previous | Next | Full Screen | Tutorial | Lab Values | Notes | Calculator | Reverse Color | Text Zoom | Settings

Exhibit Display

Zoom In | Zoom Out | Reset | Add To New Card | Existing Card

Block Time Remaining: 00:01:53
TUTOR

10 | Feedback | Suspend | End Block

Settings

Item 23 of 40
Question Id: 11502

Mark | Previous | Next | Full Screen | Tutorial | Lab Values | Notes | Calculator | Reverse Color | Text Zoom | Settings

Exhibit Display

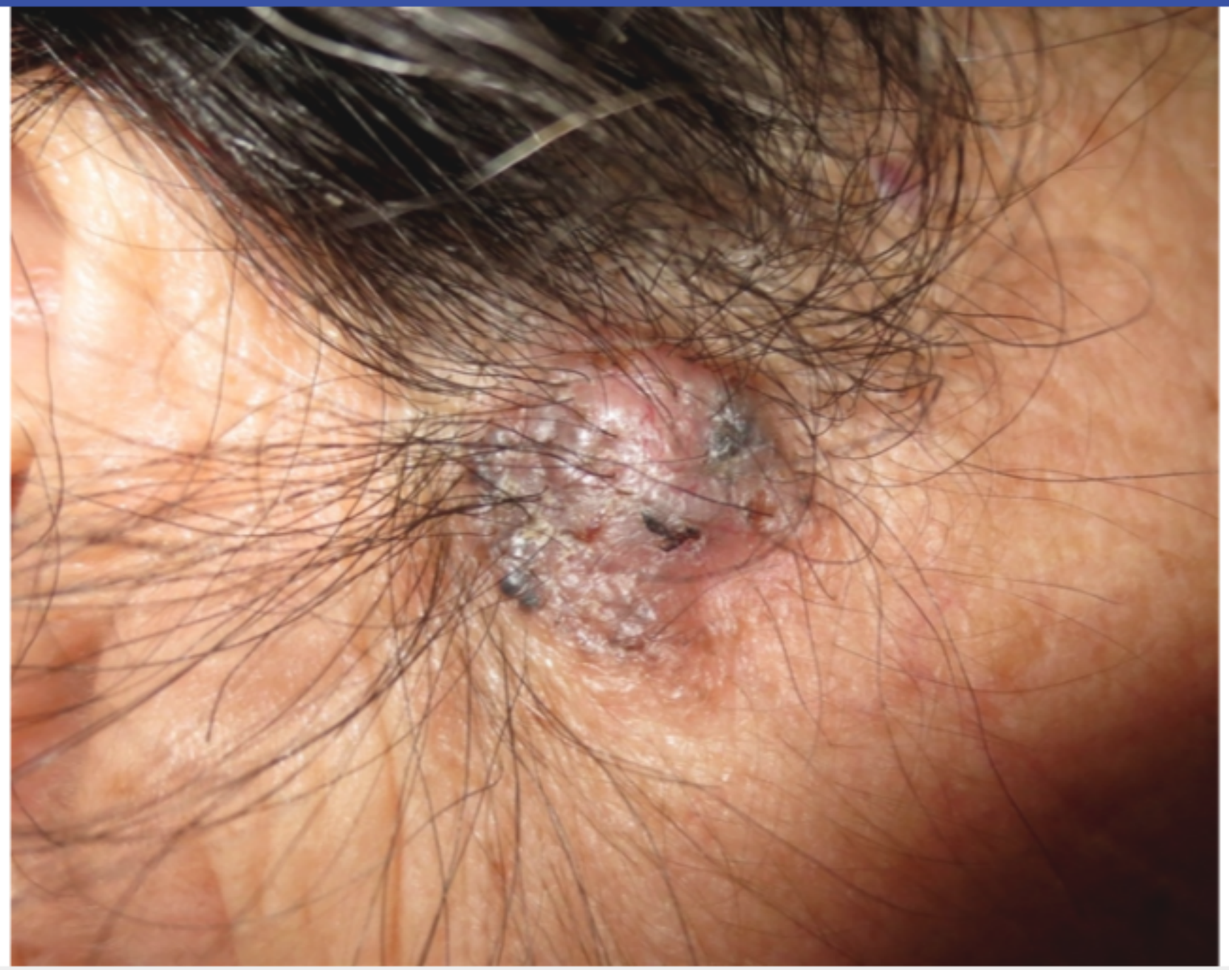

Zoom In | Zoom Out | Reset | Add To New Card | Existing Card

Block Time Remaining: 00:01:53
TUTOR

10 | Feedback | Suspend | End Block

Settings

Item 23 of 40
Question Id: 11502

Mark | Previous | Next | Full Screen | Tutorial | Lab Values | Notes | Calculator | Reverse Color | Text Zoom | Settings

Exhibit Display

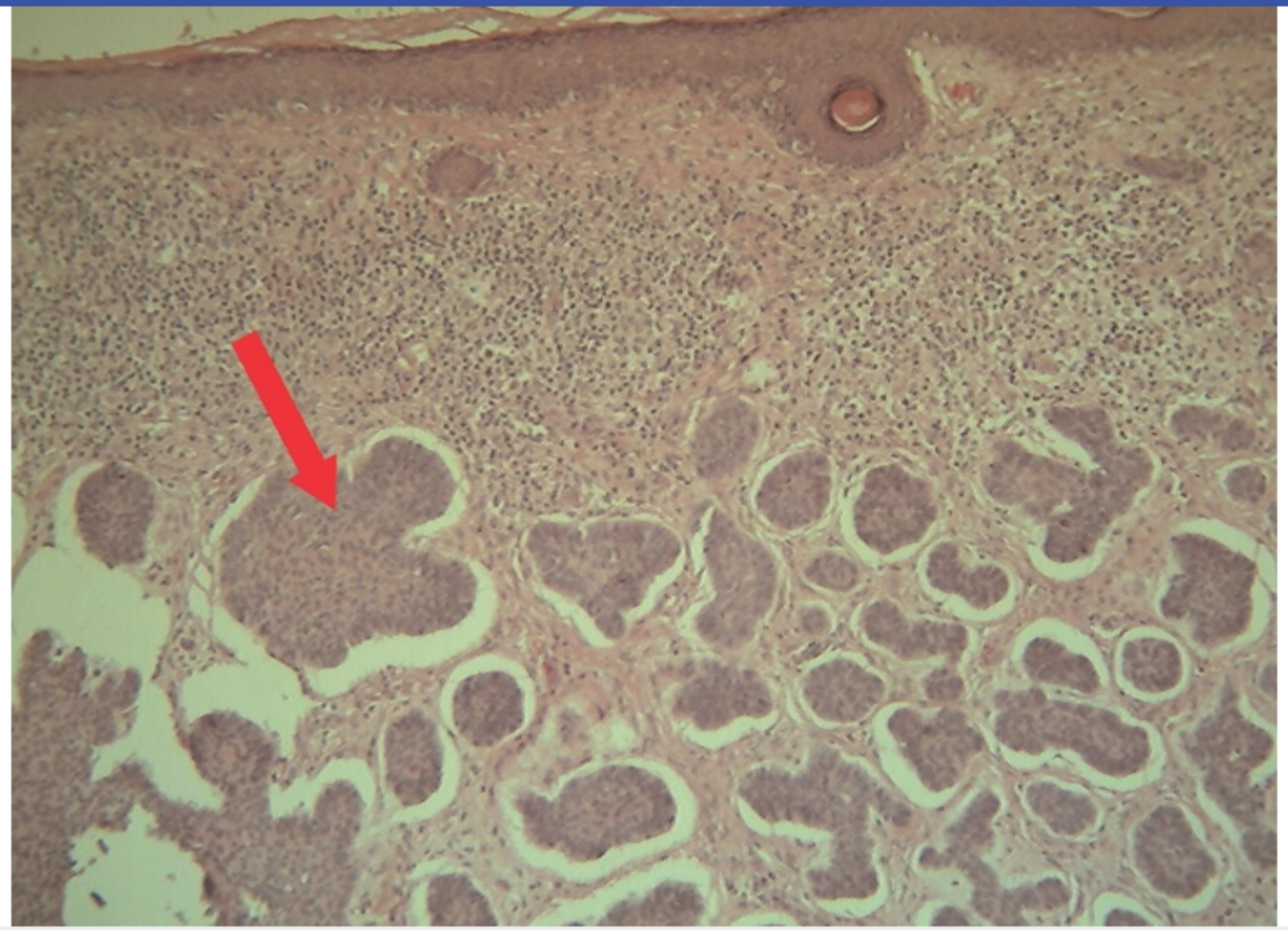

Zoom In | Zoom Out | Reset | Add To New Card | Existing Card

Block Time Remaining: 00:01:53
TUTOR

10 | Feedback | Suspend | End Block

Settings

Item 23 of 40
Question Id: 11502

Mark | Previous | Next | Full Screen | Tutorial | Lab Values | Notes | Calculator | Reverse Color | Text Zoom | Settings

3. Intradermal nevi are considered to be older lesions in which the epidermal nests of nevus cells have been lost. The remaining dermal nevus

Exhibit Display

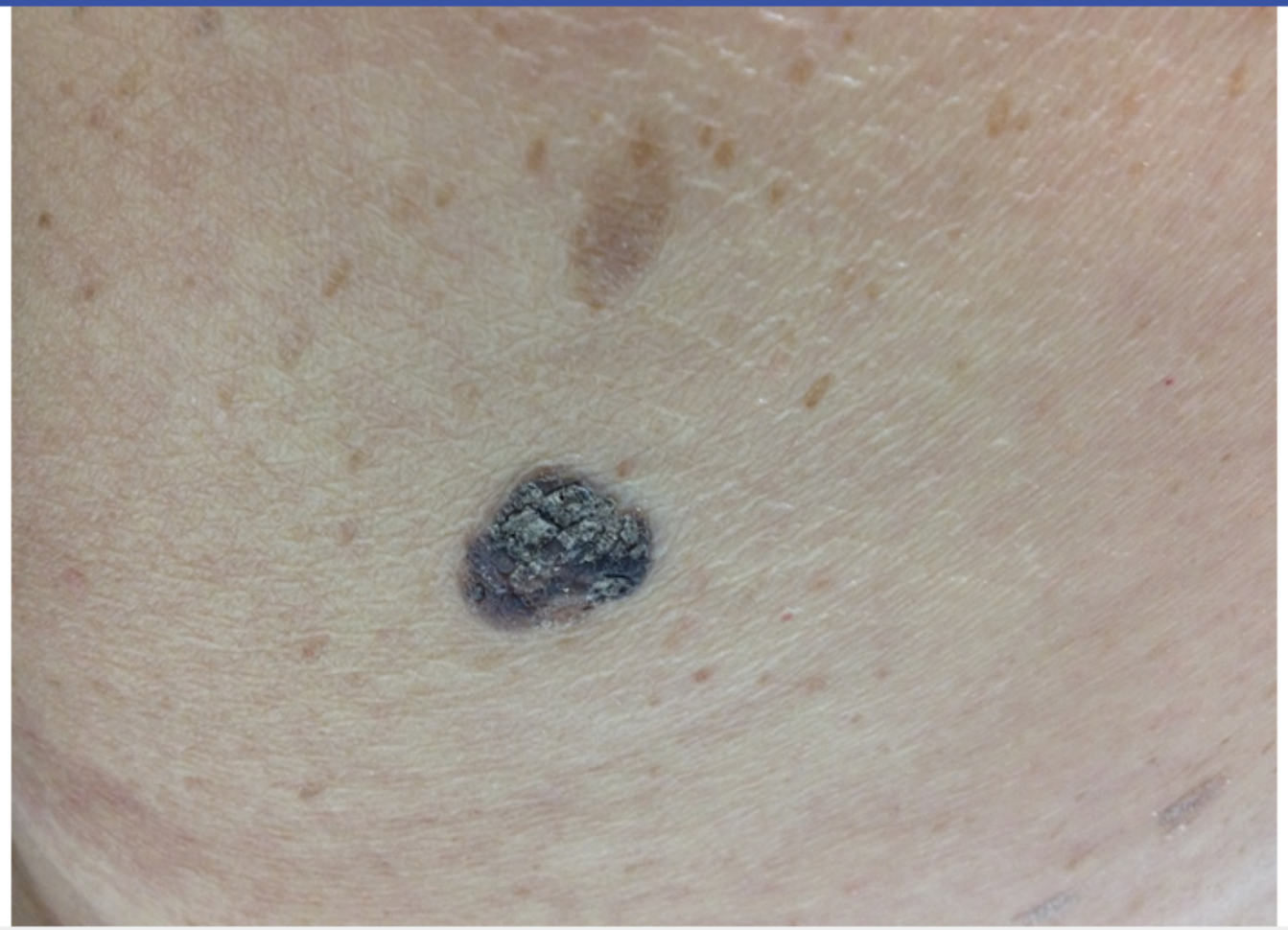

Zoom In | Zoom Out | Reset | Add To New Card | Existing Card

Block Time Remaining: 00:01:53
TUTOR

10 | Feedback | Suspend | End Block

Settings

4
5
6
7
8
9
10
11
12
13
14
15
16
17
18
19
20
21
22
23
24
25
26
27
28
29
30
31
32
33

Item 23 of 40
Question Id: 11502

Mark | Previous | Next | Full Screen | Tutorial | Lab Values | Notes | Calculator | Reverse Color | Text Zoom | Settings

3. Intradermal nevi are considered to be older lesions in which the epidermal nests of nevus cells have been lost. The remaining dermal nevus

Exhibit Display

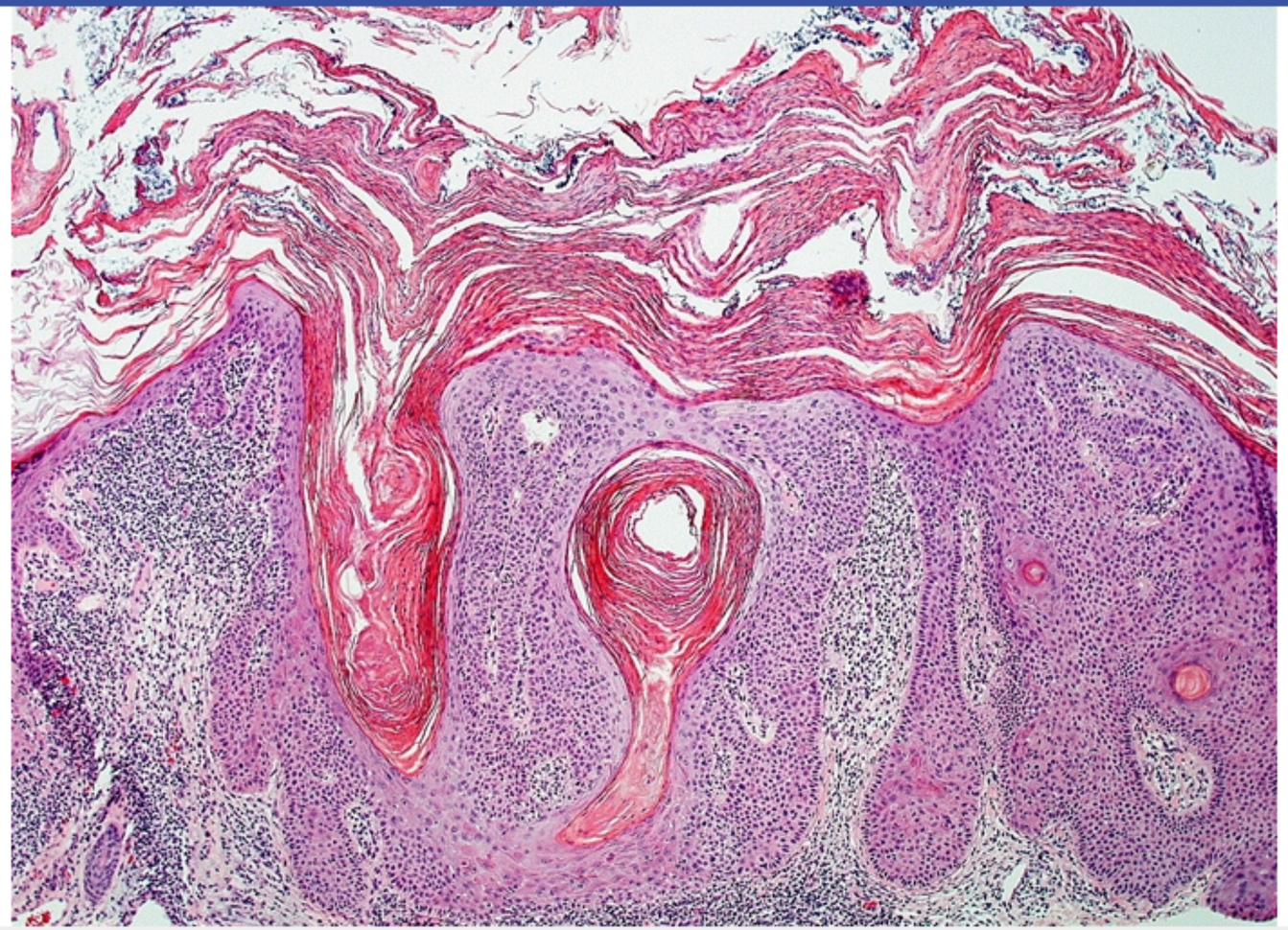

Zoom In | Zoom Out | Reset | Add To New Card | Existing Card

Block Time Remaining: 00:01:53
TUTOR

10 | Feedback | Suspend | End Block

4
5
6
7
8
9
10
11
12
13
14
15
16
17
18
19
20
21
22
23
24
25
26
27
28
29
30
31
32
33

A 35-year-old man comes to the office for evaluation of red skin lesions under his nipple that were first noticed by his wife. The lesions are not itchy or painful, and no other family members have skin lesions. He has not used any new soaps, lotions, or detergents. The patient has no known medical problems and takes no medications. He drinks 4-6 beers every night. He does not use tobacco or illicit drugs. Body mass index is 32kg/m2, and vital signs are normal. The skin findings are shown below.

Which of the following is the most likely diagnosis in this patient?

- A. Acrochordon
- B. Cavernous hemangioma

4
5
6
7
8
9
10
11
12
13
14
15
16
17
18
19
20
21
22
23
24
25
26
27
28
29
30
31
32
33

Which of the following is the most likely diagnosis in this patient?

- A. Acrochordon
- B. Cavernous hemangioma
- C. Cherry hemangioma
- D. Cystic hygroma
- E. Spider angioma
- F. Strawberry hemangioma

Submit

4
5
6
7
8
9
10
11
12
13
14
15
16
17
18
19
20
21
22
23
24
25
26
27
28
29
30
31
32
33

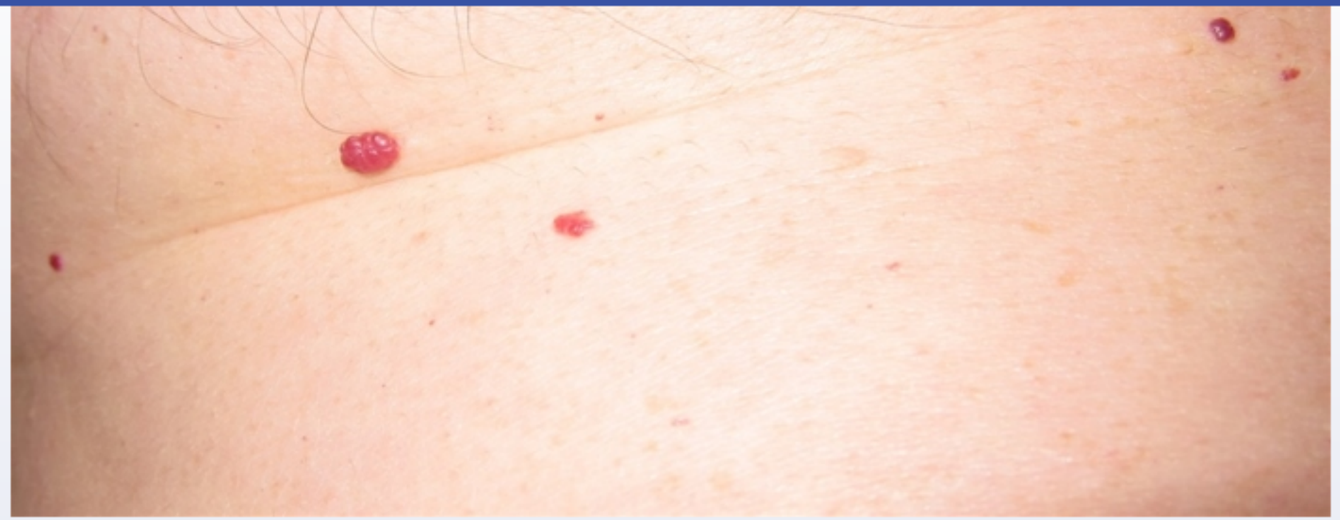

Which of the following is the most likely diagnosis in this patient?

- A. Acrochordon (2%)
- B. Cavernous hemangioma (4%)
- ✓ C. Cherry hemangioma (77%)
- D. Cystic hygroma (0%)
- E. Spider angioma (2%)
- F. Strawberry hemangioma (11%)

Omitted
Correct answer

77%
Answered correctly

05 secs
Time Spent

04/14/2020
Last Updated

4
5
6
7
8
9
10
11
12
13
14
15
16
17
18
19
20
21
22
23
24
25
26
27
28
29
30
31
32
33

Explanation

This patient's **small, bright-red**, papular lesions are **cherry hemangiomas**, also known as cherry angiomas or senile hemangiomas. They are the most common **benign vascular tumors in adults** and typically appear during the third or fourth decade of life. The lesions do not regress spontaneously and often **multiply** with age. Cherry hemangiomas are always superficial on the skin and are not found on the mucosa or deep tissues. Histologically, they appear as sharply circumscribed areas of congested capillaries and post-capillary venules in the papillary dermis.

(Choice A) Acrochordons (skin tags) are pedunculated outgrowths of normal skin. They are typically seen in areas of friction (eg, neck, axilla, inframammary, groin) of patients with obesity and diabetes mellitus.

(Choice B) Cavernous hemangiomas consist of dilated vascular spaces with thin-walled endothelial cells. They present as soft blue, compressible masses up to a few centimeters in size. They may appear on the skin, mucosa, deep tissues, and viscera. When cavernous hemangiomas appear on the skin, they are most frequently based in the dermis.

(Choice D) Cystic hygromas are comprised of lymphatic cysts lined by a thin endothelium. These benign tumors are often present at birth and are most commonly located on the posterior neck and lateral chest wall. Cystic hygromas are frequently found in neonates with Turner syndrome and Down syndrome.

(Choice E) Spider angiomas consist of a bright red central papule surrounded by several outwardly radiating vessels that blanch with pressure and refill centrifugally upon release. They are associated with increased estrogen states (eg, pregnancy, cirrhosis, oral contraceptive use, estrogen supplement use).

(Choice F) Strawberry (also known as infantile or capillary) hemangiomas appear during the first weeks of life. They initially grow rapidly and then frequently regress spontaneously by late childhood. They are bright red when near the epidermis and more violaceous when deeper.

Educational objective:
Cherry hemangiomas are small, red, cutaneous papules common in aging adults. They do not regress spontaneously and typically increase in number with age. Light microscopy of these lesions shows proliferation of capillaries and post-capillary venules in the papillary dermis.

References

- Diagnosis and management of infantile hemangiomas.

Settings

Item 24 of 40
Question Id: 826

Mark | Previous | Next | Full Screen | Tutorial | Lab Values | Notes | Calculator | Reverse Color | Text Zoom | Settings

Explanation

Exhibit Display

Zoom In | Zoom Out | Reset | Add To New Card | Existing Card

Block Time Remaining: 00:01:58
TUTOR

Feedback | Suspend | End Block

4
5
6
7
8
9
10
11
12
13
14
15
16
17
18
19
20
21
22
23
24
25
26
27
28
29
30
31
32
33

Explanation

This patient's **small, brigh**
the most common **benign**
spontaneously and often r
tissues. Histologically, the

(Choice A) Acrochordons
inframammary, groin) of p

(Choice B) Cavernous he
compressible masses up t
hemangiomas appear on t

(Choice D) Cystic hygron
are most commonly locate
and Down syndrome.

(Choice E) Spider angior
and refill centrifugally upo
estrogen supplement use)

(Choice F) Strawberry (a
then frequently regress sp

Educational objective:
Cherry hemangiomas are
number with age. Light m

References

- Diagnosis and management of infantile hemangiomas.

Exhibit Display

0:00 / 0:14

Settings

Item 24 of 40
Question Id: 826

Mark | Previous | Next | Full Screen | Tutorial | Lab Values | Notes | Calculator | Reverse Color | Text Zoom | Settings

Explanation

Exhibit Display

Zoom In | Zoom Out | Reset | Add To New Card | Existing Card

Block Time Remaining: 00:01:58
TUTOR

Feedback | Suspend | End Block

4
5
6
7
8
9
10
11
12
13
14
15
16
17
18
19
20
21
22
23
24
25
26
27
28
29
30
31
32
33

tissues. Histologically, they appear as sharply circumscribed areas of congested capillaries and post-capillary venules in the papillary dermis.

(Choice A) Acrochordons (skin tags) are pedunculated outgrowths of normal skin. They are typically seen in areas of friction (eg, neck, axilla, inframammary, groin) of patients with obesity and diabetes mellitus.

(Choice B) Cavernous hemangiomas consist of dilated vascular spaces with thin-walled endothelial cells. They present as soft blue, compressible masses up to a few centimeters in size. They may appear on the skin, mucosa, deep tissues, and viscera. When cavernous hemangiomas appear on the skin, they are most frequently based in the dermis.

(Choice D) Cystic hygromas are comprised of lymphatic cysts lined by a thin endothelium. These benign tumors are often present at birth and are most commonly located on the posterior neck and lateral chest wall. Cystic hygromas are frequently found in neonates with Turner syndrome and Down syndrome.

(Choice E) Spider angiomas consist of a bright red central papule surrounded by several outwardly radiating vessels that blanch with pressure and refill centrifugally upon release. They are associated with increased estrogen states (eg, pregnancy, cirrhosis, oral contraceptive use, estrogen supplement use).

(Choice F) Strawberry (also known as infantile or capillary) hemangiomas appear during the first weeks of life. They initially grow rapidly and then frequently regress spontaneously by late childhood. They are bright red when near the epidermis and more violaceous when deeper.

Educational objective:
Cherry hemangiomas are small, red, cutaneous papules common in aging adults. They do not regress spontaneously and typically increase in number with age. Light microscopy of these lesions shows proliferation of capillaries and post-capillary venules in the papillary dermis.

References

- Diagnosis and management of infantile hemangiomas.

Pathology	Dermatology	Cherry angioma
Subject	System	Topic

Copyright © UWorld. All rights reserved.

4
5
6
7
8
9
10
11
12
13
14
15
16
17
18
19
20
21
22
23
24
25
26
27
28
29
30
31
32
33

A 26-year-old woman comes to the office due to a skin condition. The patient has had dry and flaky skin since childhood, but it has worsened in recent years. Her symptoms are typically worse in the winter but improve as the weather warms in the spring. The patient has a family history of asthma; both parents also have chronically dry skin. Examination shows diffuse scaling of the skin that is most notable on the extremities, as shown in the exhibit. Which of the following is most likely contributing to this patient's skin condition?

A. Androgen-induced increase in sebum production

B. Autoantibodies against desmogleins 1 and 3

C. Defective keratinocyte desquamation

D. Excessive deposition of collagen

E. T cell–mediated inflammatory reaction

Submit

4
5
6
7
8
9
10
11
12
13
14
15
16
17
18
19
20
21
22
23
24
25
26
27
28
29
30
31
32
33

A 26-year-old woman comes to the office due to a skin condition. The patient has had dry and flaky skin since childhood, but it has worsened in recent years. Her symptoms are typically worse in the winter but improve as the weather warms in the spring. The patient has a family history of asthma; both parents also have chronically dry skin. Examination shows diffuse scaling of the skin that is most notable on the extremities, as shown in the exhibit. Which of the following is most likely contributing to this patient's skin condition?

A. Androgen-induced increase in sebum production (1%)

B. Autoantibodies against desmogleins 1 and 3 (5%)

✓ C. Defective keratinocyte desquamation (65%)

D. Excessive deposition of collagen (5%)

E. T cell–mediated inflammatory reaction (22%)

Omitted
Correct answer
C

65%
Answered correctly

02 secs
Time Spent

05/06/2020
Last Updated

Explanation

This patient has diffuse dermal scaling consistent with **ichthyosis vulgaris**. Ichthyosis vulgaris is an inherited disorder caused by mutations of the **filaggrin gene**. This results in epidermal hyperplasia and **defective keratinocyte desquamation**, leading to the accumulation of **dry**, **scaly skin** with loss of normal barrier function. Filaggrin mutations are also seen in atopic eczema, and ichthyosis vulgaris is frequently associated with a family history of eczema and other atopic disorders (eg, asthma, seasonal allergies).

Ichthyosis vulgaris typically affects the trunk and **extensor surfaces of the extremities** (particularly the legs), with sparing of the flexures and

4
5
6
7
8
9
10
11
12
13
14
15
16
17
18
19
20
21
22
23
24
25
26
27
28
29
30
31
32
33

This patient has diffuse dermal scaling consistent with **ichthyosis vulgaris**. Ichthyosis vulgaris is an inherited disorder caused by mutations of the **filaggrin gene**. This results in epidermal hyperplasia and **defective keratinocyte desquamation**, leading to the accumulation of **dry**, **scaly skin** with loss of normal barrier function. Filaggrin mutations are also seen in atopic eczema, and ichthyosis vulgaris is frequently associated with a family history of eczema and other atopic disorders (eg, asthma, seasonal allergies).

Ichthyosis vulgaris typically affects the trunk and **extensor surfaces of the extremities** (particularly the legs), with sparing of the flexures and face. Palmar hyperlinearity is also common. The symptoms first appear in childhood but may worsen with age, as well as in the winter due to decreased ambient humidity; mild symptoms may be misdiagnosed as simple xerosis (ie, dry skin).

(Choice A) Excessive sebum production is seen in patients with acne vulgaris and seborrheic dermatitis. Although seborrheic dermatitis presents with scaling, it primarily affects the scalp, central face, ears, and chest, and is associated with underlying erythematous plaques.

(Choice B) Autoantibodies against desmogleins 1 and 3 cause pemphigus vulgaris, which is characterized by excessive, premature desquamation. Pemphigus presents with the formation of fragile bullae and the shedding of epidermal sheets, rather than scaling.

(Choice D) Excessive collagen deposition is seen in systemic sclerosis (ie, scleroderma). Systemic sclerosis presents with diffuse thickening and hardening of the skin, often associated with ulcerations at the fingertips.

(Choice E) Allergic contact dermatitis is a type IV (T cell–mediated) hypersensitivity reaction triggered by a variety of allergens (eg, poison ivy, natural rubber, leather dyes). It presents acutely within 2-4 days of exposure with a localized, pruritic, erythematous rash with vesicles and small bullae.

Educational objective:
Ichthyosis vulgaris is characterized by dermal xerosis (dryness) and scaling that primarily affect the trunk and extensor surfaces of the extremities. It is caused by mutations of the filaggrin gene, resulting in epidermal hyperplasia, defective desquamation, and loss of the normal barrier function.

Pathology	Dermatology	Ichthyoses
Subject	System	Topic

Copyright © UWorld. All rights reserved.

Settings

Item 25 of 40
Question Id: 15441

Mark | Previous | Next | Full Screen | Tutorial | Lab Values | Notes | Calculator | Reverse Color | Text Zoom | Settings

Exhibit Display

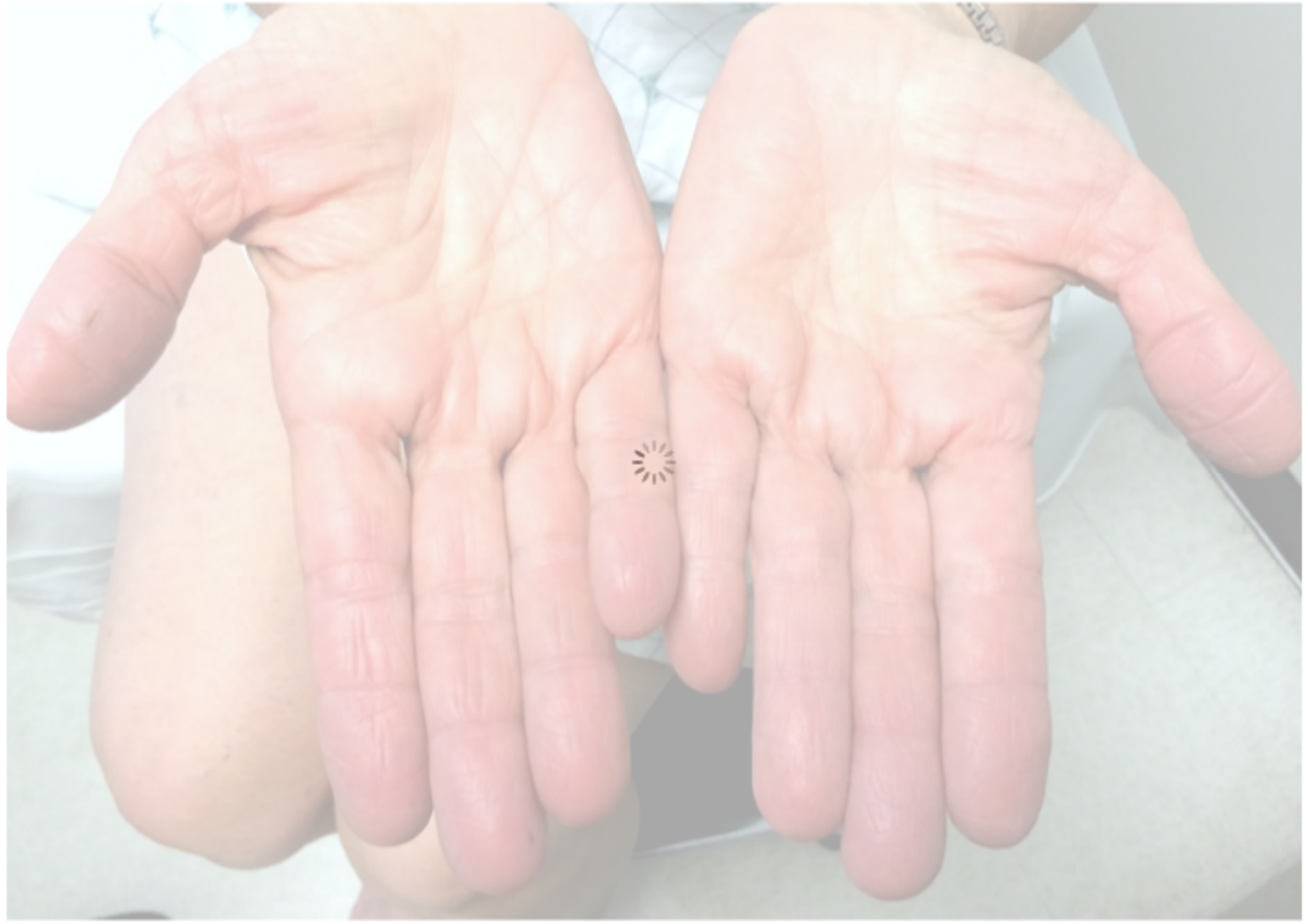

Zoom In | Zoom Out | Reset | Add To Flash Card

Copyright © UWorld. All rights reserved.

Block Time Remaining: 00:02:00
TUTOR

Feedback | Suspend | End Block

Settings

Item 25 of 40
Question Id: 15441

Mark | Previous | Next | Full Screen | Tutorial | Lab Values | Notes | Calculator | Reverse Color | Text Zoom | Settings

Exhibit Display

Zoom In | Zoom Out | Reset | Add To Flash Card

Copyright © UWorld. All rights reserved.

Block Time Remaining: 00:02:00
TUTOR

Feedback | Suspend | End Block

Settings

Item 25 of 40
Question Id: 15441

Mark | Previous | Next | Full Screen | Tutorial | Lab Values | Notes | Calculator | Reverse Color | Text Zoom | Settings

Exhibit Display

Zoom In | Zoom Out | Reset | Add To Flash Card

Copyright © UWorld. All rights reserved.

Block Time Remaining: 00:02:00
TUTOR

Feedback | Suspend | End Block

4
5
6
7
8
9
10
11
12
13
14
15
16
17
18
19
20
21
22
23
24
25
26
27
28
29
30
31
32
33

A 35-year-old man comes to the office for evaluation of a rash on his elbows. The patient has had this rash intermittently for several months, but lately, it has become more persistent and bothersome. He has had mild associated itching but no pain and has tried a topical moisturizing lotion without relief. The patient installs tile floors for a residential construction company. He has no chronic medical conditions and takes no regular medications. The patient does not use tobacco, alcohol, or illicit drugs. Vitals signs are within normal limits. The rash on his elbow is shown below, and a similar rash is present on the other elbow.

4
5
6
7
8
9
10
11
12
13
14
15
16
17
18
19
20
21
22
23
24
25
26
27
28
29
30
31
32
33

below, and a similar rash is present on the other elbow.

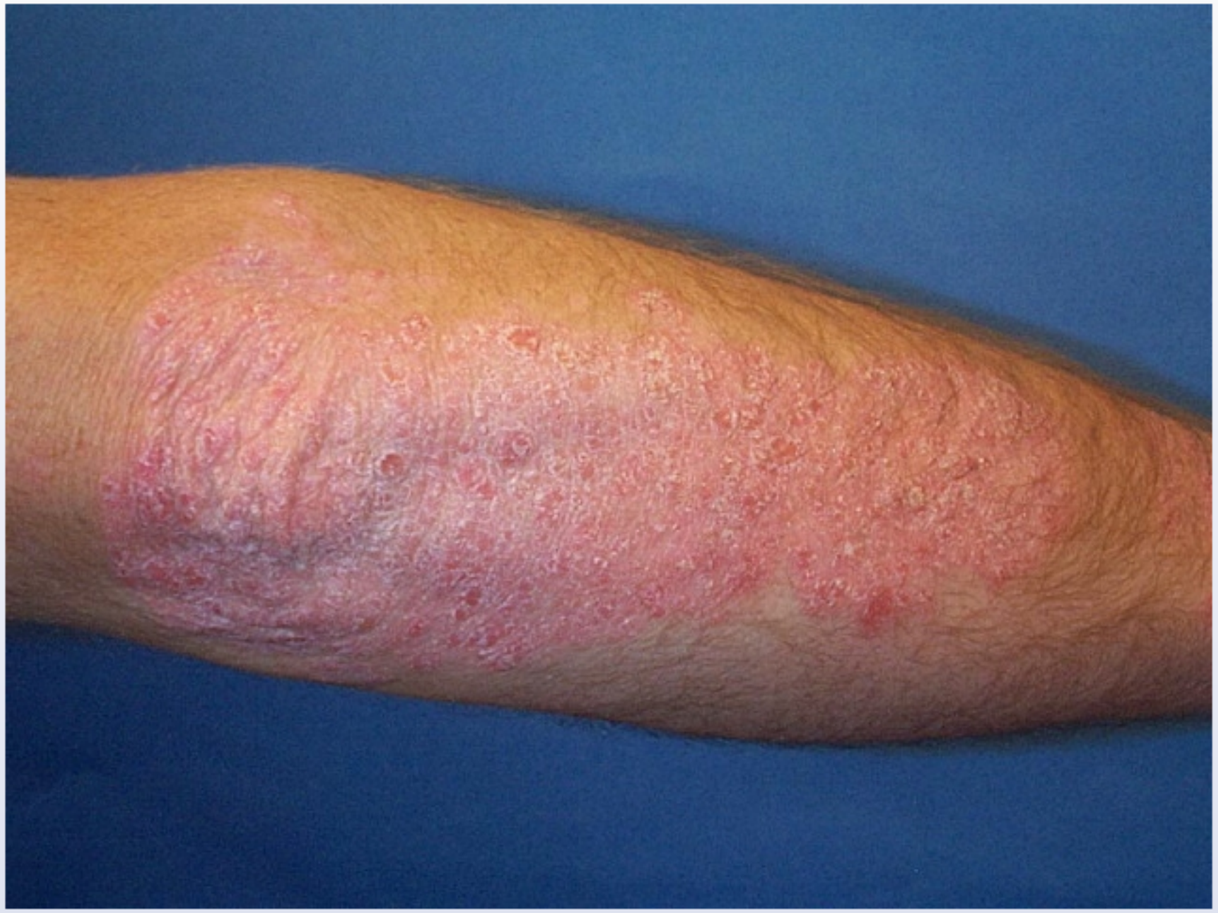

Which of the following histologic changes would be most likely if this patient's skin lesion were biopsied?

A. Epidermal hyperplasia

B. Granulomatous inflammation

4
5
6
7
8
9
10
11
12
13
14
15
16
17
18
19
20
21
22
23
24
25
26
27
28
29
30
31
32
33

Which of the following histologic changes would be most likely if this patient's skin lesion were biopsied?

A. Epidermal hyperplasia

B. Granulomatous inflammation

C. Intense eosinophilic infiltration

D. Squamous cell dysplasia

E. Thinning of the epidermis

Submit

4
5
6
7
8
9
10
11
12
13
14
15
16
17
18
19
20
21
22
23
24
25
26
27
28
29
30
31
32
33

Which of the following histologic changes would be most likely if this patient's skin lesion were biopsied?

- ✓ A. Epidermal hyperplasia (64%)
- B. Granulomatous inflammation (3%)
- C. Intense eosinophilic infiltration (13%)
- D. Squamous cell dysplasia (1%)
- E. Thinning of the epidermis (17%)

Omitted
Correct answer

64%
Answered correctly

07 secs
Time Spent

02/26/2020
Last Updated

4
5
6
7
8
9
10
11
12
13
14
15
16
17
18
19
20
21
22
23
24
25
26
27
28
29
30
31
32
33

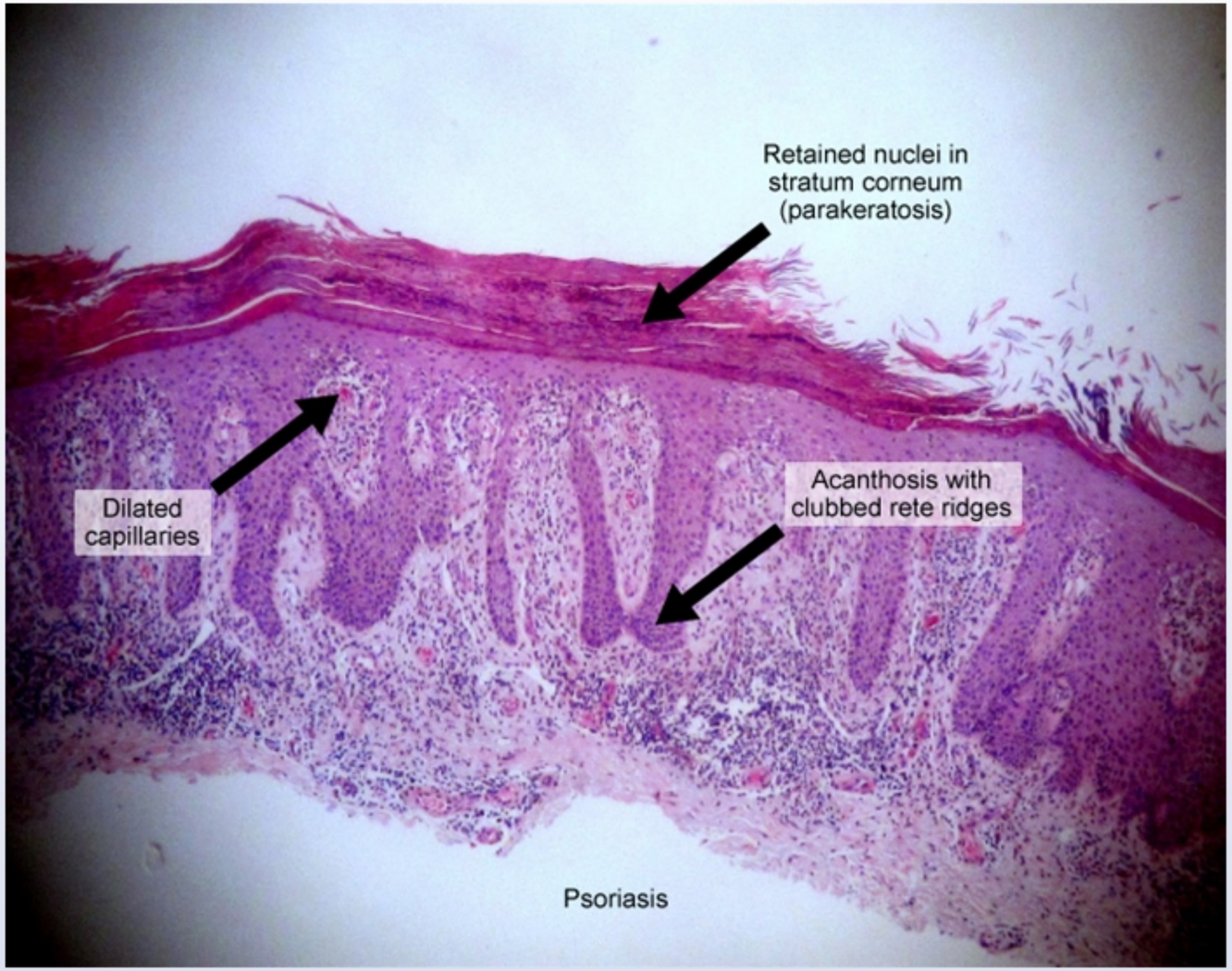

This patient has scaly, erythematous plaques consistent with psoriasis. **Psoriasis** is most common in areas exposed to pressure or friction, such as the extensor surfaces of the elbows and knees, and minor trauma can often precipitate the formation of lesions (**Koebner phenomenon**). In

This patient has scaly, erythematous plaques consistent with psoriasis. **Psoriasis** is most common in areas exposed to pressure or friction, such as the extensor surfaces of the elbows and knees, and minor trauma can often precipitate the formation of lesions (**Koebner phenomenon**). In predisposed individuals, disruption of the epithelial barrier leads to activation of antigen-presenting dendritic cells and subsequently to a self-reinforcing inflammatory cascade characterized by recruitment and activation of T helper cells and **proliferation of keratinocytes**.

On histology, this results in **hyperkeratosis** (thickening of the stratum corneum) and **parakeratosis** (retention of nuclei in the stratum corneum), which produce the characteristic silvery scales seen on gross examination. Additional changes include diffuse **epidermal hyperplasia** (acanthosis), often with elongated and clubbed rete ridges corresponding to the typical erythematous plaques. Perivascular lymphocytes and dilated dermal capillaries are also seen.

(Choice B) A granuloma is a localized, nodular, inflammatory structure composed of aggregates of epithelioid macrophages and multinucleated giant cells. They are seen in a variety of infectious (eg, tuberculosis) and autoimmune (eg, sarcoidosis) diseases but are not seen in psoriasis.

(Choice C) Eosinophilic infiltrates are a common finding in pemphigus vulgaris, atopic skin diseases (eg, atopic eczema, allergic contact dermatitis), and dermatitis herpetiformis. These disorders generally present with vesicle or bulla formation, fragility of the skin, and, often, intense itching. Plaques and scaling, when present, are mainly due to persistent scratching.

(Choice D) Actinic keratosis is characterized by hyperkeratosis and squamous dysplasia and is considered a premalignant lesion to squamous cell carcinoma. It is typically related to chronic ultraviolet exposure and is most common on sun-exposed areas of the scalp, ears, face, and dorsum of the hands.

(Choice E) Thinning of the epidermis is a common feature of scleroderma. Although patients with psoriasis treated with high-potency corticosteroids can develop skin atrophy over time, it is not a presenting feature of the disorder.

Educational objective:
Psoriasis is characterized on histology by hyperkeratosis and confluent parakeratosis of the stratum corneum (producing the characteristic silvery scales seen on gross examination), diffuse epidermal hyperplasia with elongated and clubbed rete ridges (corresponding to the typical erythematous plaques), and dilated capillaries in the dermal papillae.

Pathology Dermatology Psoriasis

This patient has scaly, erythematous plaques consistent with psoriasis. **Psoriasis** is most common in areas exposed to pressure or friction, such

Exhibit Display

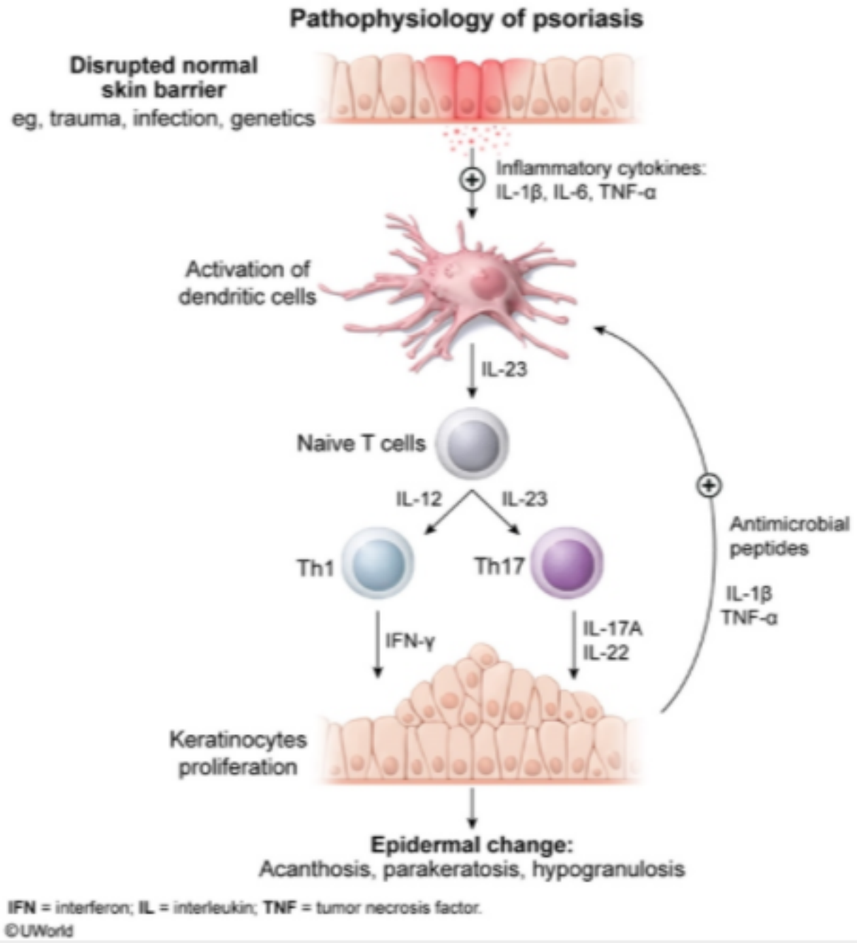

Zoom In | Zoom Out | Reset | Add To New Card | Existing Card

Pathology | Dermatology | Psoriasis

Settings

4
5
6
7
8
9
10
11
12
13
14
15
16
17
18
19
20
21
22
23
24
25
26
27
28
29
30
31
32
33

Item 26 of 40
Question Id: 15408

Mark | Previous | Next | Full Screen | Tutorial | Lab Values | Notes | Calculator | Reverse Color | Text Zoom | Settings

This patient has scaly, erythematous plaques consistent with psoriasis. **Psoriasis** is most common in areas exposed to pressure or friction, such

Exhibit Display

Zoom In | Zoom Out | Reset | Add To New Card | Existing Card

Pathology Dermatology Psoriasis

Block Time Remaining: 00:02:07
TUTOR

5 | Feedback | Suspend | End Block

Settings

4
5
6
7
8
9
10
11
12
13
14
15
16
17
18
19
20
21
22
23
24
25
26
27
28
29
30
31
32
33

Item 26 of 40
Question Id: 15408

Mark | Previous | Next | Full Screen | Tutorial | Lab Values | Notes | Calculator | Reverse Color | Text Zoom | Settings

This patient has scaly, erythematous plaques consistent with psoriasis. **Psoriasis** is most common in areas exposed to pressure or friction, such

Exhibit Display

Zoom In | Zoom Out | Reset | Add To New Card | Existing Card

Pathology Dermatology Psoriasis

Block Time Remaining: 00:02:07
TUTOR

5 | Feedback | Suspend | End Block

4
5
6
7
8
9
10
11
12
13
14
15
16
17
18
19
20
21
22
23
24
25
26
27
28
29
30
31
32
33

A 64-year-old man comes to the physician with several lesions on his forehead. The patient has been a gardener for much of his life. The photograph below shows findings from the physical examination.

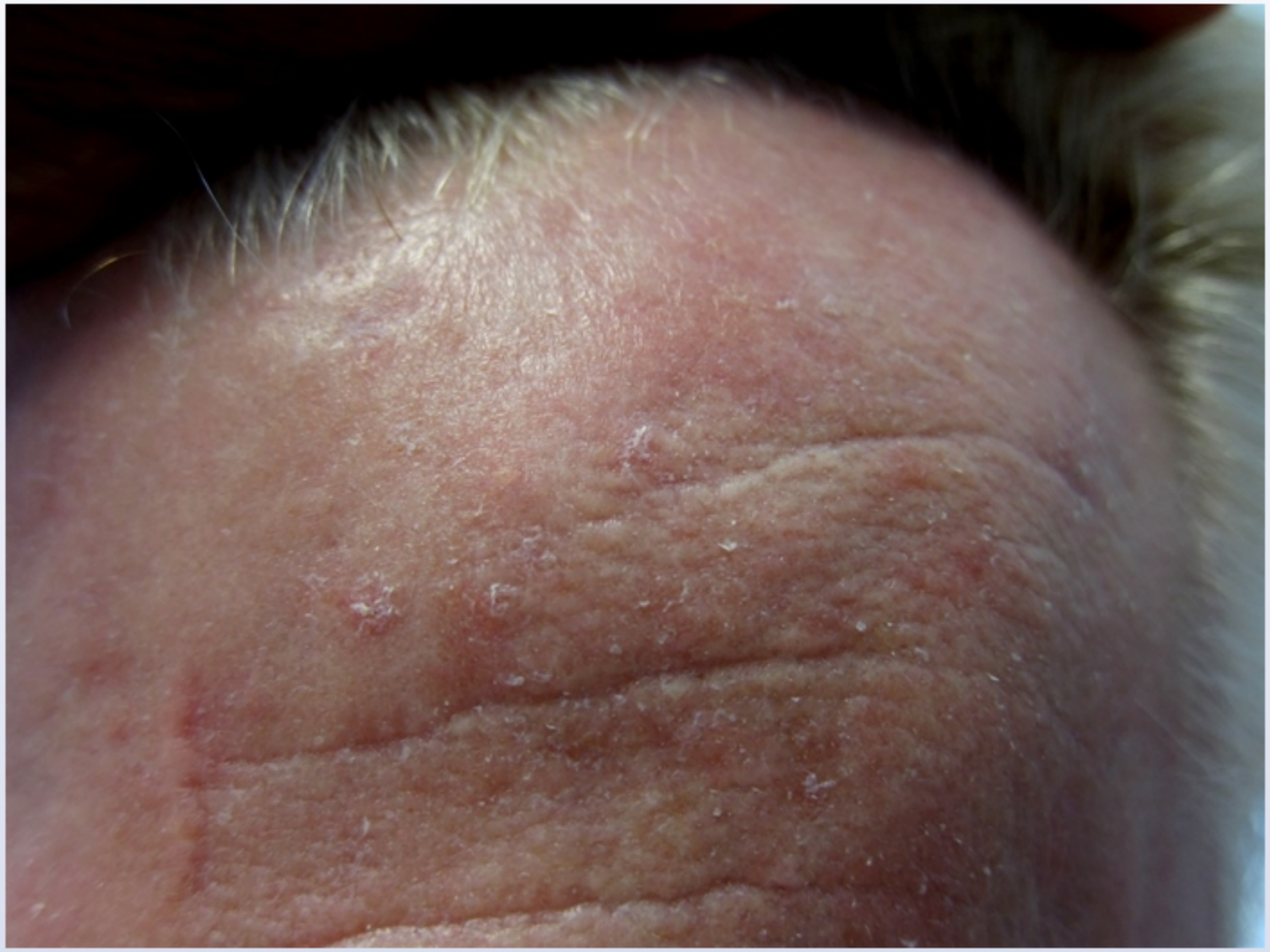

4
5
6
7
8
9
10
11
12
13
14
15
16
17
18
19
20
21
22
23
24
25
26
27
28
29
30
31
32
33

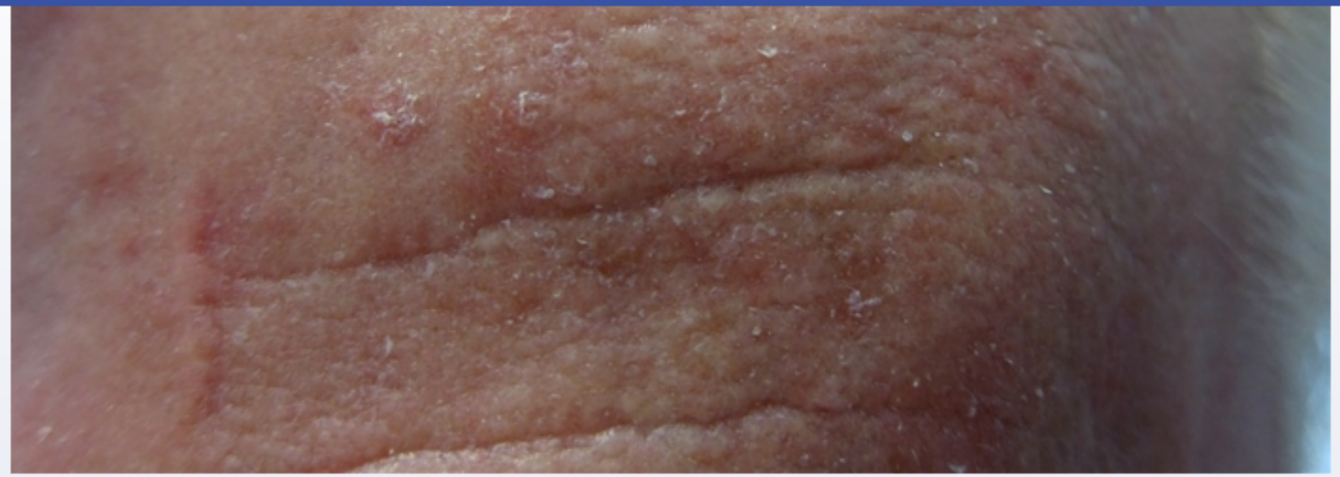

On palpation, the lesions have a rough grainy texture. Biopsy reveals atypical keratinocytes with hyperkeratosis and parakeratosis. This patient's lesions put him at greatest risk for developing which of the following conditions?

- A. Basal cell carcinoma
- B. Dermatofibroma
- C. Kaposi sarcoma
- D. Melanoma
- E. Psoriasis
- F. Squamous cell carcinoma

Submit

4
5
6
7
8
9
10
11
12
13
14
15
16
17
18
19
20
21
22
23
24
25
26
27
28
29
30
31
32
33

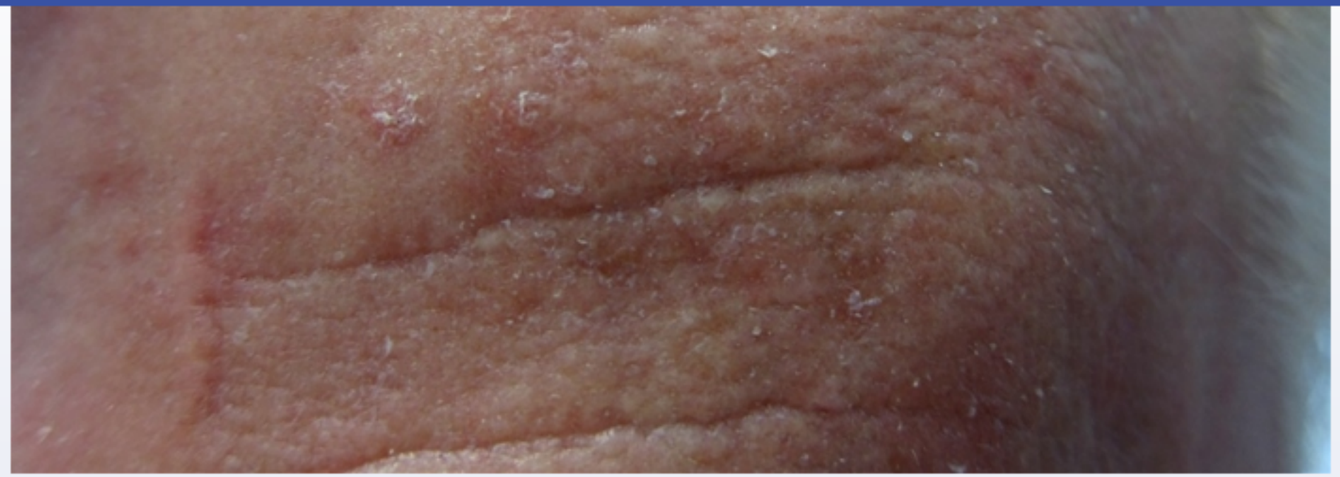

On palpation, the lesions have a rough grainy texture. Biopsy reveals atypical keratinocytes with hyperkeratosis and parakeratosis. This patient's lesions put him at greatest risk for developing which of the following conditions?

- A. Basal cell carcinoma (14%)
- B. Dermatofibroma (0%)
- C. Kaposi sarcoma (0%)
- D. Melanoma (2%)
- E. Psoriasis (6%)
- ✓ F. Squamous cell carcinoma (75%)

Omitted
Correct answer

75%
Answered correctly

04 secs
Time Spent

06/21/2020
Last Updated

4
5
6
7
8
9
10
11
12
13
14
15
16
17
18
19
20
21
22
23
24
25
26
27
28
29
30
31
32
33

Explanation

This patient's forehead lesions are characteristic of **actinic keratoses (AKs)**, which are small, scaly, erythematous lesions with a sandpaper texture occurring on sun-exposed areas. On light microscopy, AKs show **hyperkeratosis** (hyperplasia of the stratum corneum), **parakeratosis** (retention of nuclei in the stratum corneum), and **atypical keratinocytes** with pleomorphic nuclei and multiple mitoses. There may also be pigment irregularities and dilated blood vessels affecting the surrounding skin, which are consistent with chronic sun exposure.

AKs **do not invade the dermis** and are considered to be premalignant lesions. Over several years, a small percentage of AKs transform into **invasive squamous cell carcinoma (SCC)**, a change reflected by an increase in lesion size and thickness, dermal invasion, and metastatic potential.

(Choice A) Basal cell carcinoma (BCC) is the most common skin cancer. It arises on sun-exposed areas and has a very low tendency to metastasize (in contrast to melanoma). BCC often presents as pearly papules with central depression or ulceration. Histologically, BCC features nests of basaloid cells and peripheral palisading of nuclei. It is far more likely for AK to progress to SCC than to BCC.

(Choice B) Dermatofibromas (superficial benign fibrous histiocytomas) result from the benign proliferation of fibroblasts. They commonly arise on the lower extremities as solitary nodules.

(Choice C) Kaposi sarcoma is associated with human herpesvirus-8 (HHV-8) and classically occurs in patients with HIV. Lesions typically appear as palpable macules, plaques, and nodules that are usually a dark brown to violet color.

(Choice D) Melanoma is a cancer arising from the malignant transformation of melanocytes. Lesions have irregular borders and marked color variegation. AK is not a precursor to melanoma.

(Choice E) Psoriasis commonly presents as hyperkeratotic plaques that affect the scalp, knees, and elbows. It is characterized histologically by clubbed rete ridges, hyperkeratosis, neutrophils in the stratum corneum, and perivascular lymphocytic infiltrates.

Educational objective:
Actinic keratoses (AKs) are small (usually <1 cm), erythematous epidermal lesions with adherent scale that are the result of chronic sun exposure. Histologic findings include keratinocyte atypia, hyperkeratosis, and parakeratosis. A small percentage of AKs progress to invasive squamous cell carcinoma; therefore, frequent monitoring is necessary.

Settings

Item 27 of 40
Question Id: 1993

Mark | Previous | Next | Full Screen | Tutorial | Lab Values | Notes | Calculator | Reverse Color | Text Zoom | Settings

Explanation

Exhibit Display

Basal cell carcinoma, ulcerated Basal cell carcinoma, ulcerated

Zoom In | Zoom Out | Reset | Add To New Card | Existing Card

squamous cell carcinoma, therefore, frequent monitoring is necessary.

Block Time Remaining: 00:02:11
TUTOR

11 | Feedback | Suspend | End Block

Settings

4
5
6
7
8
9
10
11
12
13
14
15
16
17
18
19
20
21
22
23
24
25
26
27
28
29
30
31
32
33

Item 27 of 40
Question Id: 1993

Mark | Previous | Next | Full Screen | Tutorial | Lab Values | Notes | Calculator | Reverse Color | Text Zoom | Settings

Explanation

Exhibit Display

Basal cell carcinoma, ulcerated Basal cell carcinoma, ulcerated

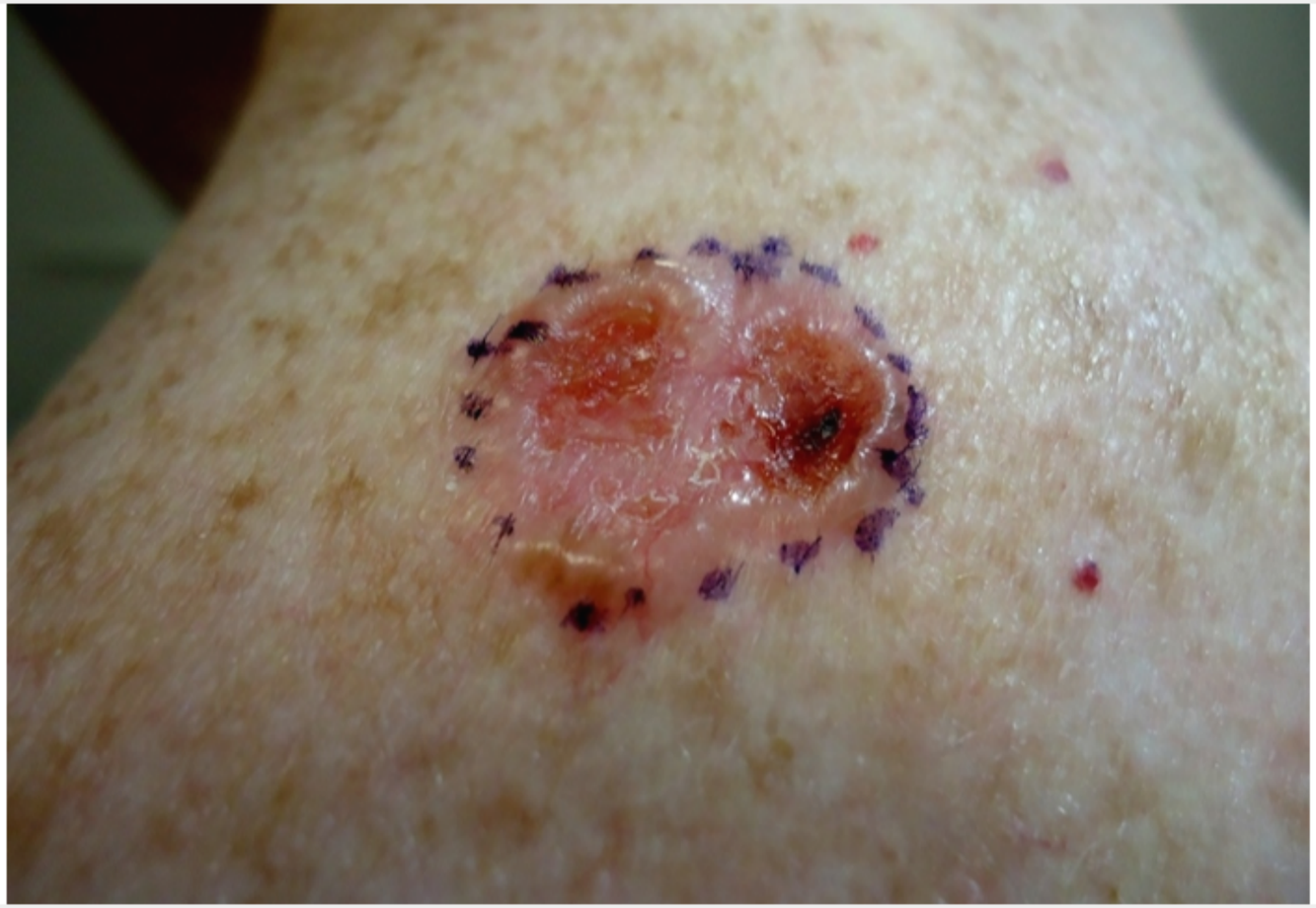

Zoom In | Zoom Out | Reset | Add To New Card | Existing Card

squamous cell carcinoma, therefore, frequent monitoring is necessary.

Block Time Remaining: 00:02:11
TUTOR

11 | Feedback | Suspend | End Block

Settings

Item 27 of 40
Question Id: 1993

Mark | Previous | Next | Full Screen | Tutorial | Lab Values | Notes | Calculator | Reverse Color | Text Zoom | Settings

Explanation

Exhibit Display

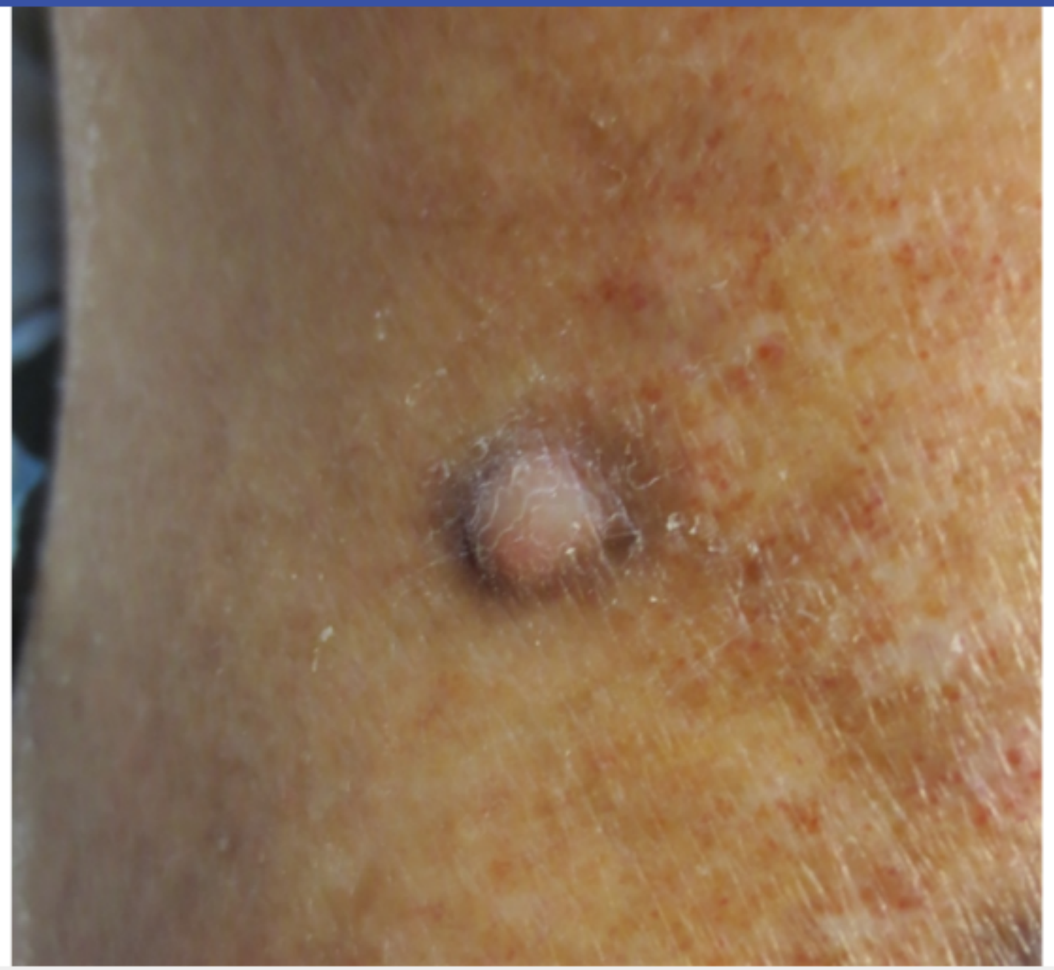

Zoom In | Zoom Out | Reset | Add To New Card | Existing Card

squamous cell carcinoma, therefore, frequent monitoring is necessary.

Block Time Remaining: 00:02:11
TUTOR

11 | Feedback | Suspend | End Block

Settings

Item 27 of 40
Question Id: 1993

Mark | Previous | Next | Full Screen | Tutorial | Lab Values | Notes | Calculator | Reverse Color | Text Zoom | Settings

Explanation

Exhibit Display

Kaposi sarcoma Kaposi sarcoma, HIV/AIDS-associated form

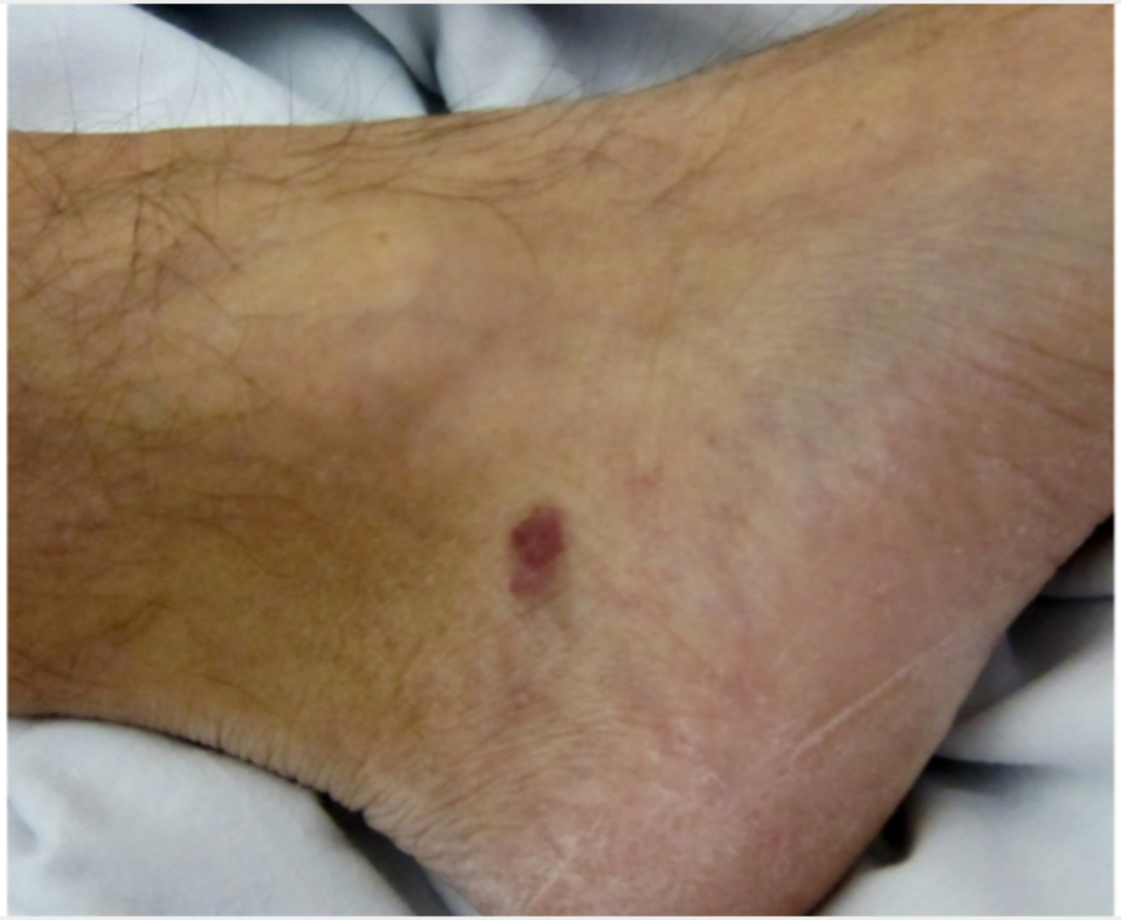

Zoom In | Zoom Out | Reset | Add To New Card | Existing Card

squamous cell carcinoma, therefore, frequent monitoring is necessary.

Block Time Remaining: 00:02:11
TUTOR

11 | Feedback | Suspend | End Block

Settings

4
5
6
7
8
9
10
11
12
13
14
15
16
17
18
19
20
21
22
23
24
25
26
27
28
29
30
31
32
33

Item 27 of 40
Question Id: 1993

Mark | Previous | Next | Full Screen | Tutorial | Lab Values | Notes | Calculator | Reverse Color | Text Zoom | Settings

Explanation

squamous cell carcinoma, therefore, frequent monitoring is necessary.

Exhibit Display

Kaposi sarcoma Kaposi sarcoma, HIV/AIDS-associated form

Zoom In | Zoom Out | Reset | Add To New Card | Existing Card

Block Time Remaining: 00:02:11
TUTOR

11 | Feedback | Suspend | End Block

Settings

Item 27 of 40
Question Id: 1993

Mark | Previous | Next | Full Screen | Tutorial | Lab Values | Notes | Calculator | Reverse Color | Text Zoom | Settings

Explanation

Exhibit Display

Kaposi sarcoma Kaposi sarcoma, HIV/AIDS-associated form

Zoom In | Zoom Out | Reset | Add To New Card | Existing Card

squamous cell carcinoma, therefore, frequent monitoring is necessary.

Block Time Remaining: 00:02:11
TUTOR

11 | Feedback | Suspend | End Block

Settings

Item 27 of 40
Question Id: 1993

Mark | Previous | Next | Full Screen | Tutorial | Lab Values | Notes | Calculator | Reverse Color | Text Zoom | Settings

4 5 6 7 8 9 10 11 12 13 14 15 16 17 18 19 20 21 22 23 24 25 26 27 28 29 30 31 32 33

Exhibit Display

Kaposi sarcoma Kaposi sarcoma, HIV/AIDS-associated form

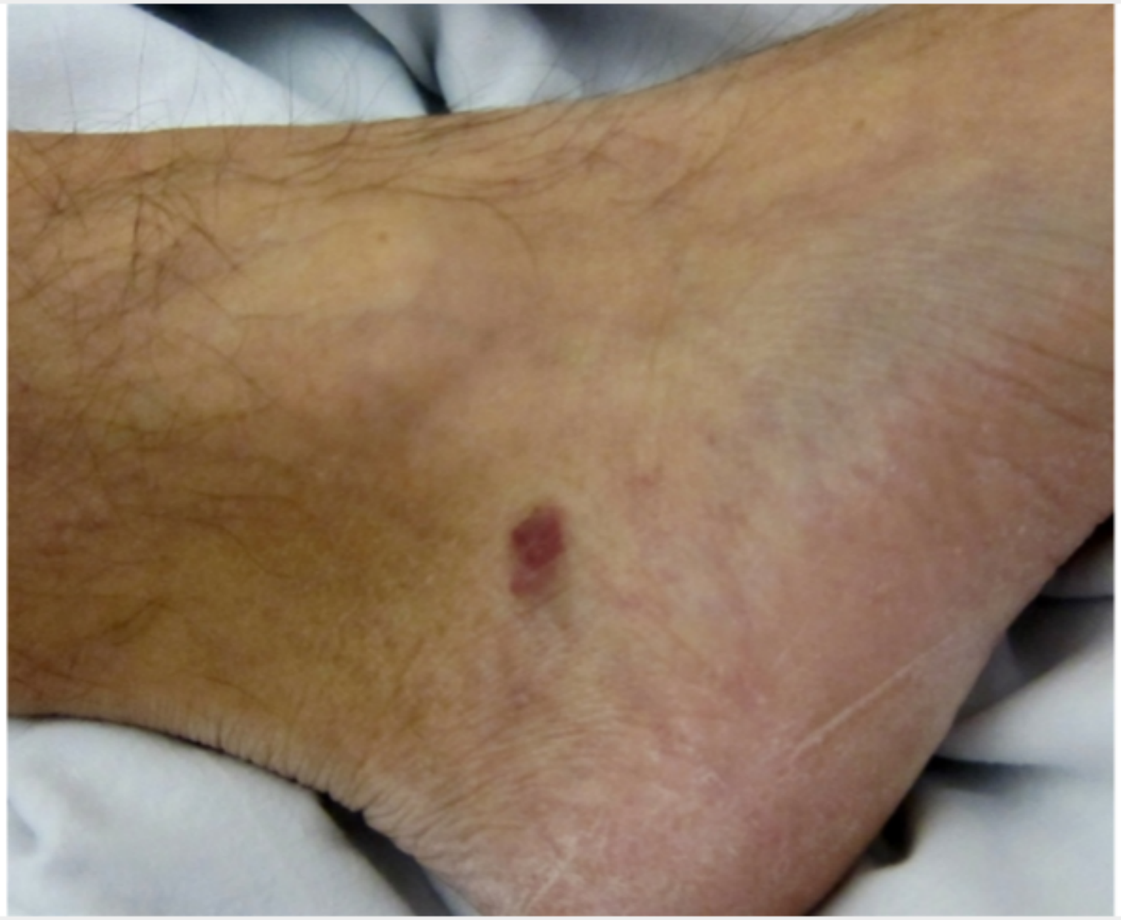

Zoom In | Zoom Out | Reset | Add To New Card | Existing Card

Block Time Remaining: 00:02:11
TUTOR

11 | Feedback | Suspend | End Block

Settings

Item 27 of 40
Question Id: 1993

Mark | Previous | Next | Full Screen | Tutorial | Lab Values | Notes | Calculator | Reverse Color | Text Zoom | Settings

Exhibit Display

Kaposi sarcoma Kaposi sarcoma, HIV/AIDS-associated form

Zoom In | Zoom Out | Reset | Add To New Card | Existing Card

Block Time Remaining: 00:02:11
TUTOR

11 | Feedback | Suspend | End Block

Settings

Item 27 of 40
Question Id: 1993

Mark | Previous | Next | Full Screen | Tutorial | Lab Values | Notes | Calculator | Reverse Color | Text Zoom | Settings

Exhibit Display

Malignant melanoma Melanoma

Zoom In | Zoom Out | Reset | Add To New Card | Existing Card

Block Time Remaining: 00:02:11
TUTOR

11 | Feedback | Suspend | End Block

Settings

Item 27 of 40
Question Id: 1993

Mark | Previous | Next | Full Screen | Tutorial | Lab Values | Notes | Calculator | Reverse Color | Text Zoom | Settings

4 5 6 7 8 9 10 11 12 13 14 15 16 17 18 19 20 21 22 23 24 25 26 27 28 29 30 31 32 33

Exhibit Display

Malignant melanoma Melanoma

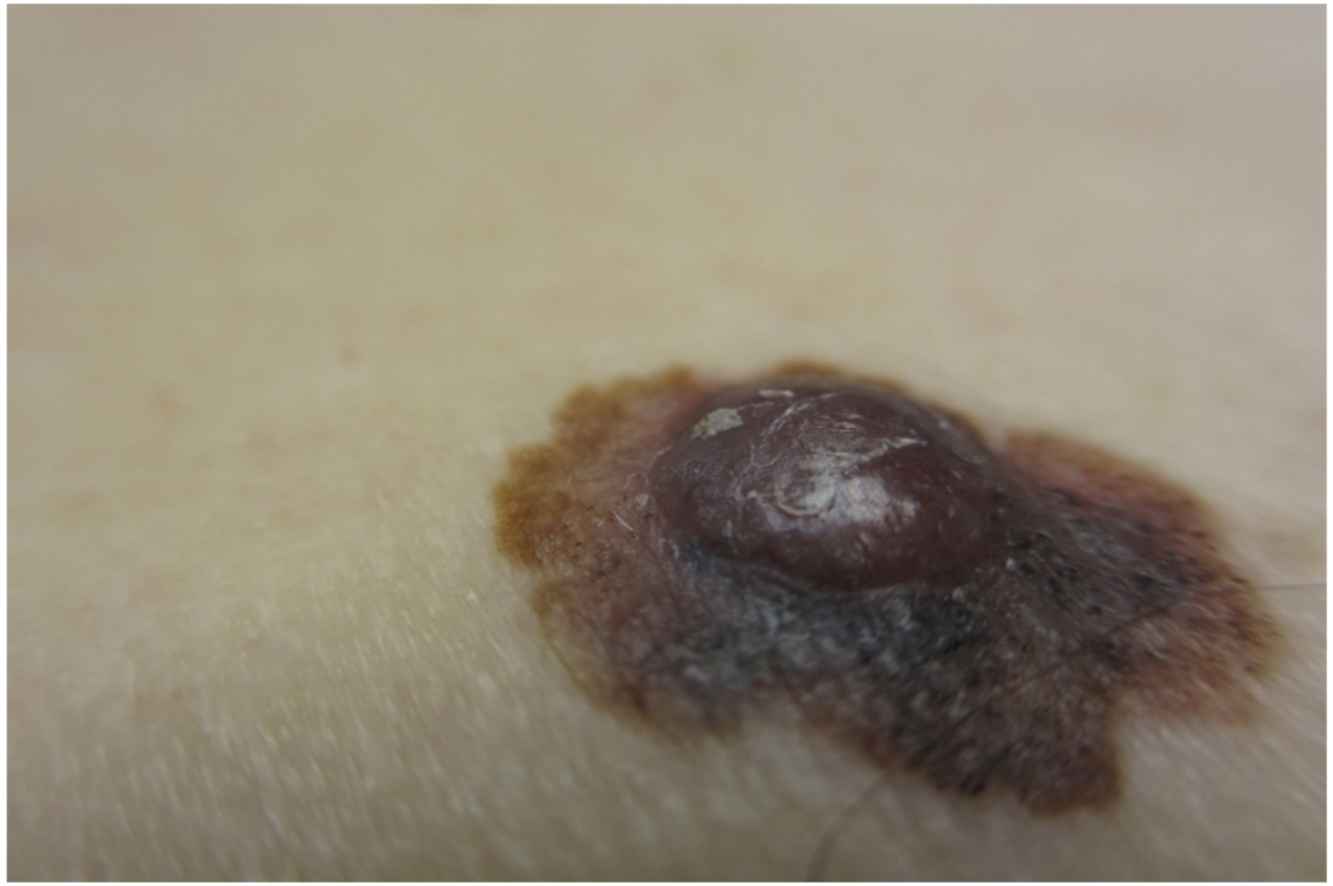

Zoom In | Zoom Out | Reset | Add To New Card | Existing Card

Block Time Remaining: 00:02:11
TUTOR

11 | Feedback | Suspend | End Block

Settings

Item 27 of 40
Question Id: 1993

Mark | Previous | Next | Full Screen | Tutorial | Lab Values | Notes | Calculator | Reverse Color | Text Zoom | Settings

Exhibit Display

Zoom In | Zoom Out | Reset | Add To New Card | Existing Card

Block Time Remaining: 00:02:11
TUTOR

11 | Feedback | Suspend | End Block

4 5 6 7 8 9 10 11 12 13 14 15 16 17 18 19 20 21 22 23 24 25 26 27 28 29 30 31 32 33

A 28-year-old man comes to the office with bilateral skin lesions over the posterior surface of the elbows. The lesions are itchy at times; topical moisturizers have reduced the itching, but the lesions have remained. The patient has no chronic medical problems and takes no medications. Biopsy of the lesions demonstrates hyperkeratosis, parakeratosis, dilated capillaries in the dermal papillae, and foci of neutrophils in the superficial epidermis. Which of the following is the most likely diagnosis?

A. Atopic dermatitis

B. Dermatitis herpetiformis

C. Erythema nodosum

D. Psoriasis

E. Urticaria

Submit

4
5
6
7
8
9
10
11
12
13
14
15
16
17
18
19
20
21
22
23
24
25
26
27
28
29
30
31
32
33

A 28-year-old man comes to the office with bilateral skin lesions over the posterior surface of the elbows. The lesions are itchy at times; topical moisturizers have reduced the itching, but the lesions have remained. The patient has no chronic medical problems and takes no medications. Biopsy of the lesions demonstrates hyperkeratosis, parakeratosis, dilated capillaries in the dermal papillae, and foci of neutrophils in the superficial epidermis. Which of the following is the most likely diagnosis?

- A. Atopic dermatitis (5%)
- B. Dermatitis herpetiformis (7%)
- C. Erythema nodosum (0%)
- ✓ D. Psoriasis (85%)
- E. Urticaria (1%)

Omitted
Correct answer
D

85%
Answered correctly

02 secs
Time Spent

02/26/2020
Last Updated

Explanation

4
5
6
7
8
9
10
11
12
13
14
15
16
17
18
19
20
21
22
23
24
25
26
27
28
29
30
31
32
33

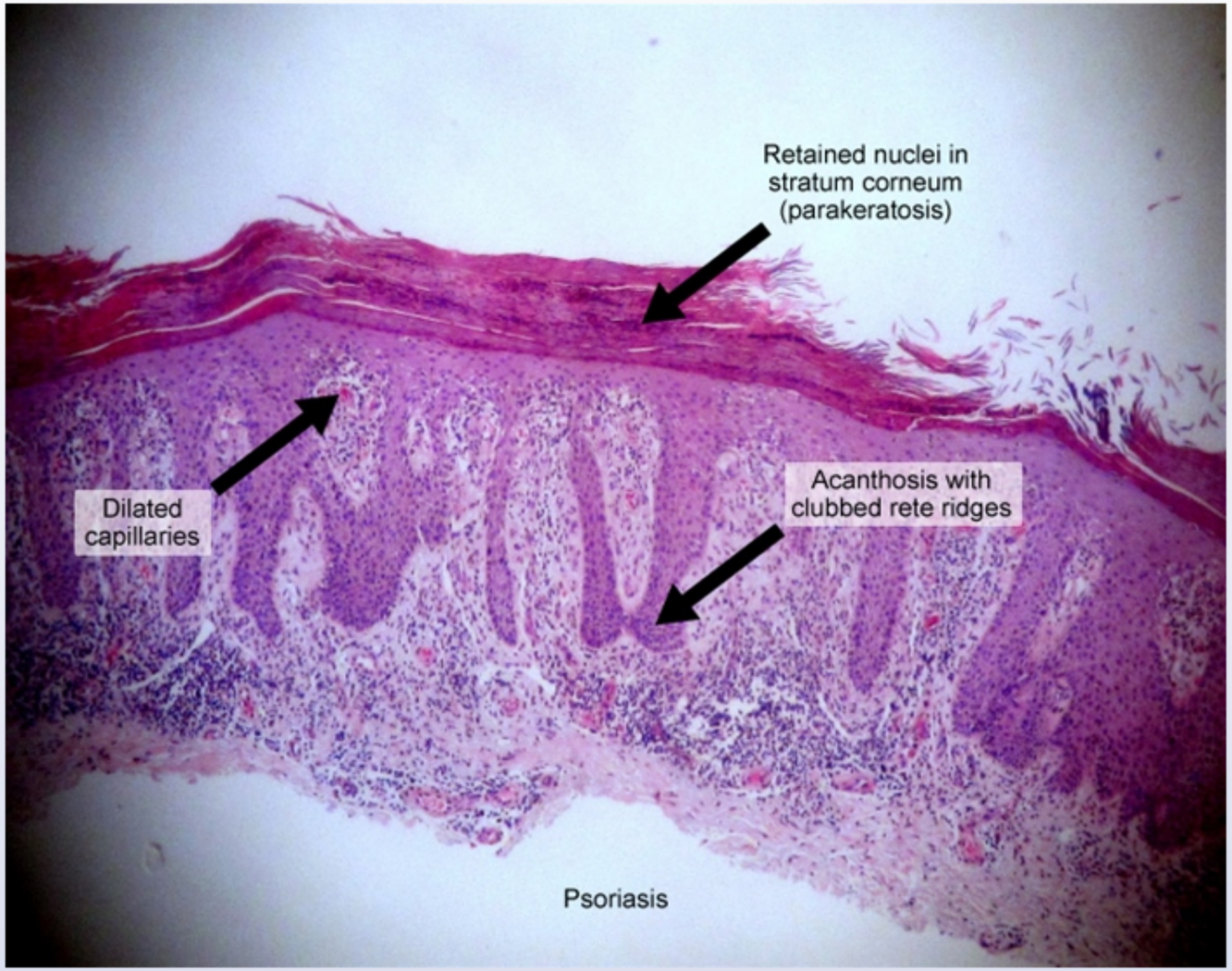

Psoriasis is a common chronic inflammatory skin disorder that presents with scaly, erythematous plaques, typically on the extensor surfaces of the elbows and knees. In predisposed individuals, disruption of the epithelial barrier leads to activation of antigen-presenting dendritic cells and

4
5
6
7
8
9
10
11
12
13
14
15
16
17
18
19
20
21
22
23
24
25
26
27
28
29
30
31
32
33

the elbows and knees. In predisposed individuals, disruption of the epithelial barrier leads to activation of antigen-presenting dendritic cells and subsequently to a self-reinforcing inflammatory cascade characterized by recruitment and activation of T helper cells and **proliferation of keratinocytes**.

Histopathologically, psoriasis is characterized by:

- **Hyperkeratosis** (thickening of the stratum corneum) and confluent parakeratosis (retention of nuclei in the stratum corneum) produces the characteristic silvery scale on gross examination
- **Epidermal hyperplasia** (acanthosis) with elongated rete ridges correspond to the typical erythematous plaques
- **Neutrophilic foci** in the stratum corneum and epidermis, which may coalesce to form microabscesses (Munro microabscesses)

In addition, the epidermal cell layer superficial to the dermal papillae may be thinned and contain **dilated blood vessels**, which leads to **pinpoint bleeding** when the scale is removed from the plaque (Auspitz sign).

(Choice A) Chronic atopic dermatitis can produce plaques characterized by hyperkeratosis and acanthosis, often with a lymphocytic or eosinophilic infiltrate. However, adults most commonly develop lesions on flexural surfaces (eg, anterior elbows), and most patients have a history of other atopic disorders (eg, asthma, allergic rhinitis) beginning in childhood.

(Choice B) Dermatitis herpetiformis presents with erythematous, pruritic papules, vesicles, and bullae symmetrically on the elbows, knees, upper back, and buttocks. It is strongly associated with celiac disease, and histopathology shows microabscesses at the dermal papillary tips, which coalesce to form subepidermal blisters.

(Choice C) Erythema nodosum is characterized by painful, red nodules on the shins and often represents an inflammatory response to medications (eg, oral contraceptives), infections, inflammatory bowel disease, or sarcoidosis. Histopathology is variable but typically shows a septal panniculitis with a mixed cellular infiltrate.

(Choice E) Urticaria ("hives") is a transient dermatologic disorder that is caused by antigen-induced degranulation of focal mast cells through IgE antibody sensitization. This degranulation causes microvasculature hyperpermeability and the formation of wheals that typically surface and resolve within hours.

Educational objective:

- **Epidermal hyperplasia** (acanthosis) with elongated rete ridges correspond to the typical erythematous plaques
- **Neutrophilic foci** in the stratum corneum and epidermis, which may coalesce to form microabscesses (Munro microabscesses)

In addition, the epidermal cell layer superficial to the dermal papillae may be thinned and contain **dilated blood vessels**, which leads to **pinpoint bleeding** when the scale is removed from the plaque (Auspitz sign).

(Choice A) Chronic atopic dermatitis can produce plaques characterized by hyperkeratosis and acanthosis, often with a lymphocytic or eosinophilic infiltrate. However, adults most commonly develop lesions on flexural surfaces (eg, anterior elbows), and most patients have a history of other atopic disorders (eg, asthma, allergic rhinitis) beginning in childhood.

(Choice B) Dermatitis herpetiformis presents with erythematous, pruritic papules, vesicles, and bullae symmetrically on the elbows, knees, upper back, and buttocks. It is strongly associated with celiac disease, and histopathology shows microabscesses at the dermal papillary tips, which coalesce to form subepidermal blisters.

(Choice C) Erythema nodosum is characterized by painful, red nodules on the shins and often represents an inflammatory response to medications (eg, oral contraceptives), infections, inflammatory bowel disease, or sarcoidosis. Histopathology is variable but typically shows a septal panniculitis with a mixed cellular infiltrate.

(Choice E) Urticaria ("hives") is a transient dermatologic disorder that is caused by antigen-induced degranulation of focal mast cells through IgE antibody sensitization. This degranulation causes microvasculature hyperpermeability and the formation of wheals that typically surface and resolve within hours.

Educational objective:
Psoriasis is characterized by hyperkeratosis and confluent parakeratosis of the stratum corneum, and epidermal hyperplasia (acanthosis) with elongated rete ridges. Neutrophilic foci in the stratum corneum and epidermis may coalesce to form microabscesses (Munro microabscesses).

Pathology	Dermatology	Psoriasis
Subject	System	Topic

Copyright © UWorld. All rights reserved.

4
5
6
7
8
9
10
11
12
13
14
15
16
17
18
19
20
21
22
23
24
25
26
27
28
29
30
31
32
33

A 46-year-old man comes to the office with the skin lesions shown in the photograph below. The patient first noticed the lesions a week ago after he returned from a trip to Hawaii. He has not had any other significant rashes or skin lesions but does have a history of autoimmune thyroiditis.

Which of the following would most likely be seen on histopathologic examination of this patient's lesions?

- A. Absence of melanocytes in the epidermis
- B. Linear pattern of melanocyte proliferation

4
5
6
7
8
9
10
11
12
13
14
15
16
17
18
19
20
21
22
23
24
25
26
27
28
29
30
31
32
33

Which of the following would most likely be seen on histopathologic examination of this patient's lesions?

A. Absence of melanocytes in the epidermis

B. Linear pattern of melanocyte proliferation

C. Melanosome aggregates within the cytoplasm of melanocytes

D. Normal melanocytes with diminished pigment transfer to keratinocytes

E. Poor melanin formation in melanocytes

Submit

4
5
6
7
8
9
10
11
12
13
14
15
16
17
18
19
20
21
22
23
24
25
26
27
28
29
30
31
32
33

Which of the following would most likely be seen on histopathologic examination of this patient's lesions?

- A. Absence of melanocytes in the epidermis (54%)
- B. Linear pattern of melanocyte proliferation (0%)
- C. Melanosome aggregates within the cytoplasm of melanocytes (4%)
- D. Normal melanocytes with diminished pigment transfer to keratinocytes (24%)
- E. Poor melanin formation in melanocytes (16%)

Omitted
Correct answer

54%
Answered correctly

05 secs
Time Spent

04/16/2020
Last Updated

4
5
6
7
8
9
10
11
12
13
14
15
16
17
18
19
20
21
22
23
24
25
26
27
28
29
30
31
32
33

Vitiligo

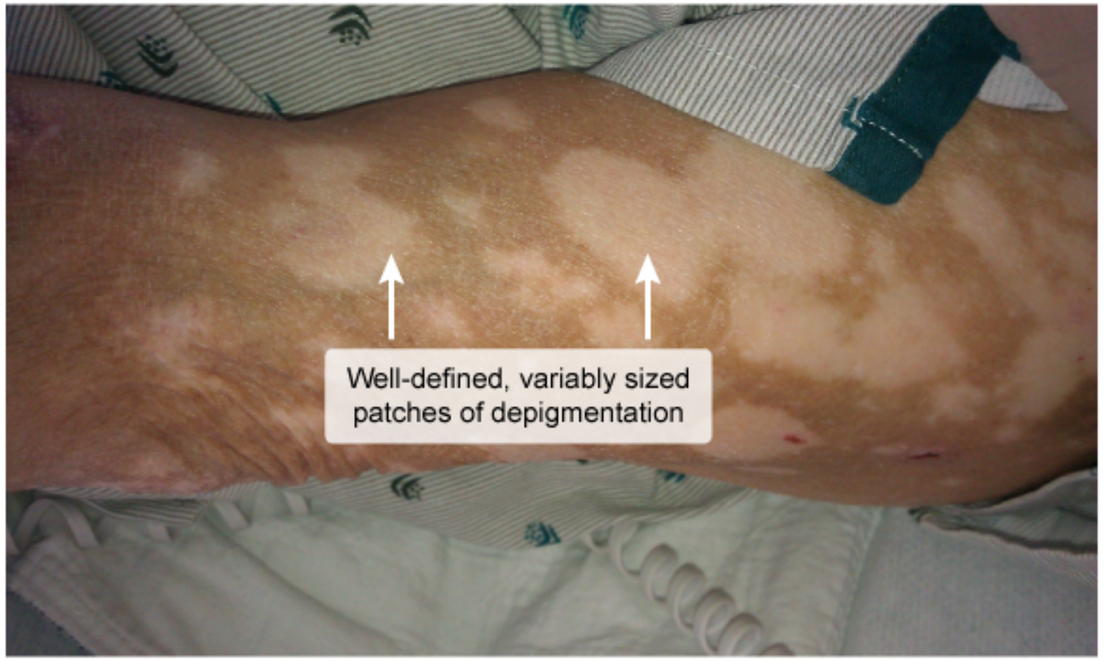

©UWorld

This patient has **vitiligo,** which is characterized by flat, well-circumscribed patches of **depigmentation** of variable size due to the partial or complete loss of melanocytes. These lesions often manifest by the second or third decade of life and can be more obvious in individuals with darkly pigmented skin. Vitiligo classically erupts on the face, extremities, axillae, groin, and over hard bony surfaces (eg, knees). Histologic examination of the affected epidermis would demonstrate the **absence of melanocytes** and melanin pigment.

The pathogenesis of melanocyte loss in vitiligo is likely a combination of **autoimmune activity**, neurohumoral toxicity specific for melanocytes, and melanocytic self-destruction (eg, toxic intermediate exposure during melanin synthesis). Autoimmune activity seems to have the strongest correlation with vitiligo due to the presence of circulating melanocyte antibodies in patients and the high prevalence of concurrent autoimmune disorders (e.g., type I diabetes mellitus, pernicious anemia, Addison disease, autoimmune thyroiditis).

4
5
6
7
8
9
10
11
12
13
14
15
16
17
18
19
20
21
22
23
24
25
26
27
28
29
30
31
32
33



©UWorld

This patient has **vitiligo,** which is characterized by flat, well-circumscribed patches of **depigmentation** of variable size due to the partial or complete loss of melanocytes. These lesions often manifest by the second or third decade of life and can be more obvious in individuals with darkly pigmented skin. Vitiligo classically erupts on the face, extremities, axillae, groin, and over hard bony surfaces (eg, knees). Histologic examination of the affected epidermis would demonstrate the **absence of melanocytes** and melanin pigment.

The pathogenesis of melanocyte loss in vitiligo is likely a combination of **autoimmune activity**, neurohumoral toxicity specific for melanocytes, and melanocytic self-destruction (eg, toxic intermediate exposure during melanin synthesis). Autoimmune activity seems to have the strongest correlation with vitiligo due to the presence of circulating melanocyte antibodies in patients and the high prevalence of concurrent autoimmune disorders (e.g., type I diabetes mellitus, pernicious anemia, Addison disease, autoimmune thyroiditis).

(Choice B) Lentigines are small, benign pigmented lesions characterized by linear melanocytic hyperplasia.

(Choice C) Café-au-lait spots demonstrate increased melanosome aggregates within the melanocyte cytoplasm. These macules are hyperpigmented and associated with neurofibromatosis type 1.

(Choice D) Postinflammatory hypopigmentation can occur after significant inflammatory skin lesions (eg, discoid lupus, psoriasis) and is characterized by redistribution of existing melanin within the skin and/or reduced transfer of melanin to keratinocytes.

(Choice E) Individuals with albinism have melanocytes that do not produce melanin because of absent or defective tyrosinase.

Educational objective:
Vitiligo is a common condition characterized by the loss of epidermal melanocytes. It occurs more commonly in patients with autoimmune disorders (eg, autoimmune thyroiditis, type I diabetes) and results in well-defined, variably sized patches of hypopigmentation.

Pathology	Dermatology	Vitiligo
Subject	System	Topic

Copyright © UWorld. All rights reserved.

4 5 6 7 8 9 10 11 12 13 14 15 16 17 18 19 20 21 22 23 24 25 26 27 28 29 30 31 32 33

A 2-year-old boy is brought to the office by his mother due to a rash that started 3 days ago. A similar red, itchy rash on the cheeks, trunk, and arms has occurred intermittently since infancy. The mother thought that the rashes were related to the consumption of certain foods, but elimination of cow's milk and fruits did not improve the rash. The patient has had a few upper respiratory infections but no major illnesses. Vaccinations are up to date, and he takes no medications. He attends a day care facility. Vital signs are within normal limits. The rash on the patient's back is shown in the exhibit. Similar findings are observed on the cheeks and proximal upper extremities. The diaper area is clear, and no mucosal lesions are present. This patient's condition is often associated with the development of which of the following disorders?

A. Celiac disease

B. Extrinsic asthma

C. Langerhans cell histiocytosis

D. Psoriatic arthritis

E. Ulcerative colitis

Submit

Settings

4
5
6
7
8
9
10
11
12
13
14
15
16
17
18
19
20
21
22
23
24
25
26
27
28
29
30
31
32
33

Item 30 of 40
Question Id: 876

Mark | Previous | Next | Full Screen | Tutorial | Lab Values | Notes | Calculator | Reverse Color | Text Zoom | Settings

Exhibit Display

Zoom In | Zoom Out | Reset | Add To New Card | Existing Card

Block Time Remaining: 00:02:22
TUTOR

7 | Feedback | Suspend | End Block

4
5
6
7
8
9
10
11
12
13
14
15
16
17
18
19
20
21
22
23
24
25
26
27
28
29
30
31
32
33

A 2-year-old boy is brought to the office by his mother due to a rash that started 3 days ago. A similar red, itchy rash on the cheeks, trunk, and arms has occurred intermittently since infancy. The mother thought that the rashes were related to the consumption of certain foods, but elimination of cow's milk and fruits did not improve the rash. The patient has had a few upper respiratory infections but no major illnesses. Vaccinations are up to date, and he takes no medications. He attends a day care facility. Vital signs are within normal limits. The rash on the patient's back is shown in the exhibit. Similar findings are observed on the cheeks and proximal upper extremities. The diaper area is clear, and no mucosal lesions are present. This patient's condition is often associated with the development of which of the following disorders?

A. Celiac disease (23%)
✓ B. Extrinsic asthma (54%)
C. Langerhans cell histiocytosis (12%)
D. Psoriatic arthritis (8%)
E. Ulcerative colitis (1%)

Omitted
Correct answer
B

54%
Answered correctly

07 secs
Time Spent

01/31/2020
Last Updated

Explanation

Atopic dermatitis	
	• Mutations of filaggrin and other epidermal barrier proteins

Atopic dermatitis	
Pathogenesis	• Mutations of filaggrin and other epidermal barrier proteins • Disrupted skin barrier increases antigen exposure and hypersensitivity • Associated with asthma & allergic rhinitis
Clinical findings	• Intense pruritus • Infants: red, crusted lesions involving extensor surfaces & face • Children & adults: flexural eczema & lichenification
Laboratory findings	• High serum IgE • Eosinophilia

Atopic dermatitis (AD), or eczema, is a **chronic** inflammatory skin disorder common in children. The disease typically occurs at age <5, with many patients developing symptoms in infancy. AD typically presents in infants and young children as erythematous papules and plaques involving the face, scalp, trunk, and extensor surfaces. The diaper area is usually spared. In older children and adults, it often manifests as lichenification in a flexural distribution (eg, neck, wrists, antecubital and popliteal fossae). Eczema has a chronic course marked by exacerbations and remissions, and its severity tends to lessen with age. Intense **pruritus** is a hallmark of AD.

AD can be associated with mutations affecting epidermal barrier proteins such as filaggrin, resulting in **impairment of the skin's barrier function**. This increases immunologic exposure to environmental allergens and microbial antigens, leading to immune hypersensitivity. Affected patients usually have high serum IgE levels and peripheral eosinophilia. Children with AD often have a **family history** of atopy and are at risk of developing other atopic diseases, such as **allergic rhinitis** and **asthma** (**allergic triad**). The risk of developing an additional atopic disease may be inversely related to the age of eczema onset.

(Choice A) Celiac disease is associated with dermatitis herpetiformis, which presents with pruritic vesicles and plaques on the buttocks and extensor surfaces of the extremities. In addition, this skin disorder is extremely uncommon in children.

(Choice C) Langerhans cell histiocytosis is a dendritic cell disorder that can present in infancy or early childhood with a severe, refractory,

4
5
6
7
8
9
10
11
12
13
14
15
16
17
18
19
20
21
22
23
24
25
26
27
28
29
30
31
32
33

Atopic dermatitis (AD), or eczema, is a **chronic** inflammatory skin disorder common in children. The disease typically occurs at age <5, with many patients developing symptoms in infancy. AD typically presents in infants and young children as erythematous papules and plaques involving the face, scalp, trunk, and extensor surfaces. The diaper area is usually spared. In older children and adults, it often manifests as lichenification in a flexural distribution (eg, neck, wrists, antecubital and popliteal fossae). Eczema has a chronic course marked by exacerbations and remissions, and its severity tends to lessen with age. Intense **pruritus** is a hallmark of AD.

AD can be associated with mutations affecting epidermal barrier proteins such as filaggrin, resulting in **impairment of the skin's barrier function**. This increases immunologic exposure to environmental allergens and microbial antigens, leading to immune hypersensitivity. Affected patients usually have high serum IgE levels and peripheral eosinophilia. Children with AD often have a **family history** of atopy and are at risk of developing other atopic diseases, such as **allergic rhinitis** and **asthma** (**allergic triad**). The risk of developing an additional atopic disease may be inversely related to the age of eczema onset.

(Choice A) Celiac disease is associated with dermatitis herpetiformis, which presents with pruritic vesicles and plaques on the buttocks and extensor surfaces of the extremities. In addition, this skin disorder is extremely uncommon in children.

(Choice C) Langerhans cell histiocytosis is a dendritic cell disorder that can present in infancy or early childhood with a severe, refractory, erythematous or ulcerative rash on the scalp, trunk, or groin. This patient's rash flares and resolves without intervention.

(Choice D) Psoriatic arthritis is associated with psoriasis. Manifestations of psoriasis include erythematous, well-demarcated papules and plaques with a silvery scale, which are not seen in this patient.

(Choice E) Ulcerative colitis, a type of inflammatory bowel disease, can be associated with dermatologic manifestations, such as pyoderma gangrenosum (ulcerative rash) or erythema nodosum (painful raised red nodules). Both are uncommon in children, and neither is seen in this case.

Educational objective:
Atopic dermatitis (eczema) is a common, chronic inflammatory disorder caused by impairment of the skin's barrier function. Eczema presents with pruritus and erythematous papules and plaques and is associated with other atopic diseases, such as allergic rhinitis and asthma.

References

4
5
6
7
8
9
10
11
12
13
14
15
16
17
18
19
20
21
22
23
24
25
26
27
28
29
30
31
32
33

Exhibit Display

Atopic dermatitis distribution by age

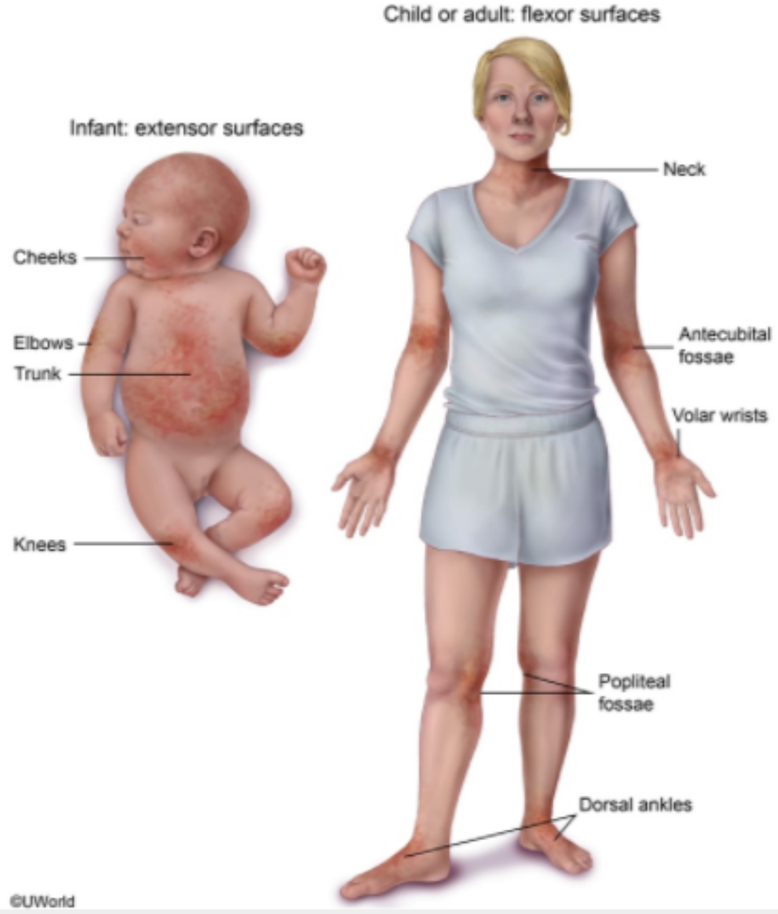

Zoom In | Zoom Out | Reset | Add To New Card | Existing Card

Settings

Item 30 of 40
Question Id: 876

Mark | Previous | Next | Full Screen | Tutorial | Lab Values | Notes | Calculator | Reverse Color | Text Zoom | Settings

Exhibit Display

Zoom In | Zoom Out | Reset | Add To New Card | Existing Card

Block Time Remaining: 00:02:25
TUTOR

7 | Feedback | Suspend | End Block

Settings

Item 30 of 40
Question Id: 876

Mark | Previous | Next | Full Screen | Tutorial | Lab Values | Notes | Calculator | Reverse Color | Text Zoom | Settings

Exhibit Display

Zoom In | Zoom Out | Reset | Add To New Card | Existing Card

Block Time Remaining: 00:02:25
TUTOR

7 | Feedback | Suspend | End Block

Settings

4
5
6
7
8
9
10
11
12
13
14
15
16
17
18
19
20
21
22
23
24
25
26
27
28
29
30
31
32
33

Item 30 of 40
Question Id: 876

Mark | Previous | Next | Full Screen | Tutorial | Lab Values | Notes | Calculator | Reverse Color | Text Zoom | Settings

Exhibit Display

Zoom In | Zoom Out | Reset | Add To New Card | Existing Card

Block Time Remaining: 00:02:25
TUTOR

7 | Feedback | Suspend | End Block

Settings

Item 30 of 40
Question Id: 876

Mark | Previous | Next | Full Screen | Tutorial | Lab Values | Notes | Calculator | Reverse Color | Text Zoom | Settings

Exhibit Display

Zoom In | Zoom Out | Reset | Add To New Card | Existing Card

Block Time Remaining: 00:02:25
TUTOR

Feedback | Suspend | End Block

Settings

4
5
6
7
8
9
10
11
12
13
14
15
16
17
18
19
20
21
22
23
24
25
26
27
28
29
30
31
32
33

Item 30 of 40
Question Id: 876

Mark | Previous | Next | Full Screen | Tutorial | Lab Values | Notes | Calculator | Reverse Color | Text Zoom | Settings

Exhibit Display

Zoom In | Zoom Out | Reset | Add To New Card | Existing Card

Block Time Remaining: 00:02:25
TUTOR

7 | Feedback | Suspend | End Block

Settings

Item 30 of 40
Question Id: 876

Mark | Previous | Next | Full Screen | Tutorial | Lab Values | Notes | Calculator | Reverse Color | Text Zoom | Settings

Exhibit Display

Erythema nodosum

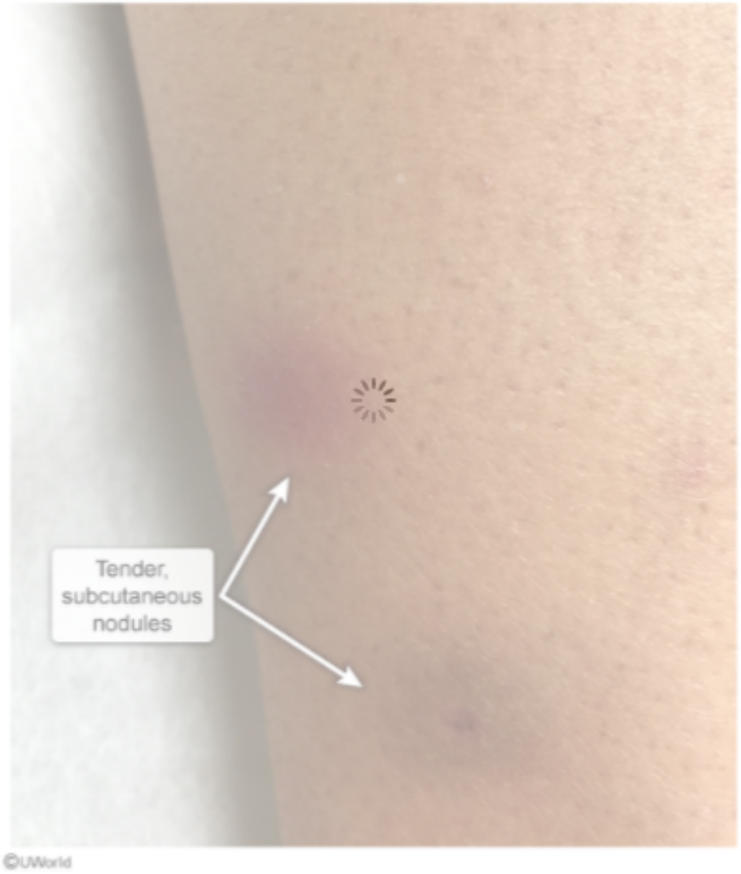

Zoom In | Zoom Out | Reset | Add To New Card | Existing Card

Block Time Remaining: 00:02:25
TUTOR

7 | Feedback | Suspend | End Block

4
5
6
7
8
9
10
11
12
13
14
15
16
17
18
19
20
21
22
23
24
25
26
27
28
29
30
31
32
33

A 27-year-old woman comes to the emergency department with a 1-day history of skin rash. Two weeks ago, she had an episode of recurrent genital lesions, which began with small papules and subsequently became vesicular with ulceration, crusting, and eventual healing. The patient has no other medical conditions and takes no medications. On physical examination, she appears comfortable. Temperature is 37 C (98.6 F). She has small linear erosions in the oral mucosa. Skin findings are shown in the image below.

Settings

4
5
6
7
8
9
10
11
12
13
14
15
16
17
18
19
20
21
22
23
24
25
26
27
28
29
30
31
32
33

Item 31 of 40
Question Id: 11662

Mark | Previous | Next | Full Screen | Tutorial | Lab Values | Notes | Calculator | Reverse Color | Text Zoom | Settings

Block Time Remaining: 00:02:28
TUTOR

4 | Feedback | Suspend | End Block

4
5
6
7
8
9
10
11
12
13
14
15
16
17
18
19
20
21
22
23
24
25
26
27
28
29
30
31
32
33

Which of the following is the most likely diagnosis?

A. Disseminated herpes simplex infection

B. Erythema multiforme

C. Primary HIV infection

D. Stevens-Johnson syndrome

E. Varicella

Submit

4
5
6
7
8
9
10
11
12
13
14
15
16
17
18
19
20
21
22
23
24
25
26
27
28
29
30
31
32
33

Which of the following is the most likely diagnosis?

- A. Disseminated herpes simplex infection (32%)
- ✓ B. Erythema multiforme (58%)
- C. Primary HIV infection (2%)
- D. Stevens-Johnson syndrome (5%)
- E. Varicella (1%)

Omitted
Correct answer

58%
Answered correctly

07 secs
Time Spent

01/22/2020
Last Updated

Explanation

This patient's rash is consistent with **erythema multiforme** (EM), an acute inflammatory disorder that can involve the skin of the extremities, face, trunk, and neck. Severe cases (EM major) can also affect oral mucous membranes and the tongue. The appearance of EM can vary, but patients typically develop erythematous, round papules that evolve into **target lesions** with a dusky central area, a dark red inflammatory zone surrounded by a pale ring, and an erythematous halo in the lesion's periphery.

EM represents a cell-mediated immune process, with an inflammatory infiltrate predominated by cytotoxic $CD8^+$ lymphocytes. EM is most frequently associated with infections (especially **herpes simplex virus** and mycoplasma) and may be due to an immune response against antigens deposited in the skin. EM can also be seen in association with certain medications (eg, sulfonamides), malignancy, and collagen vascular diseases.

(Choice A) Disseminated herpes simplex infection is seen primarily in immunocompromised patients and presents with diffuse vesicles on an erythematous base. EM does not represent disseminated infection, but is a systemic immune response to a localized infection.

(Choice C) Primary HIV infection can present with a macular or maculopapular rash associated with fever. The rash is usually well circumscribed and involves the trunk, face, and palms and soles. However, this patient's rash appears more typical of EM.

(Choice D) Stevens-Johnson syndrome is characterized by rapid onset of erythematous macules with necrosis and skin sloughing. Systemic signs (eg, fever, hypotension) are common. Stevens-Johnson syndrome may also cause target lesions, but it is usually associated with medications (eg, sulfonamides, allopurinol, phenytoin).

(Choice E) Varicella typically presents with fever and a vesicular eruption that can affect multiple areas, including the face, trunk, abdomen, and extremities. This patient's rash does not have the typical vesicular pattern seen in varicella.

Educational objective:
Erythema multiforme is a cell-mediated inflammatory disorder of the skin characterized by erythematous papules that evolve into target lesions. It is most commonly associated with herpes simplex virus.

References

- Erythema multiforme: a review of epidemiology, pathogenesis, clinical features, and treatment.

4
5
6
7
8
9
10
11
12
13
14
15
16
17
18
19
20
21
22
23
24
25
26
27
28
29
30
31
32
33

EM represents a cell-mediated immune process, with an inflammatory infiltrate predominated by cytotoxic CD8+ lymphocytes. EM is most frequently associated with infections (especially **herpes simplex virus** and mycoplasma) and may be due to an immune response against antigens deposited in the skin. EM can also be seen in association with certain medications (eg, sulfonamides), malignancy, and collagen vascular diseases.

(Choice A) Disseminated herpes simplex infection is seen primarily in immunocompromised patients and presents with diffuse vesicles on an erythematous base. EM does not represent disseminated infection, but is a systemic immune response to a localized infection.

(Choice C) Primary HIV infection can present with a macular or maculopapular rash associated with fever. The rash is usually well circumscribed and involves the trunk, face, and palms and soles. However, this patient's rash appears more typical of EM.

(Choice D) Stevens-Johnson syndrome is characterized by rapid onset of erythematous macules with necrosis and skin sloughing. Systemic signs (eg, fever, hypotension) are common. Stevens-Johnson syndrome may also cause target lesions, but it is usually associated with medications (eg, sulfonamides, allopurinol, phenytoin).

(Choice E) Varicella typically presents with fever and a vesicular eruption that can affect multiple areas, including the face, trunk, abdomen, and extremities. This patient's rash does not have the typical vesicular pattern seen in varicella.

Educational objective:
Erythema multiforme is a cell-mediated inflammatory disorder of the skin characterized by erythematous papules that evolve into target lesions. It is most commonly associated with herpes simplex virus.

References

- Erythema multiforme: a review of epidemiology, pathogenesis, clinical features, and treatment.
- Clinical features, diagnosis, and treatment of erythema multiforme: a review for the practicing dermatologist.

Pathology	Dermatology	Erythema multiforme
Subject	System	Topic

Copyright © UWorld. All rights reserved.

Settings

Item 31 of 40
Question Id: 11662

Mark | Previous | Next | Full Screen | Tutorial | Lab Values | Notes | Calculator | Reverse Color | Text Zoom | Settings

EM represents a cell-mediated immune process, with an inflammatory infiltrate predominated by cytotoxic CD8+ lymphocytes. EM is most frequently associated with infections (especially **herpes simplex virus** and mycoplasma) and may be due to an immune response against

Exhibit Display

Zoom In | Zoom Out | Reset | Add To New Card | Existing Card

Block Time Remaining: 00:02:32
TUTOR

4 | Feedback | Suspend | End Block

4 5 6 7 8 9 10 11 12 13 14 15 16 17 18 19 20 21 22 23 24 25 26 27 28 29 30 31 32 33

Settings

Item 31 of 40
Question Id: 11662

Mark | Previous | Next | Full Screen | Tutorial | Lab Values | Notes | Calculator | Reverse Color | Text Zoom | Settings

Exhibit Display

Zoom In | Zoom Out | Reset | Add To New Card | Existing Card

Block Time Remaining: 00:02:32
TUTOR

Feedback | Suspend | End Block

4
5
6
7
8
9
10
11
12
13
14
15
16
17
18
19
20
21
22
23
24
25
26
27
28
29
30
31
32
33

An 8-year-old boy is brought to the office due to a lower extremity skin rash for the past 3 days. The rash began as tender papules that quickly progressed to form vesicles and flaccid bullae that rupture easily. The patient has no mucosal lesions or other rashes and has never had similar symptoms before. He is up to date with recommended vaccinations and takes no medications. Skin examination findings are shown below.

4
5
6
7
8
9
10
11
12
13
14
15
16
17
18
19
20
21
22
23
24
25
26
27
28
29
30
31
32
33

symptoms before. He is up to date with recommended vaccinations and takes no medications. Skin examination findings are shown below.

Which of the following is the most likely cause of this patient's skin findings?

A. Autoantibodies targeted against hemidesmosomes

4
5
6
7
8
9
10
11
12
13
14
15
16
17
18
19
20
21
22
23
24
25
26
27
28
29
30
31
32
33

Which of the following is the most likely cause of this patient's skin findings?

A. Autoantibodies targeted against hemidesmosomes

B. Autoantibody-mediated epidermal cell separation

C. Bacterial toxin-induced desmoglein 1 cleavage

D. Defective epidermal barrier and T-cell dysregulation

E. Inflammatory response to viral lytic infection

Submit

4
5
6
7
8
9
10
11
12
13
14
15
16
17
18
19
20
21
22
23
24
25
26
27
28
29
30
31
32
33

Which of the following is the most likely cause of this patient's skin findings?

A. Autoantibodies targeted against hemidesmosomes (13%)

B. Autoantibody-mediated epidermal cell separation (20%)

✓ C. Bacterial toxin-induced desmoglein 1 cleavage (52%)

D. Defective epidermal barrier and T-cell dysregulation (3%)

E. Inflammatory response to viral lytic infection (10%)

Omitted
Correct answer

52%
Answered correctly

07 secs
Time Spent

03/02/2020
Last Updated

4
5
6
7
8
9
10
11
12
13
14
15
16
17
18
19
20
21
22
23
24
25
26
27
28
29
30
31
32
33

Cell junctions and cadherins

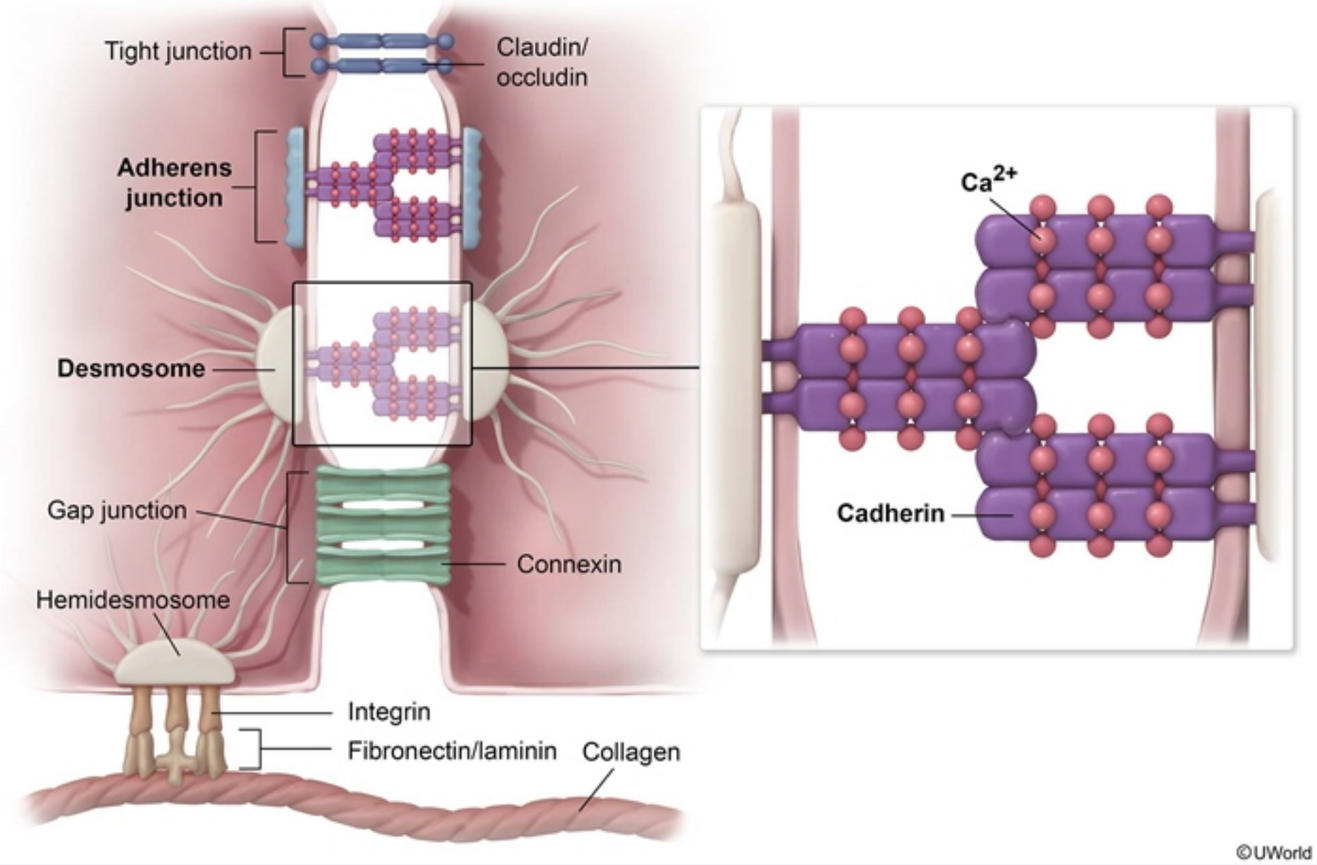

This child has a **blistering skin rash** with tan- to honey-colored **crusts**, consistent with **bullous impetigo** (BI). BI is a superficial infection by *Staphylococcus aureus* that is most common in young children. It is spread by direct contact, with the greatest incidence in warm, humid, crowded environments. Nonbullous impetigo is a similar syndrome with pustules and crusting but without significant blistering. Either form may occur in healthy skin (primary impetigo) or broken/inflamed skin (secondary impetigo).

The blistering in BI is caused by production of **exfoliative toxin A**, a serine protease that targets **desmoglein 1** in the superficial epidermis, by

©UWorld

This child has a **blistering skin rash** with tan- to honey-colored **crusts**, consistent with **bullous impetigo** (BI). BI is a superficial infection by *Staphylococcus aureus* that is most common in young children. It is spread by direct contact, with the greatest incidence in warm, humid, crowded environments. Nonbullous impetigo is a similar syndrome with pustules and crusting but without significant blistering. Either form may occur in healthy skin (primary impetigo) or broken/inflamed skin (secondary impetigo).

The blistering in BI is caused by production of **exfoliative toxin A**, a serine protease that targets **desmoglein 1** in the superficial epidermis, by some strains of *S aureus*. Desmoglein is a **cadherin component of desmosomes** in epidermal cellular junctions; disruption by exfoliative toxin A causes a loss of cell adhesion and leads to formation of flaccid bullae. Exfoliative toxin A is also responsible for staphylococcal scalded skin syndrome, which presents with generalized erythema and flaccid bullae in flexural areas.

(Choices A and B) Bullous pemphigoid is an autoimmune disorder associated with antibodies against hemidesmosomes and is characterized by tense, subepidermal blisters. Pemphigus vulgaris is characterized by intraepithelial cleavage and is due to autoantibodies against desmosomes (desmogleins 1 and 3); it presents with flaccid bullae, desquamation, and oral ulcerations. Both disorders cause scattered or widespread (rather than localized) lesions and are uncommon in children.

(Choice D) Atopic dermatitis is associated with mutations in epidermal barrier proteins, leading to increased exposure to environmental antigens and immune hypersensitivity. It typically presents in infants and young children with erythematous papules and plaques involving the head, trunk, and extensor surfaces, and in older children and adults with lichenification in a flexural distribution (eg, neck, wrists, antecubital and popliteal fossae).

(Choice E) Herpes simplex virus infection is characterized by recurrent clusters of mucocutaneous papules and vesicles that evolve into ulcerated and crusted lesions. It typically causes localized perioral or genital lesions rather than involving large regions on the extremities.

Educational objective:
Bullous impetigo is a superficial infection by *Staphylococcus aureus* that is most common in young children. It is characterized by a blistering skin rash with tan- to honey-colored crusts. The blistering in bullous impetigo is caused by exfoliative toxin A, which targets desmoglein 1 in epidermal cellular junctions and causes a loss of cell adhesion.

References

- Exfoliative toxins of Staphylococcus aureus

Settings

Item 32 of 40
Question Id: 15361

Mark | Previous | Next | Full Screen | Tutorial | Lab Values | Notes | Calculator | Reverse Color | Text Zoom | Settings

©UWorld

Exhibit Display

Zoom In | Zoom Out | Reset | Add To New Card | Existing Card

Exfoliative toxins of Staphylococcus aureus

Block Time Remaining: 00:02:39
TUTOR

8 | Feedback | Suspend | End Block

Settings

4
5
6
7
8
9
10
11
12
13
14
15
16
17
18
19
20
21
22
23
24
25
26
27
28
29
30
31
32
33

Item 32 of 40
Question Id: 15361

Mark | Previous | Next | Full Screen | Tutorial | Lab Values | Notes | Calculator | Reverse Color | Text Zoom | Settings

©UWorld

Exhibit Display

Zoom In | Zoom Out | Reset | Add To New Card | Existing Card

Exfoliative toxins of Staphylococcus aureus

Block Time Remaining: 00:02:39
TUTOR

8 | Feedback | Suspend | End Block

Settings

Item 32 of 40
Question Id: 15361

Mark | Previous | Next | Full Screen | Tutorial | Lab Values | Notes | Calculator | Reverse Color | Text Zoom | Settings

©UWorld

Exhibit Display

Zoom In | Zoom Out | Reset | Add To New Card | Existing Card

Exfoliative toxins of Staphylococcus aureus

Block Time Remaining: 00:02:39
TUTOR

8 | Feedback | Suspend | End Block

Settings

4
5
6
7
8
9
10
11
12
13
14
15
16
17
18
19
20
21
22
23
24
25
26
27
28
29
30
31
32
33

Item 32 of 40
Question Id: 15361

Mark | Previous | Next | Full Screen | Tutorial | Lab Values | Notes | Calculator | Reverse Color | Text Zoom | Settings

©UWorld

Exhibit Display

Zoom In | Zoom Out | Reset | Add To New Card | Existing Card

Exfoliative toxins of Staphylococcus aureus

Block Time Remaining: 00:02:39
TUTOR

8 | Feedback | Suspend | End Block

4
5
6
7
8
9
10
11
12
13
14
15
16
17
18
19
20
21
22
23
24
25
26
27
28
29
30
31
32
33

causes a loss of cell adhesion and leads to formation of flaccid bullae. Exfoliative toxin A is also responsible for staphylococcal scalded skin syndrome, which presents with generalized erythema and flaccid bullae in flexural areas.

(Choices A and B) Bullous pemphigoid is an autoimmune disorder associated with antibodies against hemidesmosomes and is characterized by tense, subepidermal blisters. Pemphigus vulgaris is characterized by intraepithelial cleavage and is due to autoantibodies against desmosomes (desmogleins 1 and 3); it presents with flaccid bullae, desquamation, and oral ulcerations. Both disorders cause scattered or widespread (rather than localized) lesions and are uncommon in children.

(Choice D) Atopic dermatitis is associated with mutations in epidermal barrier proteins, leading to increased exposure to environmental antigens and immune hypersensitivity. It typically presents in infants and young children with erythematous papules and plaques involving the head, trunk, and extensor surfaces, and in older children and adults with lichenification in a flexural distribution (eg, neck, wrists, antecubital and popliteal fossae).

(Choice E) Herpes simplex virus infection is characterized by recurrent clusters of mucocutaneous papules and vesicles that evolve into ulcerated and crusted lesions. It typically causes localized perioral or genital lesions rather than involving large regions on the extremities.

Educational objective:
Bullous impetigo is a superficial infection by *Staphylococcus aureus* that is most common in young children. It is characterized by a blistering skin rash with tan- to honey-colored crusts. The blistering in bullous impetigo is caused by exfoliative toxin A, which targets desmoglein 1 in epidermal cellular junctions and causes a loss of cell adhesion.

References

- Exfoliative toxins of Staphylococcus aureus.
- Autoimmune and infectious skin diseases that target desmogleins.

Pathology	Dermatology	Skin and soft tissue infections
Subject	System	Topic

Copyright © UWorld. All rights reserved.

4
5
6
7
8
9
10
11
12
13
14
15
16
17
18
19
20
21
22
23
24
25
26
27
28
29
30
31
32
33

A 68-year-old man comes to the office to establish care. He has type 2 diabetes mellitus complicated by chronic kidney disease and peripheral sensory neuropathy. Medical history is notable for hypertension and coronary artery disease. The patient works for an agricultural supply company and spends most of his day walking and standing on the warehouse floor. Vital signs are normal. BMI is 34 kg/m^2. Examination of the lower extremities shows decreased sensation to monofilament testing below the knees bilaterally, with 2+ pitting edema, varicosities, and extensive discoloration, as shown below.

4
5
6
7
8
9
10
11
12
13
14
15
16
17
18
19
20
21
22
23
24
25
26
27
28
29
30
31
32
33

Which of the following is the most likely cause of the discoloration in this patient's skin?

- A. Arteriolar calcium phosphate deposition
- B. Cutaneous fungal infection
- C. Glycosaminoglycan accumulation
- D. Hemosiderin deposition
- E. Increased melanin production

Submit

4
5
6
7
8
9
10
11
12
13
14
15
16
17
18
19
20
21
22
23
24
25
26
27
28
29
30
31
32
33

Which of the following is the most likely cause of the discoloration in this patient's skin?

A. Arteriolar calcium phosphate deposition (8%)

B. Cutaneous fungal infection (5%)

C. Glycosaminoglycan accumulation (27%)

✓ D. Hemosiderin deposition (52%)

E. Increased melanin production (5%)

Omitted
Correct answer

52%
Answered correctly

05 secs
Time Spent

02/13/2020
Last Updated

4
5
6
7
8
9
10
11
12
13
14
15
16
17
18
19
20
21
22
23
24
25
26
27
28
29
30
31
32
33

Chronic venous insufficiency

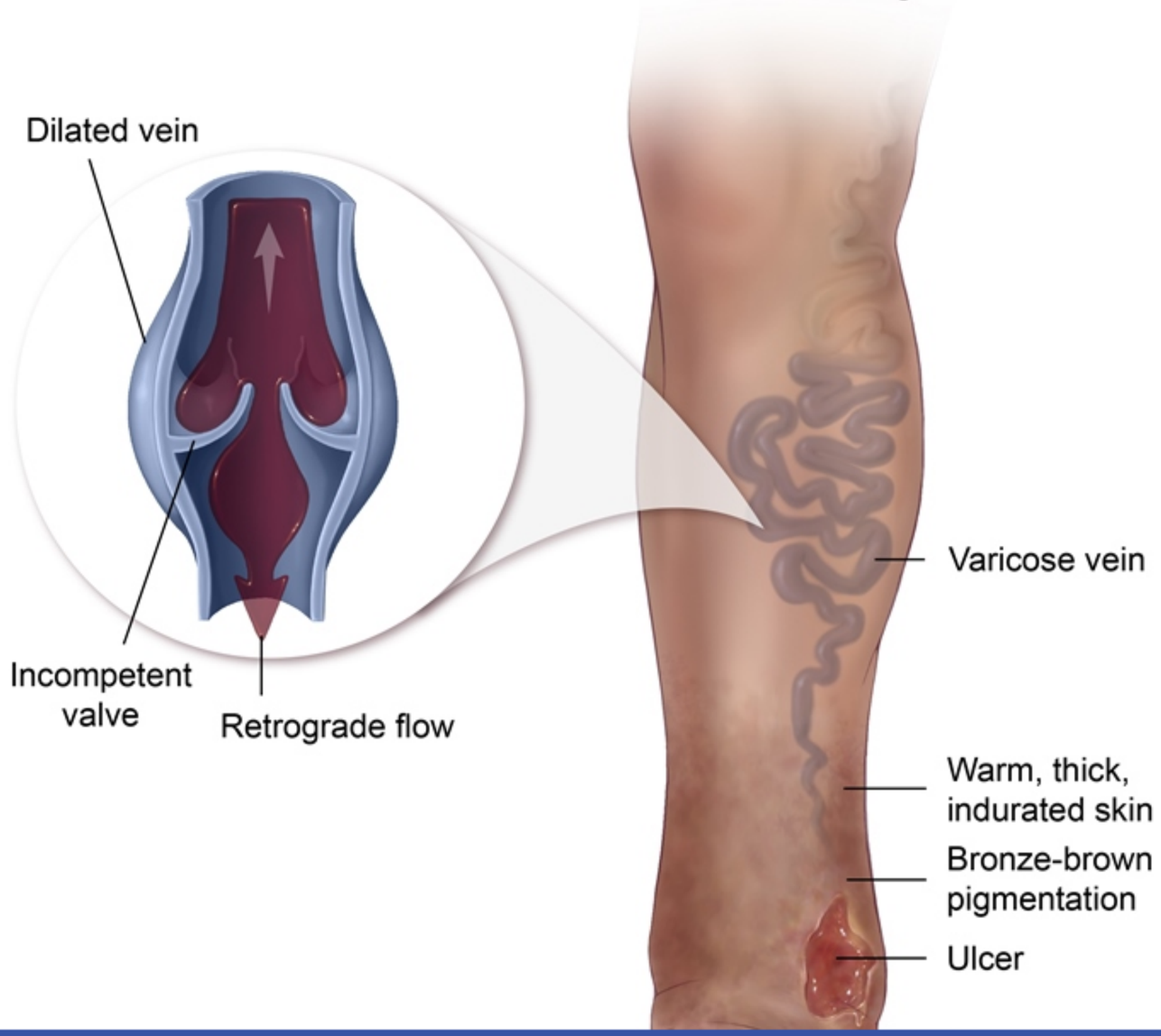

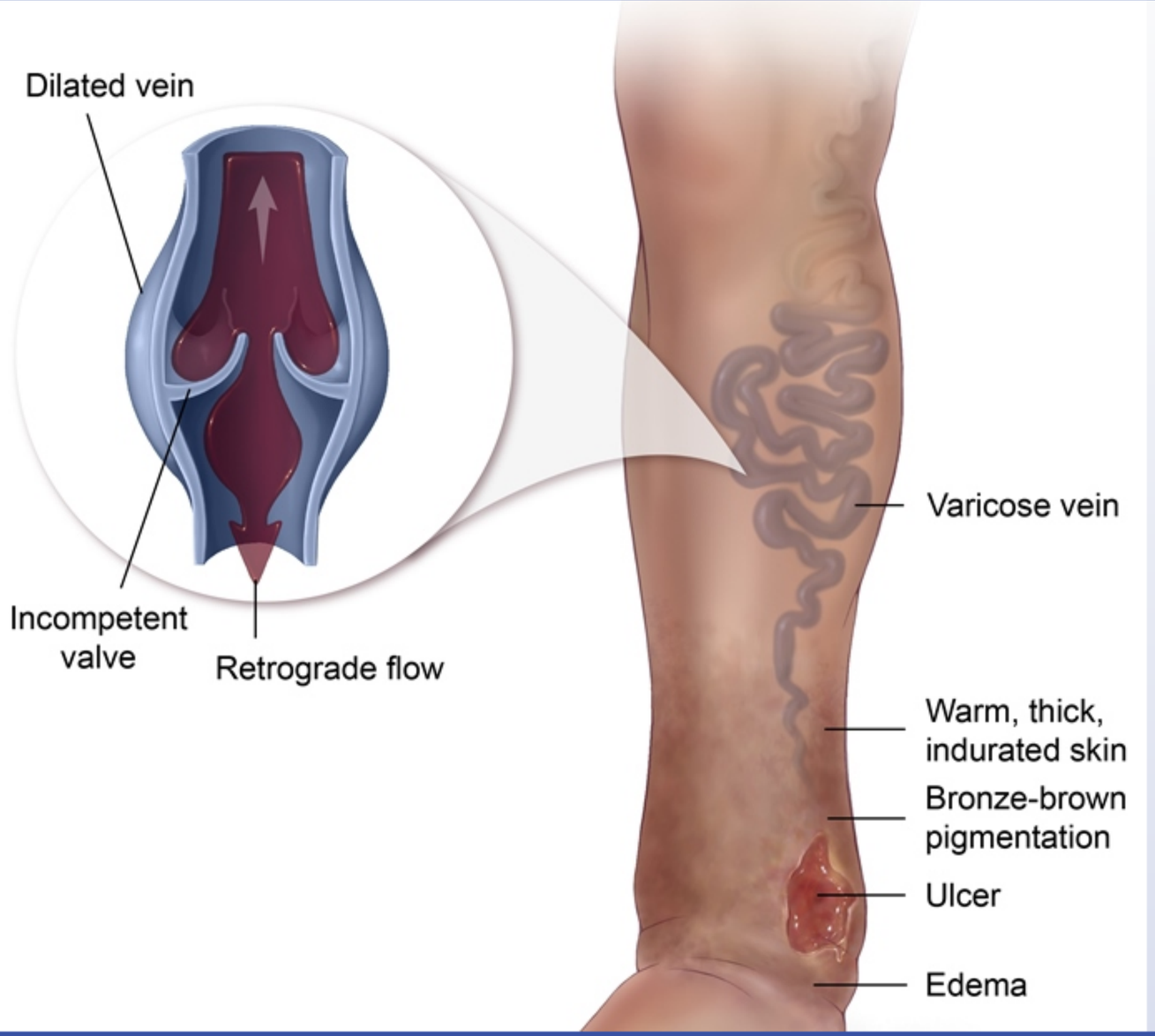
Dilated vein
Incompetent valve
Retrograde flow
Varicose vein
Warm, thick, indurated skin
Bronze-brown pigmentation
Ulcer
Edema

4
5
6
7
8
9
10
11
12
13
14
15
16
17
18
19
20
21
22
23
24
25
26
27
28
29
30
31
32
33

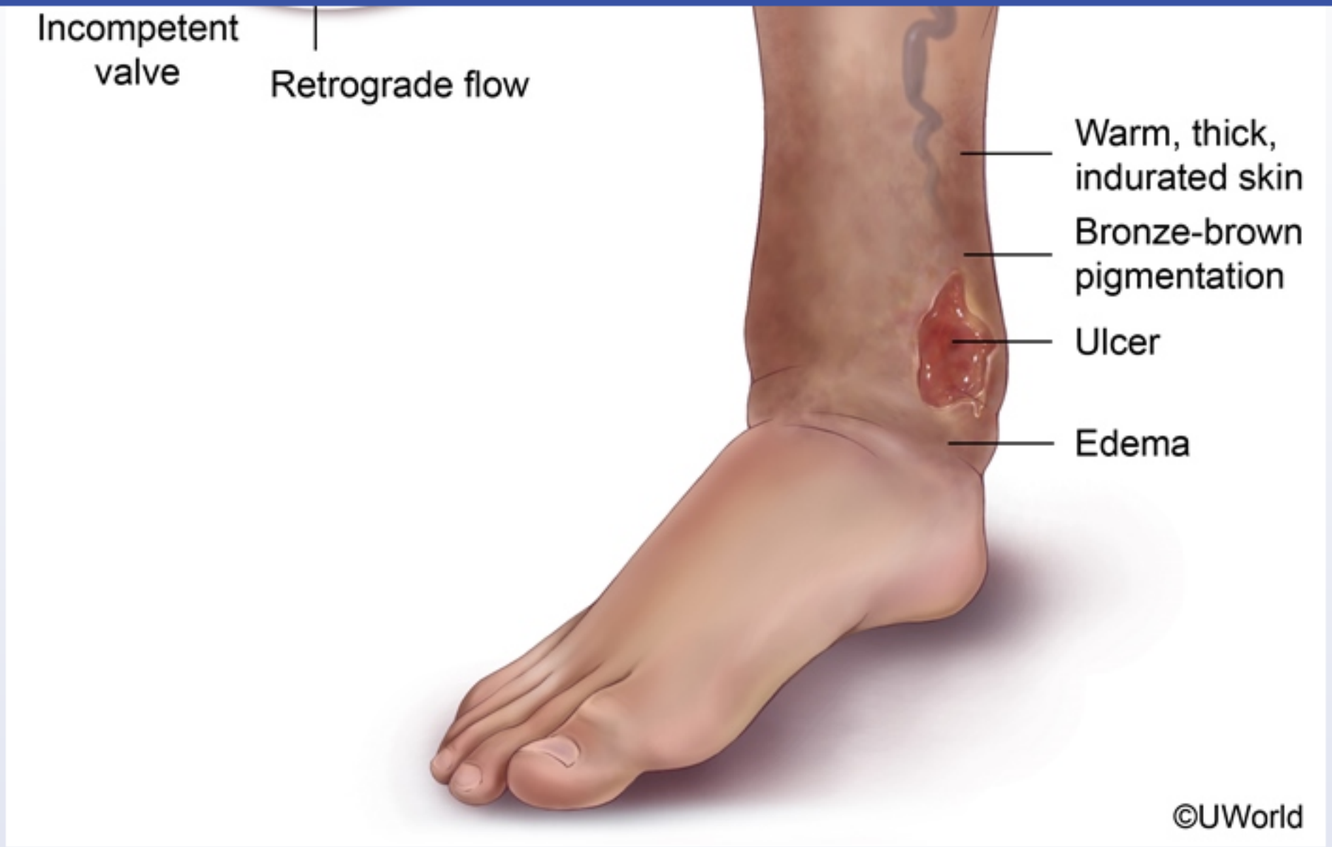

This patient has varicose veins and edema in the lower extremities consistent with **chronic venous insufficiency**. Venous insufficiency is a multifactorial process; contributing factors include obstruction of venous return (eg, pregnancy, **obesity**), increased orthostatic pressure (eg, **prolonged standing**), decreased muscular compression (eg, sedentary lifestyle), and damaged venous valves (eg, due to deep vein thrombosis).

Over time, patients with venous insufficiency can develop extravasation of fluid, plasma proteins, and red cells, leading to chronic inflammation and **stasis dermatitis (SD)**. SD is characterized by erythema, induration, fibrosis, and deposition of **hemosiderin** (from breakdown of extravasated RBCs) manifesting as **reddish-brown discoloration**, as in this patient. Symptoms are typically bilateral and usually worse at or above the ankles. Complications of SD include poor wound healing and **ulceration**.

4
5
6
7
8
9
10
11
12
13
14
15
16
17
18
19
20
21
22
23
24
25
26
27
28
29
30
31
32
33

This patient has varicose veins and edema in the lower extremities consistent with **chronic venous insufficiency**. Venous insufficiency is a multifactorial process; contributing factors include obstruction of venous return (eg, pregnancy, **obesity**), increased orthostatic pressure (eg, **prolonged standing**), decreased muscular compression (eg, sedentary lifestyle), and damaged venous valves (eg, due to deep vein thrombosis).

Over time, patients with venous insufficiency can develop extravasation of fluid, plasma proteins, and red cells, leading to chronic inflammation and **stasis dermatitis (SD)**. SD is characterized by erythema, induration, fibrosis, and deposition of **hemosiderin** (from breakdown of extravasated RBCs) manifesting as **reddish-brown discoloration**, as in this patient. Symptoms are typically bilateral and usually worse at or above the ankles. Complications of SD include poor wound healing and **ulceration**.

(Choice A) Deposition of calcium phosphate salts leads to calcific uremic arteriolopathy (calciphylaxis). This usually occurs in patients with end-stage renal disease receiving hemodialysis and presents with extremely painful nodules, plaques, and ulcers.

(Choice B) Tinea versicolor is a superficial dermatophyte infection that causes primarily macular, rather than regional, pigment changes. It is typically found on the trunk and upper extremities rather than the ankles.

(Choice C) Dermal deposition of glycosaminoglycans is seen in patients with untreated hypothyroidism (ie, myxedema) and Graves disease (ie, thyroid dermopathy). It can manifest as induration and thickening of the skin over the shins.

(Choice E) Chronic radiation dermatitis is characterized by focal fibrosis and increased production of melanin. It is usually seen following external beam radiation therapy for cancer, and the findings are typically most notable in the treatment field.

Educational objective:
Stasis dermatitis is characterized by chronic erythema, fibrosis, and reddish-brown discoloration due to deposition of hemosiderin (from breakdown of extravasated red cells). Symptoms are typically bilateral, and usually worse at or above the ankles. Complications include poor wound healing, weeping, and ulceration.

References

- Stasis dermatitis: pathophysiology, evaluation, and management.

Pathology | Dermatology | Chronic venous insufficiency

A 31-year-old Caucasian female presents to your office for routine check-up. You notice several subcutaneous bumps that seem to be attached to Achilles tendons. Her father died from a heart attack at 35 years old and her mother suffers from rheumatoid arthritis. Her aunt was diagnosed with colon cancer while 55 years old. Which of the following is the best initial test in this patient?

A. Blood cholesterol

B. Fasting blood glucose

C. Rheumatoid factor

D. Antinuclear antibodies

E. Fecal occult blood test

Submit

A 31-year-old Caucasian female presents to your office for routine check-up. You notice several subcutaneous bumps that seem to be attached to Achilles tendons. Her father died from a heart attack at 35 years old and her mother suffers from rheumatoid arthritis. Her aunt was diagnosed with colon cancer while 55 years old. Which of the following is the best initial test in this patient?

- ✓ A. Blood cholesterol (87%)
- B. Fasting blood glucose (1%)
- C. Rheumatoid factor (4%)
- D. Antinuclear antibodies (5%)
- E. Fecal occult blood test (1%)

Omitted
Correct answer
A

87%
Answered correctly

01 sec
Time Spent

02/03/2020
Last Updated

Explanation

Typically associated with hyperlipidemia or lymphoproliferative malignancies, xanthomas are yellow nodules composed of lipid-laden histiocytes in the dermis. Clinically, xanthomas can be divided into five categories: eruptive xanthomas (yellow papules that abruptly appear when plasma triglycerides and lipids increase); tuberous and tendinous xanthomas (the latter are often present on Achilles tendons and the extensor tendons of the fingers); plane xanthomas (linear lesions in skin folds that are strongly associated with primary biliary cirrhosis); and xanthelasma (soft eyelid or periorbital plaques with no associated lipid abnormalities in 50% of affected individuals).

4
5
6
7
8
9
10
11
12
13
14
15
16
17
18
19
20
21
22
23
24
25
26
27
28
29
30
31
32
33

Explanation

Typically associated with hyperlipidemia or lymphoproliferative malignancies, xanthomas are yellow nodules composed of lipid-laden histiocytes in the dermis. Clinically, xanthomas can be divided into five categories: eruptive xanthomas (yellow papules that abruptly appear when plasma triglycerides and lipids increase); tuberous and tendinous xanthomas (the latter are often present on Achilles tendons and the extensor tendons of the fingers); plane xanthomas (linear lesions in skin folds that are strongly associated with primary biliary cirrhosis); and xanthelasma (soft eyelid or periorbital plaques with no associated lipid abnormalities in 50% of affected individuals).

Histologically, xanthomas are composed of benign macrophages packed with finely vacuolated, "foamy" cytoplasm. This cytoplasm contains high levels of cholesterol, phospholipids, and triglycerides. The lipid-laden macrophages are frequently also enclosed by inflammatory cells and fibrotic stroma. With xanthelasmas, the small aggregates of dermal foam cells are present without any surrounding inflammation or fibrosis.

(Choice B) Fasting blood glucose would be appropriate to evaluate in patients suspected of having diabetes mellitus or other glucose metabolic abnormalities.

(Choice C) Rheumatoid factor would be appropriate to evaluate in patients suspected of having rheumatoid arthritis.

(Choice D) Antinuclear antibodies would be appropriate to evaluate in patients suspected of having autoimmune diseases such as systemic lupus erythematosus.

(Choice E) Fecal occult blood test would be appropriate to evaluate in patients suspected of having bleeding of the gastrointestinal tract.

Educational Objective:
Xanthomas are suggestive of hyperlipidemia, especially when present in conjunction with a family history of early cardiac death.

Pathology	Dermatology	Dyslipidemia
Subject	System	Topic

Copyright © UWorld. All rights reserved.

A 56-year-old man is brought to the emergency department with new-onset tonic-clonic seizures. His past medical history is unremarkable. The patient recently has had right-sided headaches and has taken acetaminophen with some relief. MRI of the brain reveals several round lesions in the right temporal lobe. After initial evaluation, a stereotactic biopsy of one of the lesions is performed. The biopsy results show neoplastic tissue containing a mutation in the gene that encodes BRAF, a protein kinase. The point mutation results in a valine → glutamic acid substitution at position 600 of the protein. Which of the following is the most likely diagnosis?

A. Glioblastoma

B. Melanoma

C. Prostate cancer

D. Renal cell carcinoma

E. Small cell lung cancer

Submit

A 56-year-old man is brought to the emergency department with new-onset tonic-clonic seizures. His past medical history is unremarkable. The patient recently has had right-sided headaches and has taken acetaminophen with some relief. MRI of the brain reveals several round lesions in the right temporal lobe. After initial evaluation, a stereotactic biopsy of one of the lesions is performed. The biopsy results show neoplastic tissue containing a mutation in the gene that encodes BRAF, a protein kinase. The point mutation results in a valine → glutamic acid substitution at position 600 of the protein. Which of the following is the most likely diagnosis?

- A. Glioblastoma (10%)
- ✓ B. Melanoma (69%)
- C. Prostate cancer (4%)
- D. Renal cell carcinoma (5%)
- E. Small cell lung cancer (9%)

Omitted
Correct answer
B

69%
Answered correctly

01 sec
Time Spent

05/02/2020
Last Updated

Explanation

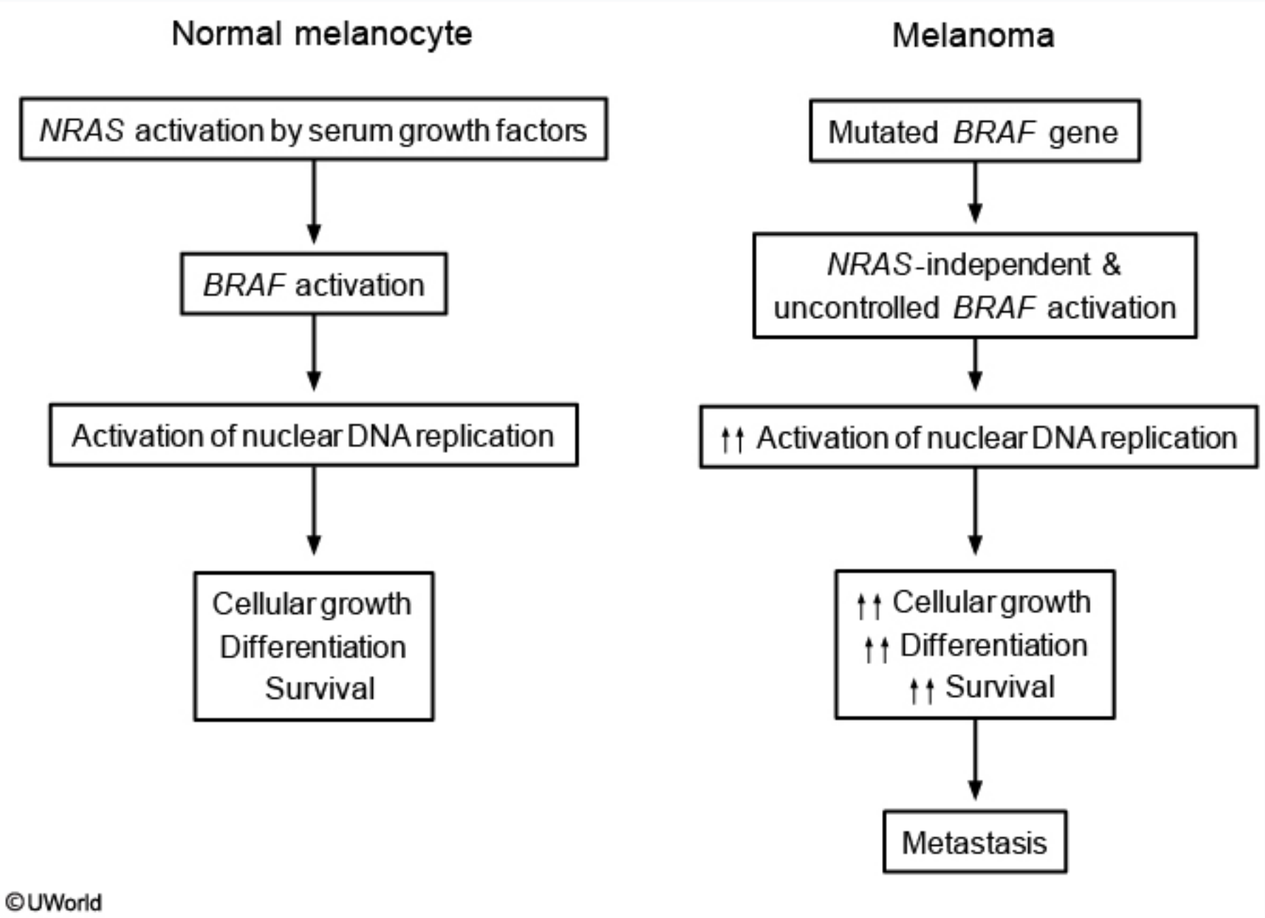

The main environmental risk factor for cutaneous **melanoma** is increased exposure to ultraviolet radiation (eg, solar or tanning bed sources), which can cause malignant transformation of melanocytes. The risk of melanoma is also increased by mutations in specific genetic factors, most commonly tumor suppressor genes and various oncogenes. **BRAF** is a protein kinase involved in activating the signaling pathways of melanocyte proliferation. *BRAF* mutation V600E (valine → glutamic acid), seen in 40%-60% of patients with melanoma, leads to greatly increased **activation** of the signaling pathways for melanocyte growth, survival, and metastasis.

The main environmental risk factor for cutaneous **melanoma** is increased exposure to ultraviolet radiation (eg, solar or tanning bed sources), which can cause malignant transformation of melanocytes. The risk of melanoma is also increased by mutations in specific genetic factors, most commonly tumor suppressor genes and various oncogenes. **BRAF** is a protein kinase involved in activating the signaling pathways of melanocyte proliferation. *BRAF* mutation V600E (valine → glutamic acid), seen in 40%-60% of patients with melanoma, leads to greatly increased **activation** of the signaling pathways for melanocyte growth, survival, and metastasis.

Vemurafenib, a potent inhibitor of mutated BRAF, has significant anti-tumor effects with improved survival and long-term outcomes in advanced stage V600E-positive melanoma patients. The presence of this *BRAF* mutation in this patient's tissue sample most likely indicates a diagnosis of metastatic melanoma.

(Choice A) Glioblastoma is more likely to present as a single lesion; *BRAF* mutations are less common than with melanoma.

(Choice C) Prostate cancer is associated with *BRCA1* and *BRCA2* mutations, not *BRAF* mutations. *BRCA* mutations also increase the risk of breast cancer.

(Choices D and E) Renal cell carcinoma and small cell lung cancer appear to be multifactorial in origin, involving many different genes and environmental factors. However, *BRAF* has not been associated with either malignancy.

Educational objective:
BRAF is a protein kinase involved in activation of signaling pathways for melanocyte proliferation; the *BRAF* V600E mutation is seen in 40%-60% of patients with melanoma.

References

- Improved survival with vemurafenib in melanoma with BRAF V600E mutation.
- Incidence of the V600K mutation among melanoma patients with BRAF mutations, and potential therapeutic response to the specific BRAF inhibitor PLX4032.

Pathology	Dermatology	Melanoma
Subject	System	Topic

Settings

Item 35 of 40
Question Id: 7707

Mark | Previous | Next | Full Screen | Tutorial | Lab Values | Notes | Calculator | Reverse Color | Text Zoom | Settings

Exhibit Display

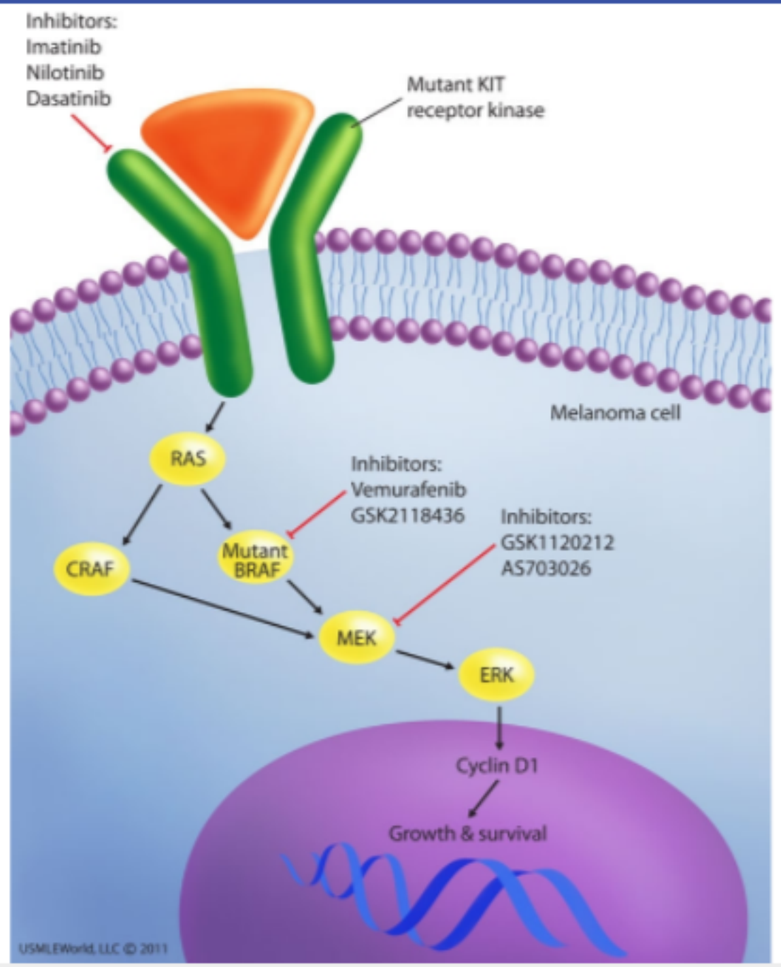

Zoom In | Zoom Out | Reset | Add To New Card | Existing Card

Subject System Topic

Block Time Remaining: 00:02:46
TUTOR

Feedback | Suspend | End Block

A 65-year-old man comes to the office due to skin lesions on his back. He first noted the spots 5 years ago and says they are becoming more numerous. The lesions are occasionally pruritic but are otherwise asymptomatic. The patient did not come for evaluation previously because he "did not care about them," but made an appointment now at his wife's insistence. Medical history is notable for hypertension, hyperlipidemia, and type 2 diabetes mellitus. On examination, there are numerous pigmented plaques, as shown in the image below.

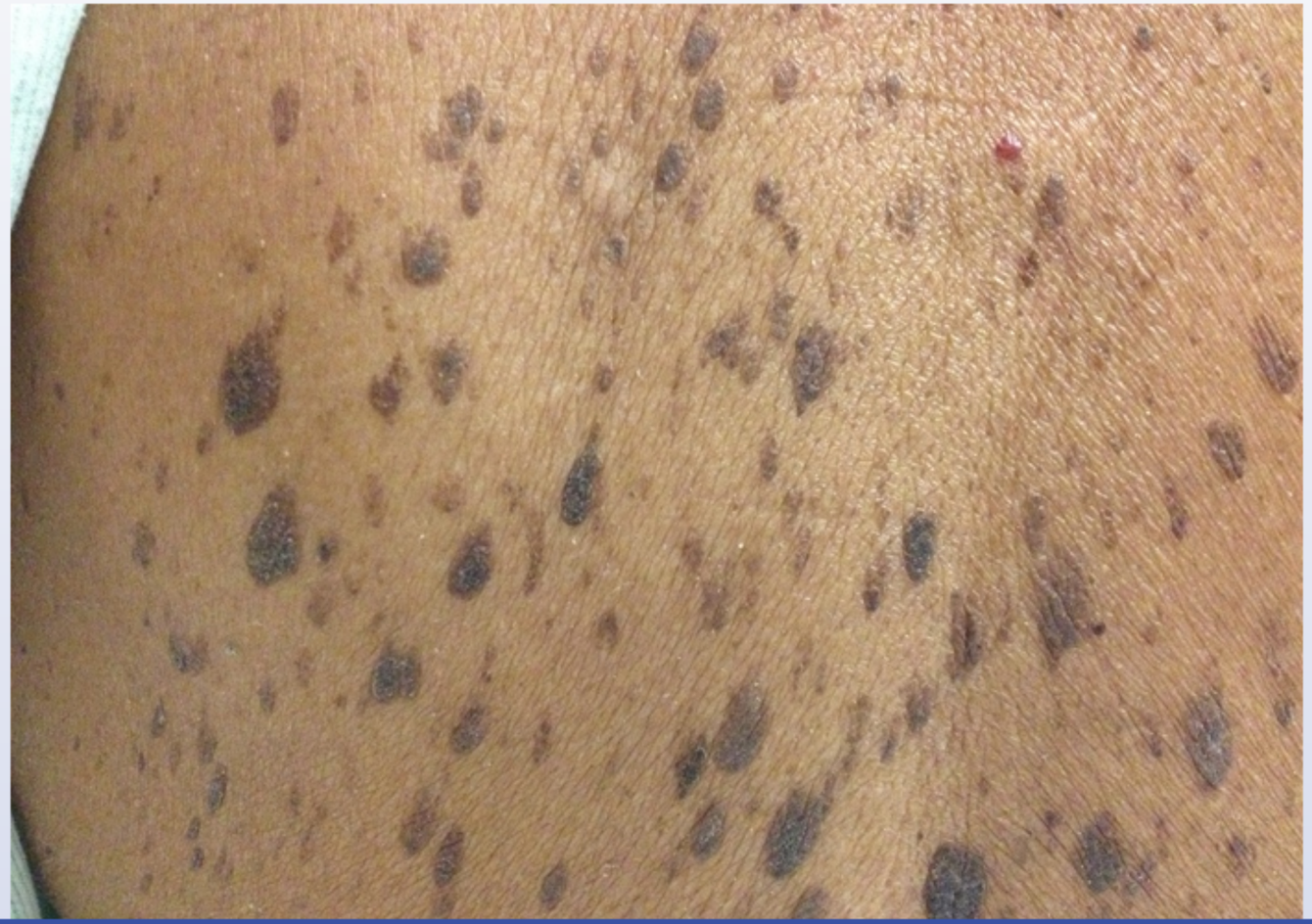

Settings

4
5
6
7
8
9
10
11
12
13
14
15
16
17
18
19
20
21
22
23
24
25
26
27
28
29
30
31
32
33

Item 36 of 40
Question Id: 1112

Mark | Previous | Next | Full Screen | Tutorial | Lab Values | Notes | Calculator | Reverse Color | Text Zoom | Settings

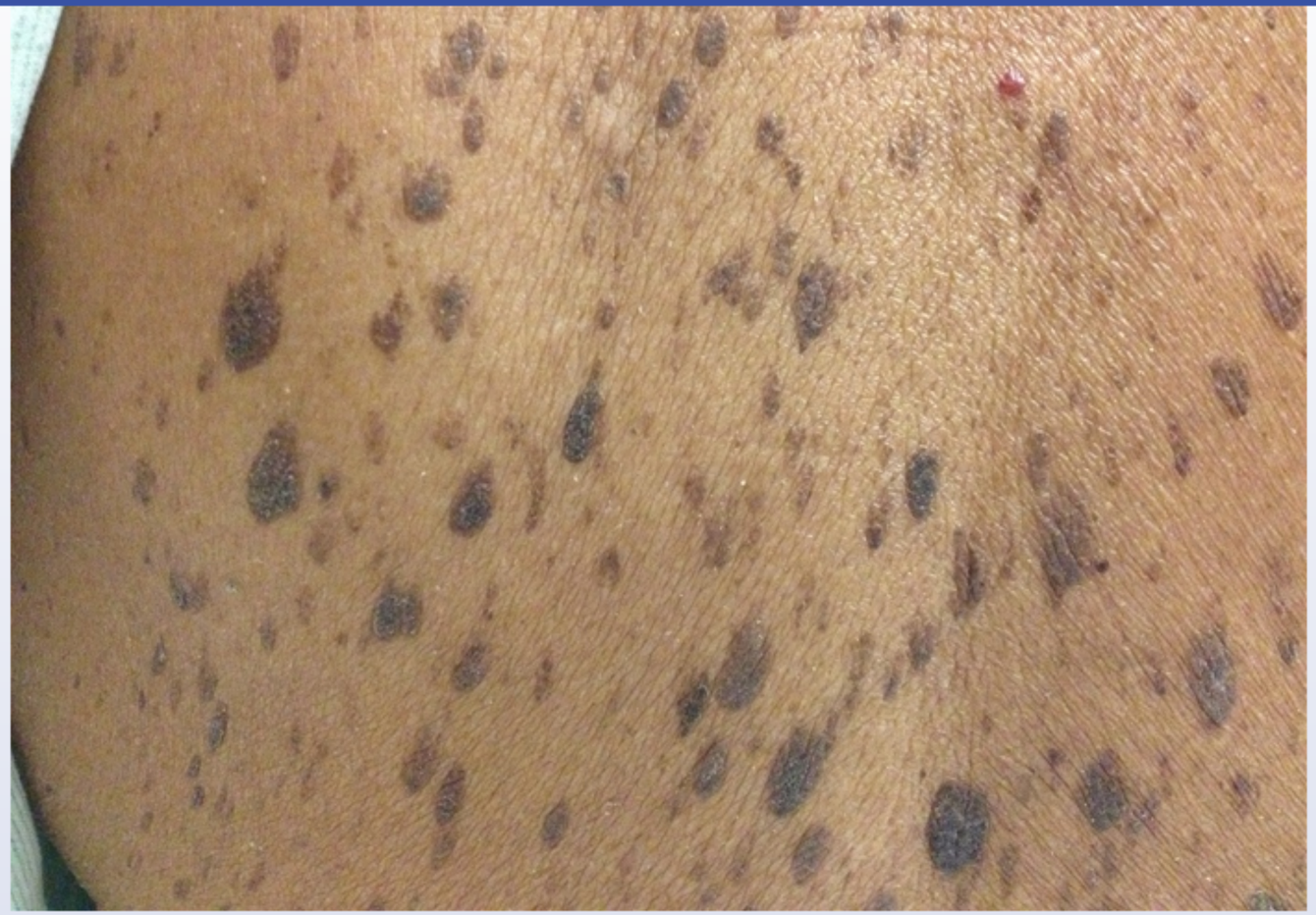

Which of the following is the most likely diagnosis?

A. Acanthosis nigricans

B. Actinic keratosis

C. Lichen planus

Block Time Remaining: 00:02:49
TUTOR

10 | Feedback | Suspend | End Block

4 5 6 7 8 9 10 11 12 13 14 15 16 17 18 19 20 21 22 23 24 25 26 27 28 29 30 31 32 33

Which of the following is the most likely diagnosis?

- A. Acanthosis nigricans
- B. Actinic keratosis
- C. Lichen planus
- D. Malignant melanoma
- E. Psoriasis
- F. Seborrheic keratosis

Submit

4
5
6
7
8
9
10
11
12
13
14
15
16
17
18
19
20
21
22
23
24
25
26
27
28
29
30
31
32
33

Which of the following is the most likely diagnosis?

A. Acanthosis nigricans (8%)

B. Actinic keratosis (10%)

C. Lichen planus (9%)

D. Malignant melanoma (4%)

E. Psoriasis (0%)

✓ F. Seborrheic keratosis (67%)

Omitted
Correct answer

67%
Answered correctly

06 secs
Time Spent

03/20/2020
Last Updated

Explanation

Seborrheic keratosis (SK) (plural: keratoses) is a common, tan or brown, epidermal tumor occurring in middle-aged or elderly individuals. It has a variable appearance from nearly flat macules to raised, wart-like lesions, ranging in size from a few millimeters to centimeters. SK typically has a velvety or greasy surface and well-demarcated border, and is often described as having a **"stuck-on" appearance**. On microscopic examination, the lesions of SK are composed of small cells resembling basal cells, with variable pigmentation, hyperkeratosis (thickening of the stratum corneum), and keratin-containing cysts.

The etiology of SK is not fully understood; however, it is frequently associated with activating mutations of the **fibroblast growth factor receptor 3**. SK itself is benign, but **rapid onset of numerous SK**s (Leser-Trélat sign) is often associated with an **internal malignancy** (eg, gastric adenocarcinoma), possibly due to overproduction of insulin-like growth factor 1 and other cytokines.

(Choice A) Acanthosis nigricans is characterized by hyperpigmented, velvety plaques at flexural areas (eg, axilla, posterior neck). It is associated with diabetes mellitus, obesity, visceral malignancy, and various endocrinopathies.

(Choice B) Actinic keratosis presents with hyperkeratotic lesions in sun-exposed areas of the scalp, ears, face, and hands. These lesions are unpigmented and, despite the similar name, are unrelated to seborrheic keratosis.

(Choice C) Lichen planus is characterized by the "5 Ps": polygonal, planar, pruritic, purplish plaques on the wrists, hands, trunk, and legs. Fine white lines (Wickham striae) may be present on the plaque surface.

(Choice D) Melanoma characteristically presents as an asymmetric, pigmented lesion with an irregular border, variable coloration, and change in size and appearance over time. Multifocal development of monotonous, otherwise asymptomatic lesions is much more typical of SK.

(Choice E) Psoriasis presents with scaly, nonpigmented plaques. Although it may occur on the trunk, it is more common on the extensor surfaces of the extremities.

Educational objective:
Seborrheic keratosis is a common epidermal tumor that presents as a tan or brown, round lesion with a well-demarcated border and "stuck-on" appearance. Microscopic examination shows small cells resembling basal cells, with pigmentation, hyperkeratosis, and keratin-containing cysts. Rapid onset of numerous lesions is often associated with internal malignancy (Leser-Trélat sign).

Settings

4
5
6
7
8
9
10
11
12
13
14
15
16
17
18
19
20
21
22
23
24
25
26
27
28
29
30
31
32
33

Item 36 of 40
Question Id: 1112

Mark | Previous | Next | Full Screen | Tutorial | Lab Values | Notes | Calculator | Reverse Color | Text Zoom | Settings

Explanation

Exhibit Display

Zoom In | Zoom Out | Reset | Add To New Card | Existing Card

Rapid onset of numerous lesions is often associated with internal malignancy (Leser-Trélat sign).

Block Time Remaining: 00:02:52
TUTOR

10 | Feedback | Suspend | End Block

Settings

4
5
6
7
8
9
10
11
12
13
14
15
16
17
18
19
20
21
22
23
24
25
26
27
28
29
30
31
32
33

Item 36 of 40
Question Id: 1112

Mark | Previous | Next | Full Screen | Tutorial | Lab Values | Notes | Calculator | Reverse Color | Text Zoom | Settings

Explanation

Exhibit Display

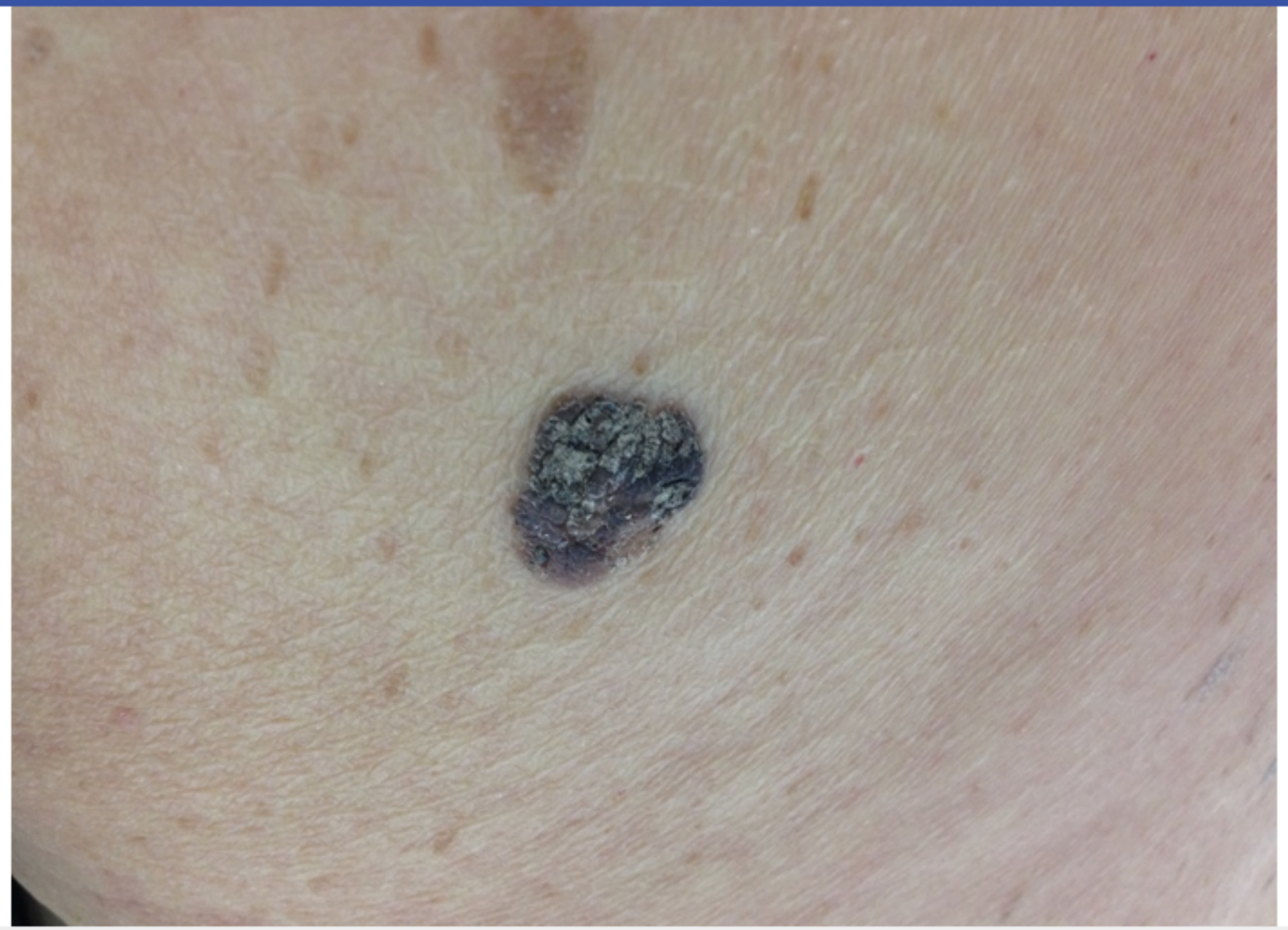

Zoom In | Zoom Out | Reset | Add To New Card | Existing Card

Rapid onset of numerous lesions is often associated with internal malignancy (Leser-Trélat sign).

Block Time Remaining: 00:02:52
TUTOR

10 | Feedback | Suspend | End Block

Settings

Item 36 of 40
Question Id: 1112

Mark | Previous | Next | Full Screen | Tutorial | Lab Values | Notes | Calculator | Reverse Color | Text Zoom | Settings

Explanation

Exhibit Display

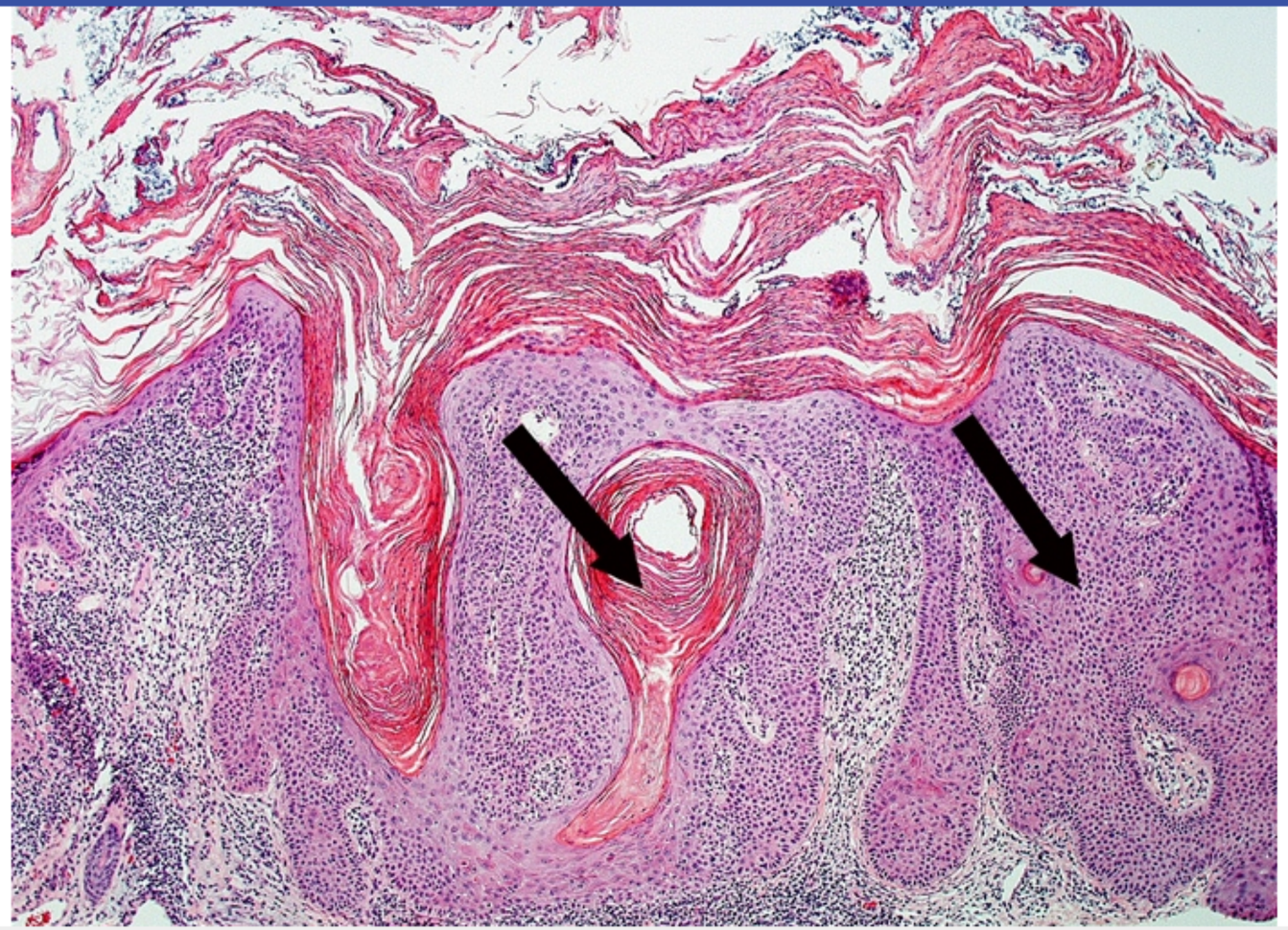

Zoom In | Zoom Out | Reset | Add To New Card | Existing Card

Rapid onset of numerous lesions is often associated with internal malignancy (Leser-Trélat sign).

Block Time Remaining: 00:02:52
TUTOR

10 | Feedback | Suspend | End Block

Settings

4
5
6
7
8
9
10
11
12
13
14
15
16
17
18
19
20
21
22
23
24
25
26
27
28
29
30
31
32
33

Item 36 of 40
Question Id: 1112

Mark | Previous | Next | Full Screen | Tutorial | Lab Values | Notes | Calculator | Reverse Color | Text Zoom | Settings

Explanation

Exhibit Display

Zoom In | Zoom Out | Reset | Add To New Card | Existing Card

Rapid onset of numerous lesions is often associated with internal malignancy (Leser-Trélat sign).

Block Time Remaining: 00:02:52
TUTOR

10 | Feedback | Suspend | End Block

Settings

4
5
6
7
8
9
10
11
12
13
14
15
16
17
18
19
20
21
22
23
24
25
26
27
28
29
30
31
32
33

Item 36 of 40
Question Id: 1112

Mark | Previous | Next | Full Screen | Tutorial | Lab Values | Notes | Calculator | Reverse Color | Text Zoom | Settings

Explanation

Exhibit Display

Zoom In | Zoom Out | Reset | Add To New Card | Existing Card

Rapid onset of numerous lesions is often associated with internal malignancy (Leser-Trélat sign).

Block Time Remaining: 00:02:52
TUTOR

10 | Feedback | Suspend | End Block

Settings

4
5
6
7
8
9
10
11
12
13
14
15
16
17
18
19
20
21
22
23
24
25
26
27
28
29
30
31
32
33

Item 36 of 40
Question Id: 1112

Mark | Previous | Next | Full Screen | Tutorial | Lab Values | Notes | Calculator | Reverse Color | Text Zoom | Settings

Explanation

Exhibit Display

Zoom In | Zoom Out | Reset | Add To New Card | Existing Card

Rapid onset of numerous lesions is often associated with internal malignancy (Leser-Trélat sign).

Block Time Remaining: 00:02:52
TUTOR

10 | Feedback | Suspend | End Block

Settings

4
5
6
7
8
9
10
11
12
13
14
15
16
17
18
19
20
21
22
23
24
25
26
27
28
29
30
31
32
33

Item 36 of 40
Question Id: 1112

Mark | Previous | Next | Full Screen | Tutorial | Lab Values | Notes | Calculator | Reverse Color | Text Zoom | Settings

Explanation

Exhibit Display

Zoom In | Zoom Out | Reset | Add To New Card | Existing Card

Rapid onset of numerous lesions is often associated with internal malignancy (Leser-Trélat sign).

Block Time Remaining: 00:02:52
TUTOR

10 | Feedback | Suspend | End Block

Settings

4
5
6
7
8
9
10
11
12
13
14
15
16
17
18
19
20
21
22
23
24
25
26
27
28
29
30
31
32
33

Item 36 of 40
Question Id: 1112

Mark | Previous | Next | Full Screen | Tutorial | Lab Values | Notes | Calculator | Reverse Color | Text Zoom | Settings

Explanation

Exhibit Display

Zoom In | Zoom Out | Reset | Add To New Card | Existing Card

Rapid onset of numerous lesions is often associated with internal malignancy (Leser-Trélat sign).

Block Time Remaining: 00:02:52
TUTOR

10 | Feedback | Suspend | End Block

stratum corneum), and keratin-containing cysts.

The etiology of SK is not fully understood; however, it is frequently associated with activating mutations of the **fibroblast growth factor receptor 3**. SK itself is benign, but **rapid onset of numerous SK**s (Leser-Trélat sign) is often associated with an **internal malignancy** (eg, gastric adenocarcinoma), possibly due to overproduction of insulin-like growth factor 1 and other cytokines.

(Choice A) Acanthosis nigricans is characterized by hyperpigmented, velvety plaques at flexural areas (eg, axilla, posterior neck). It is associated with diabetes mellitus, obesity, visceral malignancy, and various endocrinopathies.

(Choice B) Actinic keratosis presents with hyperkeratotic lesions in sun-exposed areas of the scalp, ears, face, and hands. These lesions are unpigmented and, despite the similar name, are unrelated to seborrheic keratosis.

(Choice C) Lichen planus is characterized by the "5 Ps": polygonal, planar, pruritic, purplish plaques on the wrists, hands, trunk, and legs. Fine white lines (Wickham striae) may be present on the plaque surface.

(Choice D) Melanoma characteristically presents as an asymmetric, pigmented lesion with an irregular border, variable coloration, and change in size and appearance over time. Multifocal development of monotonous, otherwise asymptomatic lesions is much more typical of SK.

(Choice E) Psoriasis presents with scaly, nonpigmented plaques. Although it may occur on the trunk, it is more common on the extensor surfaces of the extremities.

Educational objective:
Seborrheic keratosis is a common epidermal tumor that presents as a tan or brown, round lesion with a well-demarcated border and "stuck-on" appearance. Microscopic examination shows small cells resembling basal cells, with pigmentation, hyperkeratosis, and keratin-containing cysts. Rapid onset of numerous lesions is often associated with internal malignancy (Leser-Trélat sign).

Pathology	Dermatology	Seborrheic keratosis
Subject	System	Topic

Copyright © UWorld. All rights reserved.

4 5 6 7 8 9 10 11 12 13 14 15 16 17 18 19 20 21 22 23 24 25 26 27 28 29 30 31 32 33

A 32-year-old woman is brought to the emergency department due to "bruising." She has a chronic mental disability and lives in a group home. Care staff members accompanying the patient report that she fell 3 days ago but has not mentioned any pain. No signs of injury were noted until a large area of discoloration was seen at the upper arm during bathing. Past medical history is unremarkable, and the patient takes no medications. Vital signs are normal. Skin examination findings are shown in the image below. There is no associated warmth, and the patient shows no signs of discomfort during palpation of the affected area.

Which of the following terms best describes this abnormality?

4 5 6 7 8 9 10 11 12 13 14 15 16 17 18 19 20 21 22 23 24 25 26 27 28 29 30 31 32 33

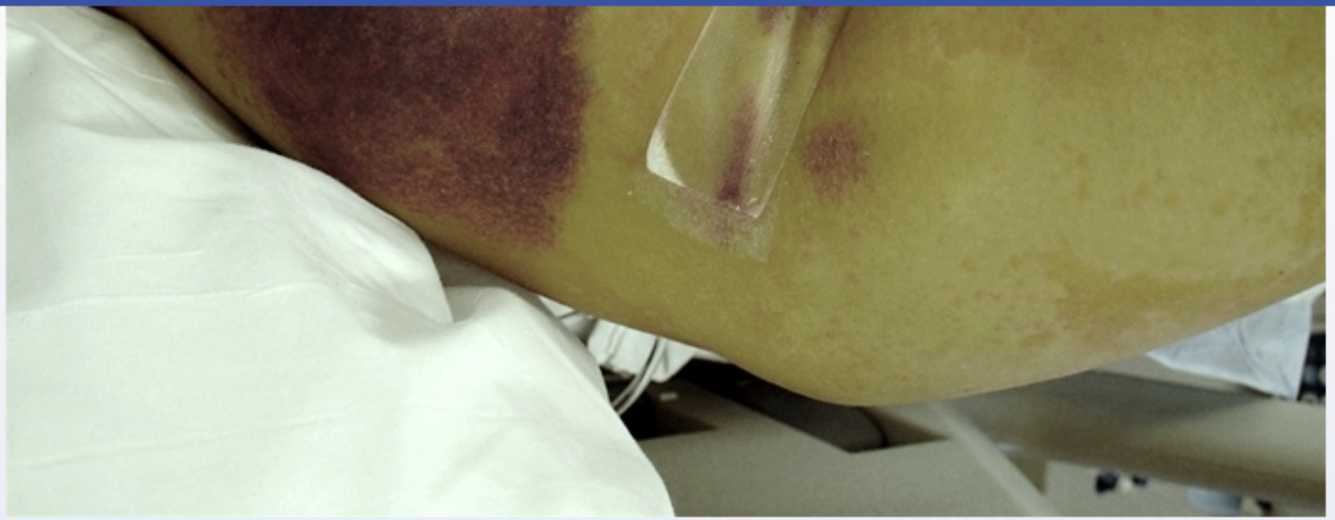

Which of the following terms best describes this abnormality?

- A. Angioma
- B. Ecchymosis
- C. Lentigo
- D. Petechia
- E. Purpura
- F. Telangiectasia

Submit

4 5 6 7 8 9 10 11 12 13 14 15 16 17 18 19 20 21 22 23 24 25 26 27 28 29 30 31 32 33

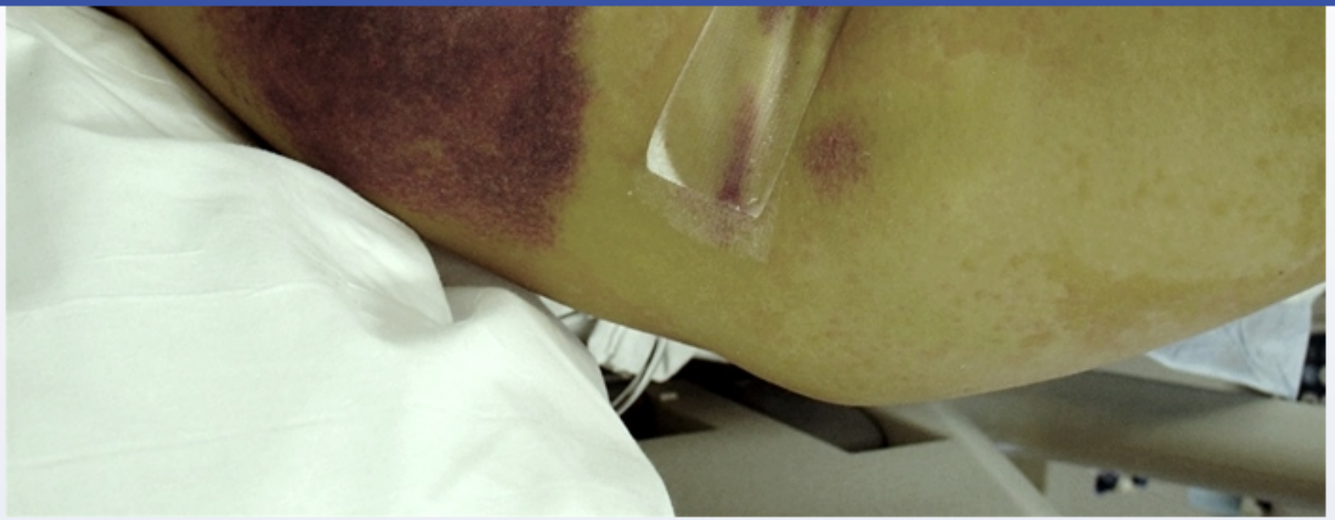

Which of the following terms best describes this abnormality?

- A. Angioma (3%)
- ✓ B. Ecchymosis (80%)
- C. Lentigo (1%)
- D. Petechia (0%)
- E. Purpura (12%)
- F. Telangiectasia (1%)

Omitted
Correct answer

80%
Answered correctly

04 secs
Time Spent

02/11/2020
Last Updated

Explanation

This patient has a large area of **ecchymosis** involving the upper extremity. Patients and caregivers often use the term "bruise" to describe a variety of hemorrhagic skin lesions. However, the specific visual appearance often gives clues to the etiology of the lesion.

An ecchymosis is a cutaneous or subcutaneous collection of **extravasated blood** measuring at least 1 cm in diameter. Ecchymoses can arise superficially without a history of noticeable trauma, but they frequently indicate a deep hemorrhage (hematoma) due to bony fracture, ligamentous rupture, or muscular injury. These lesions do not blanch under pressure because the red blood cells are not contained within the vasculature. Ecchymoses often pass through an evolution of color change (blue or red to brown, green, and yellow), which can be used to estimate the age of the injury. This property is especially useful in cases of suspected abuse when other historical details are unknown or inconsistent.

(Choice A) Angiomas are chronic vascular malformations that most commonly appear as soft, well-demarcated, red or blue nodules. Capillary hemangiomas are usually small and superficial whereas cavernous hemangiomas are usually larger and more likely to involve deeper structures.

(Choice C) Lentigines are small tan or brown macules most often seen on the sun-exposed skin of a middle-aged or elderly person.

(Choices D and E) Petechiae (<5 mm diameter) and purpura (5 mm to 1 cm) are cutaneous or subcutaneous collections of extravasated blood from small-vessel bleeding that are often associated with platelet dysfunction or capillary fragility. They occur most commonly in areas of increased venous pressure (eg, ankles, feet). Palpable purpura are an indicator of leukocytoclastic vasculitis.

(Choice F) Telangiectasias are small, permanent dilations of superficial capillaries or venules. Telangiectasias will blanch under pressure and are commonly seen in aging, chronic solar damage, long-term glucocorticoid use, rosacea, and a variety of systemic disorders.

Educational objective:
Ecchymoses frequently indicate a deep hemorrhage (hematoma) due to bony fracture, ligamentous rupture, or muscular injury. They do not blanch under pressure as the red blood cells are not contained within the vasculature. Ecchymoses often pass through an evolution of color change (blue or red to brown, green, and yellow), which can be used to estimate the age of the injury.

Pathology	Dermatology	Primary hemostasis
Subject	System	Topic

Settings

Item 37 of 40
Question Id: 1878

Mark | Previous | Next | Full Screen | Tutorial | Lab Values | Notes | Calculator | Reverse Color | Text Zoom | Settings

Explanation

Exhibit Display

Zoom In | Zoom Out | Reset | Add To New Card | Existing Card

Block Time Remaining: 00:02:56
TUTOR

8 | Feedback | Suspend | End Block

Settings

Item 37 of 40
Question Id: 1878

Mark | Previous | Next | Full Screen | Tutorial | Lab Values | Notes | Calculator | Reverse Color | Text Zoom | Settings

Explanation

Exhibit Display

Zoom In | Zoom Out | Reset | Add To New Card | Existing Card

Block Time Remaining: 00:02:56
TUTOR

8 | Feedback | Suspend | End Block

Settings

4
5
6
7
8
9
10
11
12
13
14
15
16
17
18
19
20
21
22
23
24
25
26
27
28
29
30
31
32
33

Item 37 of 40
Question Id: 1878

Mark | Previous | Next | Full Screen | Tutorial | Lab Values | Notes | Calculator | Reverse Color | Text Zoom | Settings

Explanation

Exhibit Display

Zoom In | Zoom Out | Reset | Add To New Card | Existing Card

Block Time Remaining: 00:02:56
TUTOR

8 | Feedback | Suspend | End Block

Settings

Item 37 of 40
Question Id: 1878

Mark | Previous | Next | Full Screen | Tutorial | Lab Values | Notes | Calculator | Reverse Color | Text Zoom | Settings

Explanation

Exhibit Display

Zoom In | Zoom Out | Reset | Add To New Card | Existing Card

Block Time Remaining: 00:02:56
TUTOR

8 | Feedback | Suspend | End Block

Settings

4
5
6
7
8
9
10
11
12
13
14
15
16
17
18
19
20
21
22
23
24
25
26
27
28
29
30
31
32
33

Item 37 of 40
Question Id: 1878

Mark | Previous | Next | Full Screen | Tutorial | Lab Values | Notes | Calculator | Reverse Color | Text Zoom | Settings

Explanation

Exhibit Display

Zoom In | Zoom Out | Reset | Add To New Card | Existing Card

Block Time Remaining: 00:02:56
TUTOR

8 | Feedback | Suspend | End Block

Settings

Item 37 of 40
Question Id: 1878

Mark | Previous | Next | Full Screen | Tutorial | Lab Values | Notes | Calculator | Reverse Color | Text Zoom | Settings

Explanation

Exhibit Display

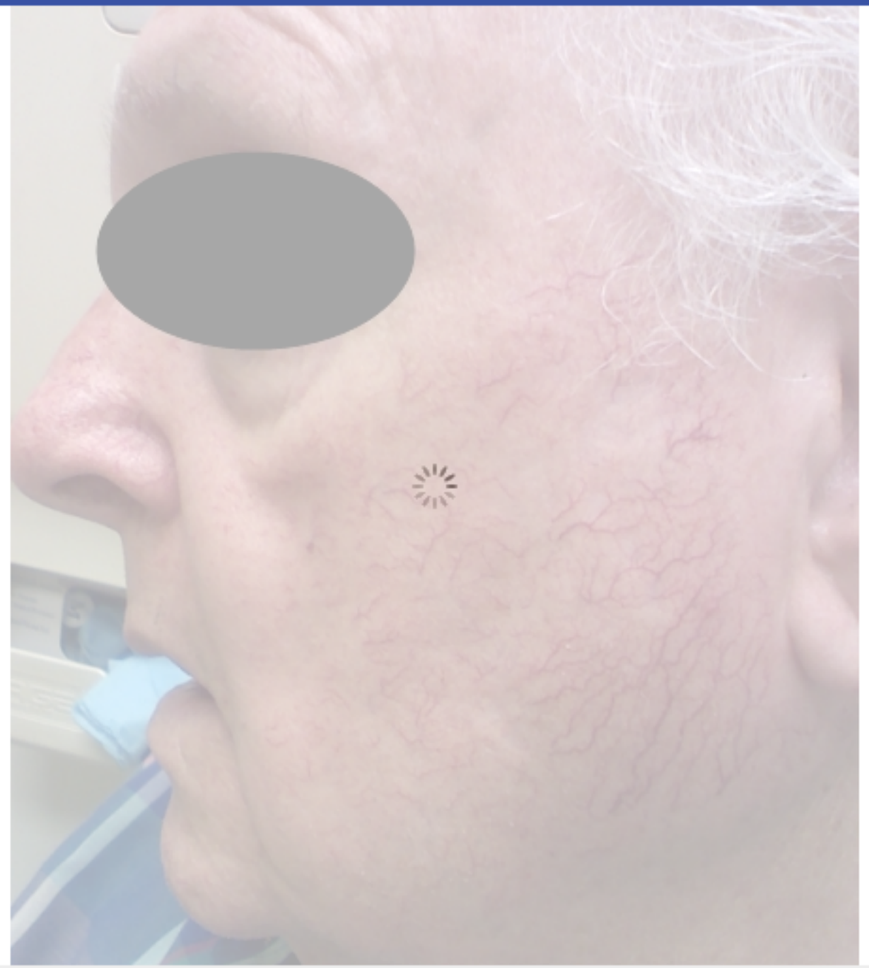

Zoom In | Zoom Out | Reset | Add To New Card | Existing Card

Block Time Remaining: 00:02:56
TUTOR

8 | Feedback | Suspend | End Block

11
12
13
14
15
16
17
18
19
20
21
22
23
24
25
26
27
28
29
30
31
32
33
34
35
36
37
38
39
40

A 79-year-old woman comes to the office due to bleeding from an ulcerative lesion on her right nipple. The lesion is itchy, has been there for several months, and is slowly increasing in size. Examination shows a crusty, thickened, erythematous, and ulcerated nodule with evidence of hyperpigmentation. Changes extend to the surrounding areola. Excisional biopsy reveals relatively well-circumscribed aggregates of large, polygonal, pleomorphic cells with abundant mitotic activity and surrounding necrosis. S-100 and HMB-45 stains are diffusely positive. Which of the following is the most likely diagnosis?

A. Basal cell carcinoma

B. Melanoma

C. Paget disease of the breast

D. Seborrheic keratosis

E. Squamous cell skin cancer

Submit

11
12
13
14
15
16
17
18
19
20
21
22
23
24
25
26
27
28
29
30
31
32
33
34
35
36
37
38
39
40

A 79-year-old woman comes to the office due to bleeding from an ulcerative lesion on her right nipple. The lesion is itchy, has been there for several months, and is slowly increasing in size. Examination shows a crusty, thickened, erythematous, and ulcerated nodule with evidence of hyperpigmentation. Changes extend to the surrounding areola. Excisional biopsy reveals relatively well-circumscribed aggregates of large, polygonal, pleomorphic cells with abundant mitotic activity and surrounding necrosis. S-100 and HMB-45 stains are diffusely positive. Which of the following is the most likely diagnosis?

A. Basal cell carcinoma (2%)
✓ B. Melanoma (62%)
C. Paget disease of the breast (30%)
D. Seborrheic keratosis (0%)
E. Squamous cell skin cancer (3%)

Omitted
Correct answer
B

62%
Answered correctly

02 secs
Time Spent

02/25/2020
Last Updated

Explanation

This older patient has a crusted, ulcerated, hyperpigmented nodule on the nipple and areola. Biopsy was performed to differentiate Paget disease of the breast **(Choice C)**, an adenocarcinoma of the areolar epithelium, from nodular **malignant melanoma**. Histopathology revealed poorly differentiated cells with abundant mitotic activity and necrosis. Subsequent immunostaining was positive for **S-100** (a protein expressed in cells derived from the **neural crest** such as melanocytes) and **HMB-45** (a monoclonal antibody that binds to **immature melanosomes** found in melanocytic tumors) indicating melanoma.

Explanation

This older patient has a crusted, ulcerated, hyperpigmented nodule on the nipple and areola. Biopsy was performed to differentiate Paget disease of the breast **(Choice C)**, an adenocarcinoma of the areolar epithelium, from nodular **malignant melanoma**. Histopathology revealed poorly differentiated cells with abundant mitotic activity and necrosis. Subsequent immunostaining was positive for **S-100** (a protein expressed in cells derived from the **neural crest** such as melanocytes) and **HMB-45** (a monoclonal antibody that binds to **immature melanosomes** found in melanocytic tumors) indicating melanoma.

Immunostaining is often used to assist the diagnosis of melanoma because histopathologic features are sometimes insufficient to confirm the diagnosis. Tumor cells that stain **positive for multiple melanocyte markers** (as in this case) are very likely to be melanoma. S-100 is positive in >95% of melanoma tumors, and HMB-45 is both highly sensitive (>95%) and highly specific (~100%) for the malignancy.

(Choice A) Basal cell carcinoma usually appears on the face as a nodular, flesh colored papule. Although scaly trunk lesions can occasionally occur, this tumor is derived from basal epithelial cells and would not stain positive for melanocyte markers.

(Choice D) Seborrheic keratosis is a benign skin lesion that is well demarcated (appears "stuck on") with a verrucous surface. These lesions are derived from immature keratinocytes and would not stain positive for multiple melanin markers.

(Choice E) Squamous cell carcinoma is most common on the head and neck but can also occasionally arise on the trunk. It generally appears as hyperkeratotic plaque, nodule, or papule. Because it is derived from epithelial cells (not melanocytes), multiple melanin markers would not be positive.

Educational objective:
Melanoma is often diagnosed when immunostaining of biopsy samples reveals multiple melanocyte markers (eg, S-100, HMB-45, MART-1).

Pathology	Dermatology	Melanoma
Subject	System	Topic

Copyright © UWorld. All rights reserved.

Settings

11
12
13
14
15
16
17
18
19
20
21
22
23
24
25
26
27
28
29
30
31
32
33
34
35
36
37
38
39
40

Item 38 of 40
Question Id: 16865

Mark | Previous | Next | Full Screen | Tutorial | Lab Values | Notes | Calculator | Reverse Color | Text Zoom | Settings

Explanation

Exhibit Display

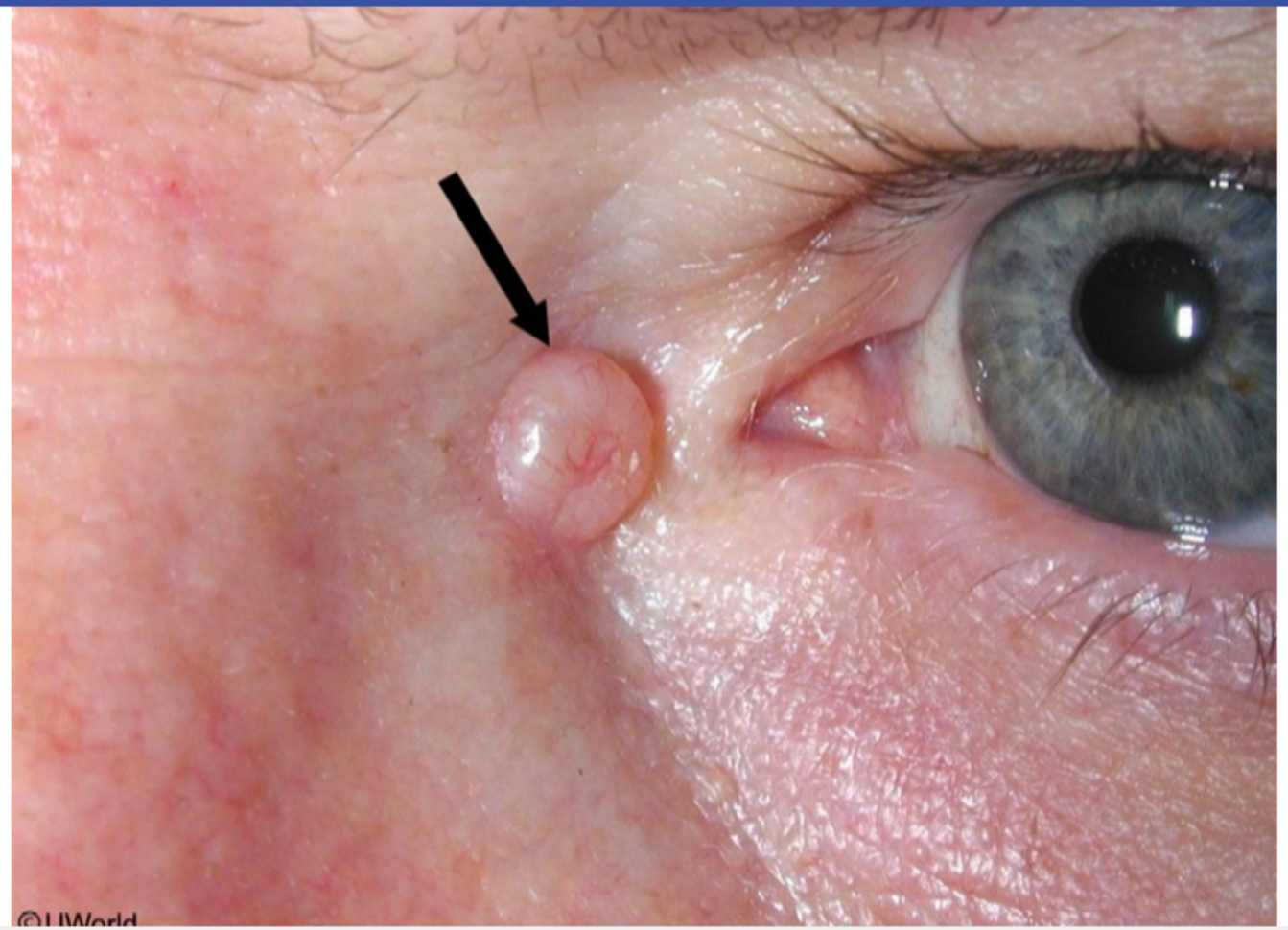

Zoom In | Zoom Out | Reset | Add To New Card | Existing Card

Block Time Remaining: 00:02:58
TUTOR

4 | Feedback | Suspend | End Block

Settings

11
12
13
14
15
16
17
18
19
20
21
22
23
24
25
26
27
28
29
30
31
32
33
34
35
36
37
38
39
40

Item 38 of 40
Question Id: 16865

Mark | Previous | Next | Full Screen | Tutorial | Lab Values | Notes | Calculator | Reverse Color | Text Zoom | Settings

Explanation

Exhibit Display

Zoom In | Zoom Out | Reset | Add To New Card | Existing Card

Block Time Remaining: 00:02:58
TUTOR

4 | Feedback | Suspend | End Block

Settings

11
12
13
14
15
16
17
18
19
20
21
22
23
24
25
26
27
28
29
30
31
32
33
34
35
36
37
38
39
40

Item 38 of 40
Question Id: 16865

Mark | Previous | Next | Full Screen | Tutorial | Lab Values | Notes | Calculator | Reverse Color | Text Zoom | Settings

Explanation

Exhibit Display

Zoom In | Zoom Out | Reset | Add To New Card | Existing Card

Block Time Remaining: 00:02:58
TUTOR

4 | Feedback | Suspend | End Block

11
12
13
14
15
16
17
18
19
20
21
22
23
24
25
26
27
28
29
30
31
32
33
34
35
36
37
38
39
40

A 28-year-old woman is brought to the emergency department by her family due to acute left flank pain. The pain radiates to her groin and is associated with pink hematuria and urinary urgency. Past medical history is unremarkable, and the patient has never experienced similar symptoms. CT scan of the urinary system confirms the presence of a stone at the ureterovesical junction. The patient is given intravenous morphine sulfate for pain relief. Fifteen minutes later, she develops diffuse itching involving the arms, legs, and back. Which of the following is the most likely mechanism causing this patient's adverse reaction?

A. IgE-dependent mast cell degranulation

B. IgE-independent mast cell degranulation

C. Inhibition of prostaglandin synthesis

D. Precipitation of immune complexes

E. T cell release of inflammatory cytokines

Submit

11
12
13
14
15
16
17
18
19
20
21
22
23
24
25
26
27
28
29
30
31
32
33
34
35
36
37
38
39
40

A 28-year-old woman is brought to the emergency department by her family due to acute left flank pain. The pain radiates to her groin and is associated with pink hematuria and urinary urgency. Past medical history is unremarkable, and the patient has never experienced similar symptoms. CT scan of the urinary system confirms the presence of a stone at the ureterovesical junction. The patient is given intravenous morphine sulfate for pain relief. Fifteen minutes later, she develops diffuse itching involving the arms, legs, and back. Which of the following is the most likely mechanism causing this patient's adverse reaction?

- A. IgE-dependent mast cell degranulation (57%)
- ✓ B. IgE-independent mast cell degranulation (36%)
- C. Inhibition of prostaglandin synthesis (1%)
- D. Precipitation of immune complexes (2%)
- E. T cell release of inflammatory cytokines (2%)

Omitted
Correct answer
B

36%
Answered correctly

02 secs
Time Spent

01/20/2020
Last Updated

Explanation

This patient with acute pruritus following administration of morphine most likely has medication-induced **IgE-independent** mast cell activation. A number of medications, including **opioids**, **radiocontrast agents**, and some antibiotics (eg, **vancomycin**), can induce mast cell degranulation by activation of protein kinase A and PI3 kinase. This results in release of several mediators, including histamine, bradykinin, heparin, and a number of enzymes and chemotactic factors. Common symptoms include diffuse itching and pain, bronchospasm, and localized swelling (urticaria).

Explanation

This patient with acute pruritus following administration of morphine most likely has medication-induced **IgE-independent** mast cell activation. A number of medications, including **opioids**, **radiocontrast agents**, and some antibiotics (eg, **vancomycin**), can induce mast cell degranulation by activation of protein kinase A and PI3 kinase. This results in release of several mediators, including histamine, bradykinin, heparin, and a number of enzymes and chemotactic factors. Common symptoms include diffuse itching and pain, bronchospasm, and localized swelling (urticaria).

(Choice A) IgE-mediated degranulation is typically associated with environmental exposures such as foods or vespid stings or with medications such as beta-lactam and sulfonamide antibiotics. Opioids can cause IgE-dependent degranulation (very rare), but IgE-independent reactions are more common.

(Choice C) Inhibition of cyclooxygenase 1 by aspirin and nonsteroidal anti-inflammatory drugs can trigger urticaria in patients with chronic idiopathic urticaria. These medications shunt arachidonic acid metabolites toward formation of leukotrienes, which increase vascular permeability.

(Choice D) Serum sickness is a type III hypersensitivity reaction caused by precipitation of circulating immune complexes. Typical symptoms include fever, pruritic rash, and arthralgias starting 7-14 days after antigen exposure. Common triggers include beta-lactam and sulfonamide antibiotics.

(Choice E) Acute allergic contact dermatitis is caused by a T cell-mediated type IV (delayed) hypersensitivity reaction to an antigen on the skin surface. Gross findings include erythematous, papulovesicular, weeping lesions.

Educational objective:
A number of medications, including opioids, radiocontrast agents, and some antibiotics (eg, vancomycin), can trigger IgE-independent mast cell degranulation. Common symptoms include diffuse itching and pain, bronchospasm, and localized swelling (urticaria).

References

- Pharmacological stimuli in asthma/urticaria.
- Pathogenic intracellular and autoimmune mechanisms in urticaria and angioedema.
- Codeine induces human mast cell chemokine and cytokine production: involvement of G-protein activation.

Settings

11
12
13
14
15
16
17
18
19
20
21
22
23
24
25
26
27
28
29
30
31
32
33
34
35
36
37
38
39
40

Item 39 of 40
Question Id: 11852

Mark | Previous | Next | Full Screen | Tutorial | Lab Values | Notes | Calculator | Reverse Color | Text Zoom | Settings

Explanation

Exhibit Display

Zoom In | Zoom Out | Reset | Add To New Card | Existing Card

Block Time Remaining: 00:03:00
TUTOR

5 | Feedback | Suspend | End Block

Settings

11
12
13
14
15
16
17
18
19
20
21
22
23
24
25
26
27
28
29
30
31
32
33
34
35
36
37
38
39
40

Item 39 of 40
Question Id: 11852

Mark | Previous | Next | Full Screen | Tutorial | Lab Values | Notes | Calculator | Reverse Color | Text Zoom | Settings

Explanation

Exhibit Display

Zoom In | Zoom Out | Reset | Add To New Card | Existing Card

Block Time Remaining: 00:03:00
TUTOR

5 | Feedback | Suspend | End Block

A 12-year-old boy is brought to the office due to a week of nonproductive cough and rash. He has also had low-grade fevers, malaise, and headaches. The patient has no prior medical conditions and is up to date with immunizations. Lung examination reveals bilateral crackles and wheezes. There is a diffuse rash on his torso and extremities as shown in the exhibit. Which of the following is the most likely cause of this patient's skin lesions?

A. Cytotoxic T-cell–mediated epithelial injury

B. Inflammatory reaction in subcutaneous fat

C. Keratinocyte hyperproliferation and parakeratosis

D. Subepidermal immunoglobulin A deposition

E. Vasoactive mediator release from mast cells

Submit

Settings

- 11
- 12
- 13
- 14
- 15
- 16
- 17
- 18
- 19
- 20
- 21
- 22
- 23
- 24
- 25
- 26
- 27
- 28
- 29
- 30
- 31
- 32
- 33
- 34
- 35
- 36
- 37
- 38
- 39
- 40

Item 40 of 40
Question Id: 15695

Mark | Previous | Next | Full Screen | Tutorial | Lab Values | Notes | Calculator | Reverse Color | Text Zoom | Settings

Exhibit Display

Zoom In | Zoom Out | Reset | Add To New Card | Existing Card

Block Time Remaining: 00:03:04
TUTOR

7 | Feedback | Suspend | End Block

A 12-year-old boy is brought to the office due to a week of nonproductive cough and rash. He has also had low-grade fevers, malaise, and headaches. The patient has no prior medical conditions and is up to date with immunizations. Lung examination reveals bilateral crackles and wheezes. There is a diffuse rash on his torso and extremities as shown in the exhibit. Which of the following is the most likely cause of this patient's skin lesions?

- ✓ A. Cytotoxic T-cell–mediated epithelial injury (54%)
- B. Inflammatory reaction in subcutaneous fat (9%)
- C. Keratinocyte hyperproliferation and parakeratosis (1%)
- D. Subepidermal immunoglobulin A deposition (13%)
- E. Vasoactive mediator release from mast cells (21%)

Omitted
Correct answer
A

54%
Answered correctly

07 secs
Time Spent

04/07/2020
Last Updated

Explanation

This patient's target-shaped skin lesions likely indicate **erythema multiforme** (EM), an acute, inflammatory skin disorder that usually develops in the setting of an ongoing **infection**. Although herpes simplex virus is the most common trigger, respiratory tract infections due to ***Mycoplasma pneumoniae*** (eg, low-grade fever, headache, fatigue, cough, wheezes) frequently cause EM in children.

EM develops when circulating pathogens are phagocytosed by peripheral mononuclear cells and are brought to the epidermis, where DNA fragments are transferred to keratinocytes via direct cell-to-cell spread (facilited by upregulation of adhesion molecules). Pathogen-specific

This patient's target-shaped skin lesions likely indicate **erythema multiforme** (EM), an acute, inflammatory skin disorder that usually develops in the setting of an ongoing **infection**. Although herpes simplex virus is the most common trigger, respiratory tract infections due to ***Mycoplasma pneumoniae*** (eg, low-grade fever, headache, fatigue, cough, wheezes) frequently cause EM in children.

EM develops when circulating pathogens are phagocytosed by peripheral mononuclear cells and are brought to the epidermis, where DNA fragments are transferred to keratinocytes via direct cell-to-cell spread (facilited by upregulation of adhesion molecules). Pathogen-specific **cytotoxic T-cells** then recognize foreign antigens produced by keratinocytes and initiate an inflammatory cascade that results in epithelial damage.

Manifestations of EM include **target-shaped lesions** on the extremities and trunk that have a central dusky area, a surrounding pale ring of edema, and a peripheral halo of erythema. Mucosal lesions also sometimes occur.

(Choice B) Erythema nodosum is a delayed-type hypersensitivity reaction that causes inflammatory nodules in the subcutaneous fat. Although it can be triggered by infection, patients generally have tender, erythematous nodules on the bilateral shins (not target-shaped lesions).

(Choice C) Psoriasis is an immune-mediated inflammatory disease associated with cytokine-driven keratinocyte hyperproliferation and parakeratosis. It usually causes erythematous, chronic skin plaques with silvery scales on the extensor elbows, scalp, and/or knees.

(Choice D) Dermatitis herpetiformis, a manifestation of gluten sensitivity, is caused by the subepidermal deposition of IgA. It is associated with pruritic papules and vesicles on the forearms, knees, and/or scalp (not target-shaped lesions).

(Choice E) Urticaria is caused by the release of inflammatory and vasoactive mediators from mast cells in the superficial dermis. Infections (eg, parasites) can cause urticaria, but patients generally have well-circumscribed, raised, pruritic, erythematous plaques. Sometimes the lesions have central pallor, but they are not target-shaped.

Educational objective:
Erythema multiforme is a target-shaped, inflammatory skin lesion that typically arises in the setting of infection, particularly with herpes simplex virus or *Mycoplasma pneumoniae*. It is caused by the deposition of infectious antigens in keratinocytes, leading to a strong cell-mediated (eg, cytotoxic T-cell) immune response.

EM develops when circulating pathogens are phagocytosed by peripheral mononuclear cells and are brought to the epidermis, where DNA fragments are transferred to keratinocytes via direct cell-to-cell spread (facilited by upregulation of adhesion molecules). Pathogen-specific **cytotoxic T-cells** then recognize foreign antigens produced by keratinocytes and initiate an inflammatory cascade that results in epithelial damage.

Manifestations of EM include **target-shaped lesions** on the extremities and trunk that have a central dusky area, a surrounding pale ring of edema, and a peripheral halo of erythema. Mucosal lesions also sometimes occur.

(Choice B) Erythema nodosum is a delayed-type hypersensitivity reaction that causes inflammatory nodules in the subcutaneous fat. Although it can be triggered by infection, patients generally have tender, erythematous nodules on the bilateral shins (not target-shaped lesions).

(Choice C) Psoriasis is an immune-mediated inflammatory disease associated with cytokine-driven keratinocyte hyperproliferation and parakeratosis. It usually causes erythematous, chronic skin plaques with silvery scales on the extensor elbows, scalp, and/or knees.

(Choice D) Dermatitis herpetiformis, a manifestation of gluten sensitivity, is caused by the subepidermal deposition of IgA. It is associated with pruritic papules and vesicles on the forearms, knees, and/or scalp (not target-shaped lesions).

(Choice E) Urticaria is caused by the release of inflammatory and vasoactive mediators from mast cells in the superficial dermis. Infections (eg, parasites) can cause urticaria, but patients generally have well-circumscribed, raised, pruritic, erythematous plaques. Sometimes the lesions have central pallor, but they are not target-shaped.

Educational objective:
Erythema multiforme is a target-shaped, inflammatory skin lesion that typically arises in the setting of infection, particularly with herpes simplex virus or *Mycoplasma pneumoniae*. It is caused by the deposition of infectious antigens in keratinocytes, leading to a strong cell-mediated (eg, cytotoxic T-cell) immune response.

Pathology	Dermatology	Erythema multiforme
Subject	System	Topic

Copyright © UWorld. All rights reserved.

Settings

11
12
13
14
15
16
17
18
19
20
21
22
23
24
25
26
27
28
29
30
31
32
33
34
35
36
37
38
39
40

Item 40 of 40
Question Id: 15695

Mark | Previous | Next | Full Screen | Tutorial | Lab Values | Notes | Calculator | Reverse Color | Text Zoom | Settings

EM develops when circulating pathogens are phagocytosed by peripheral mononuclear cells and are brought to the epidermis, where DNA

Exhibit Display

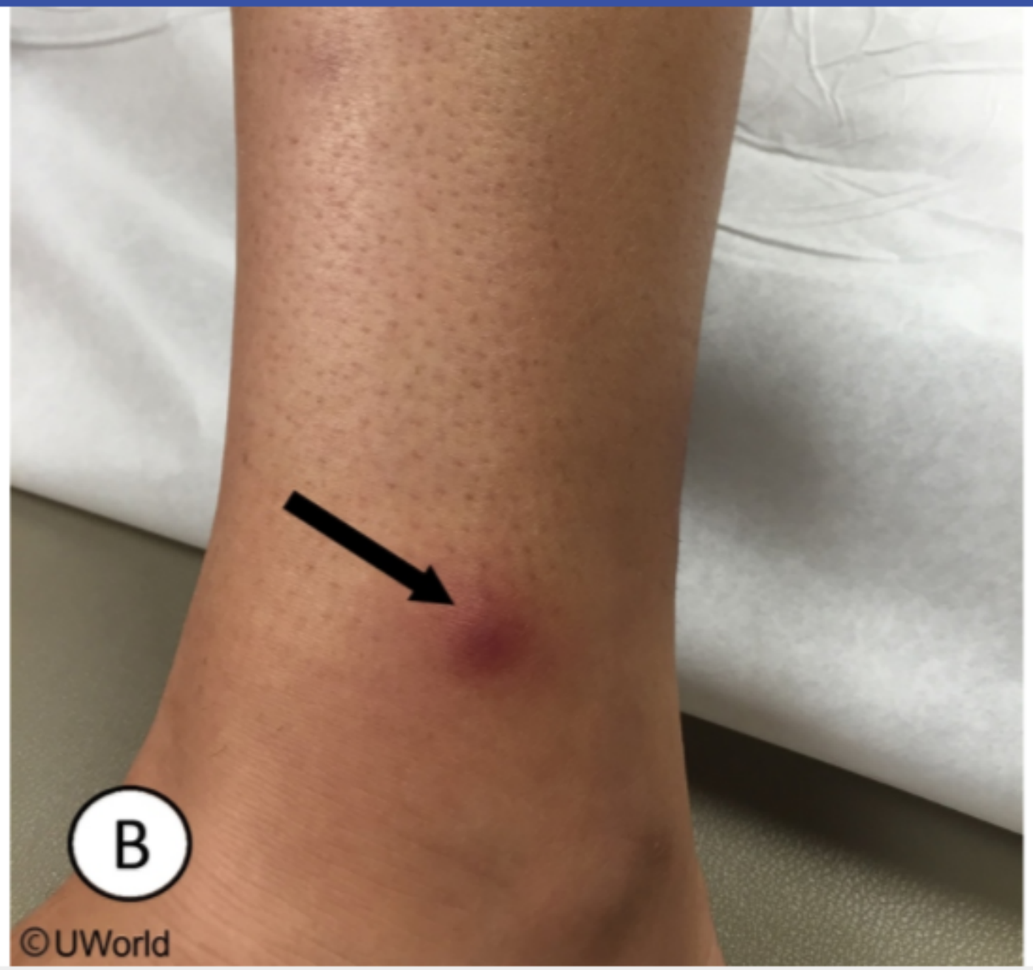

Zoom In | Zoom Out | Reset | Add To New Card | Existing Card

Block Time Remaining: 00:03:07
TUTOR

7 | Feedback | Suspend | End Block

Settings

11
12
13
14
15
16
17
18
19
20
21
22
23
24
25
26
27
28
29
30
31
32
33
34
35
36
37
38
39
40

Item 40 of 40
Question Id: 15695

Mark | Previous | Next | Full Screen | Tutorial | Lab Values | Notes | Calculator | Reverse Color | Text Zoom | Settings

EM develops when circulating pathogens are phagocytosed by peripheral mononuclear cells and are brought to the epidermis, where DNA

Exhibit Display

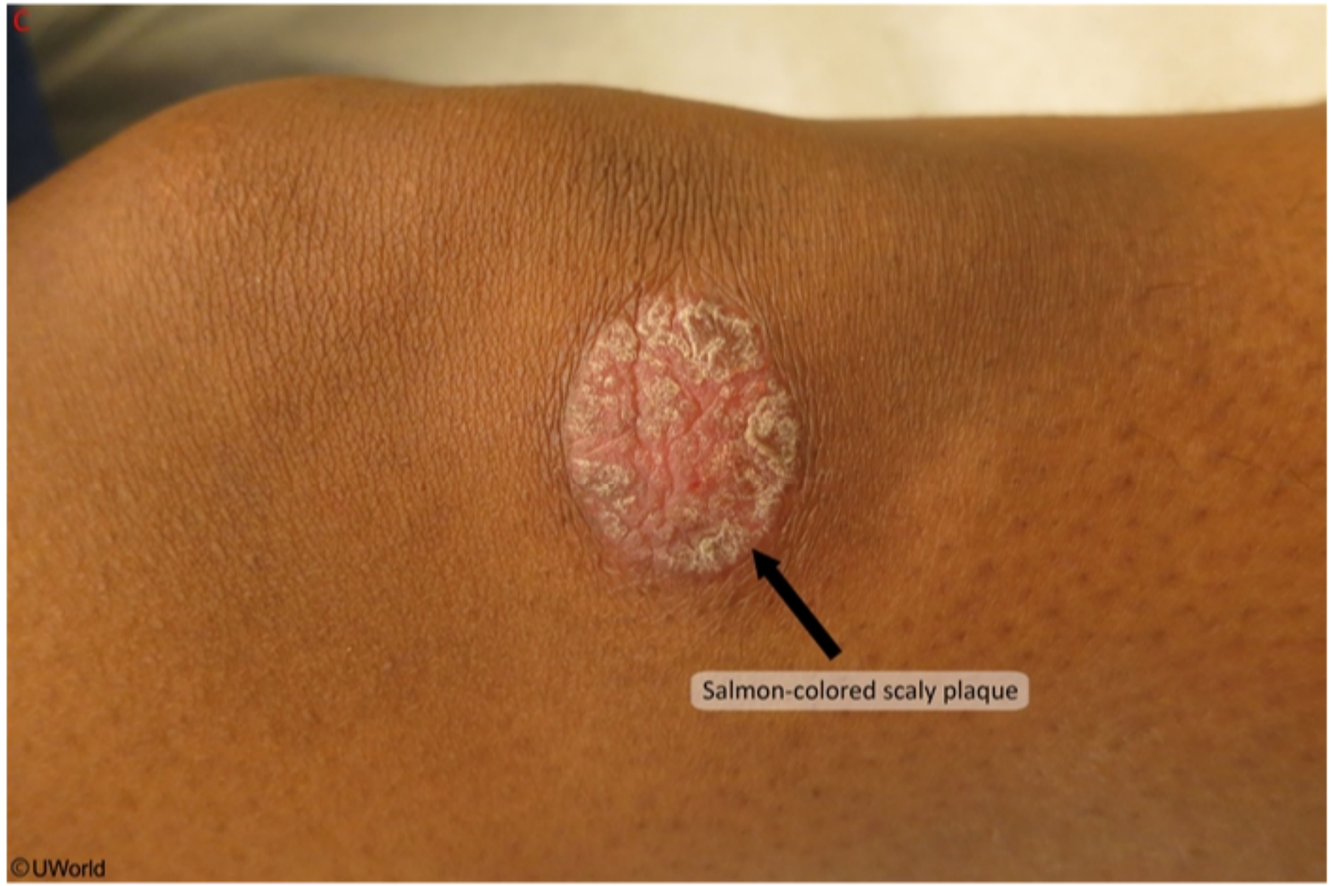

Zoom In | Zoom Out | Reset | Add To New Card | Existing Card

Block Time Remaining: 00:03:07
TUTOR

7 | Feedback | Suspend | End Block

Settings

11
12
13
14
15
16
17
18
19
20
21
22
23
24
25
26
27
28
29
30
31
32
33
34
35
36
37
38
39
40

Item 40 of 40
Question Id: 15695

Mark | Previous | Next | Full Screen | Tutorial | Lab Values | Notes | Calculator | Reverse Color | Text Zoom | Settings

EM develops when circulating pathogens are phagocytosed by peripheral mononuclear cells and are brought to the epidermis, where DNA

Exhibit Display

Zoom In | Zoom Out | Reset | Add To New Card | Existing Card

Block Time Remaining: 00:03:07
TUTOR

7 | Feedback | Suspend | End Block

Settings

11
12
13
14
15
16
17
18
19
20
21
22
23
24
25
26
27
28
29
30
31
32
33
34
35
36
37
38
39
40

Item 40 of 40
Question Id: 15695

Mark | Previous | Next | Full Screen | Tutorial | Lab Values | Notes | Calculator | Reverse Color | Text Zoom | Settings

EM develops when circulating pathogens are phagocytosed by peripheral mononuclear cells and are brought to the epidermis, where DNA

Exhibit Display

Zoom In | Zoom Out | Reset | Add To New Card | Existing Card

Block Time Remaining: 00:03:07
TUTOR

7 | Feedback | Suspend | End Block

Settings

1
2
3
4
5

Item 1 of 5
Question Id: 2065

Mark | Previous | Next | Full Screen | Tutorial | Lab Values | Notes | Calculator | Reverse Color | Text Zoom | Settings

A 52-year-old woman comes to the office with a 2-month history of oral lesions that cause pain with chewing and swallowing food. The patient did not seek treatment as she thought they would "go away on their own," but the lesions have persisted. On examination, there are erosions of the buccal and gingival mucosa as shown in the image below. There are several flaccid bullae with erosions scattered over her trunk. The blisters spread laterally with pressure, and traction on seemingly uninvolved skin produces blistering. Autoantibodies directed against which of the following structures are most likely responsible for this process?

Block Time Remaining: 00:00:01
TUTOR

8 | Feedback | Suspend | End Block

Settings

1
2
3
4
5

Item 1 of 5
Question Id: 2065

Mark | Previous | Next | Full Screen | Tutorial | Lab Values | Notes | Calculator | Reverse Color | Text Zoom | Settings

A. Basement membrane

B. Connexin proteins

C. Desmosomes

D. Hemidesmosomes

E. Tissue transglutaminase

Submit

Block Time Remaining: 00:00:03
TUTOR

8 | Feedback | Suspend | End Block

Settings

1
2
3
4
5

Item 1 of 5
Question Id: 2065

Mark | Previous | Next | Full Screen | Tutorial | Lab Values | Notes | Calculator | Reverse Color | Text Zoom | Settings

A. Basement membrane (2%)

B. Connexin proteins (1%)

✓ C. Desmosomes (75%)

D. Hemidesmosomes (19%)

E. Tissue transglutaminase (1%)

Omitted
Correct answer

75%
Answered correctly

05 secs
Time Spent

06/27/2020
Last Updated

Block Time Remaining: 00:00:05
TUTOR

8 | Feedback | Suspend | End Block

Explanation

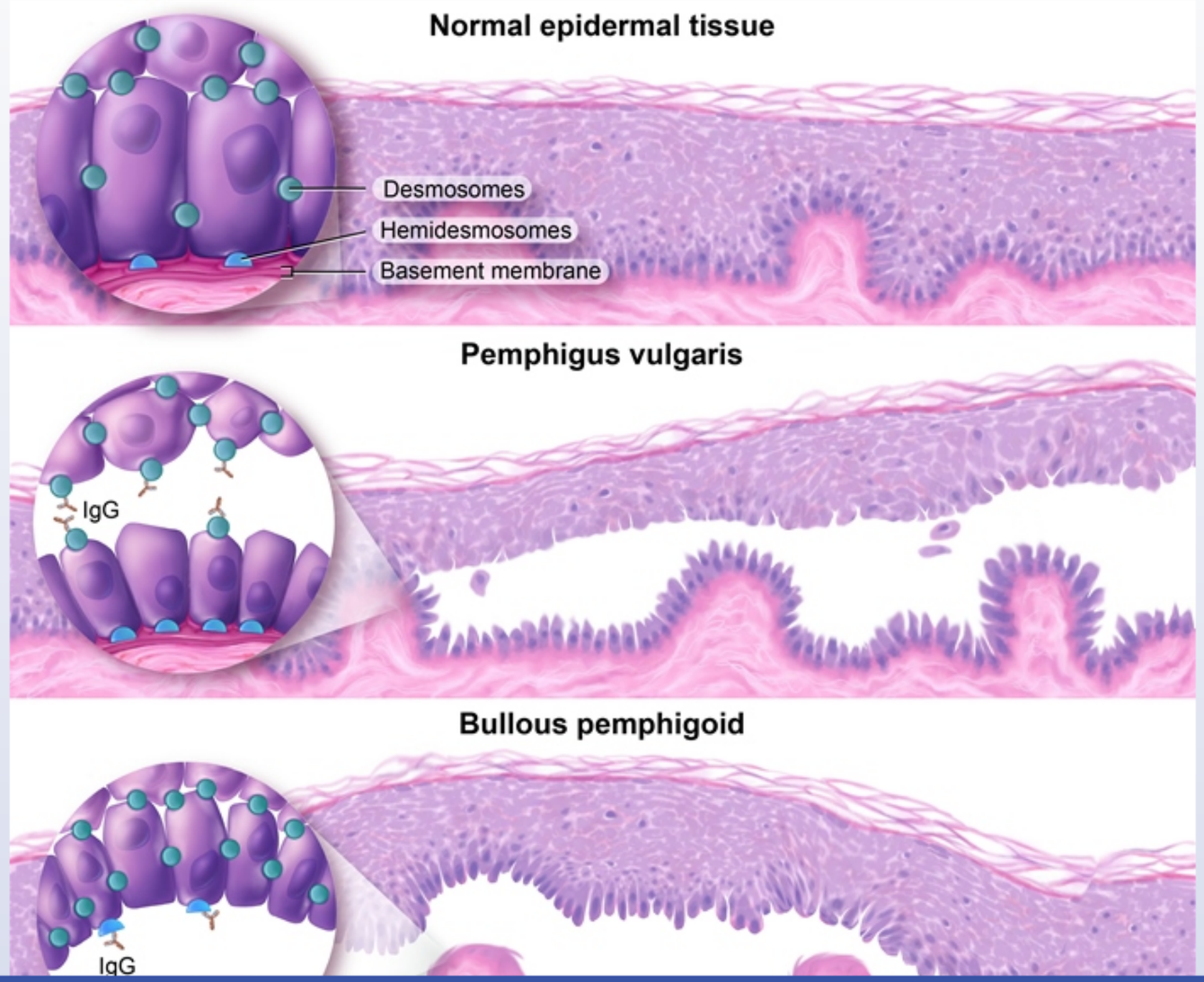

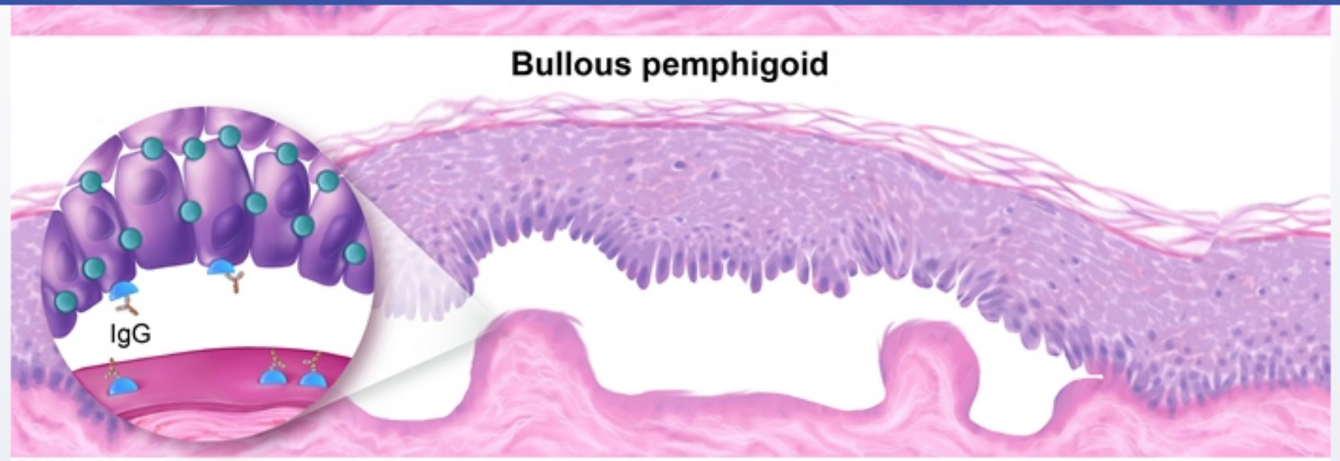

©UWorld

This patient has **pemphigus vulgaris** (PV), an autoimmune bullous disease characterized by painful flaccid bullae and erosions of the skin and mucosal membranes. Any mucosal site can be involved, but the oral mucosa is the most common. The bullae are structurally weak and often rupture prior to presentation, with only erosions remaining. The bullae spread laterally when pressure is applied on top (Asboe-Hansen sign), and new blisters may form with gentle traction or rubbing (Nikolsky sign).

The underlying pathophysiology of PV involves autoantibodies directed against **desmosomes**, specifically **desmogleins** 1 and 3, which disrupt cohesion of keratinocytes. Biopsy of an active PV lesion will show **intraepithelial cleavage** with detached keratinocytes (acantholysis), retained keratinocytes along the basement membrane, and an eosinophilic inflammatory infiltrate. Direct immunofluorescence of unaffected skin adjacent to PV lesions will show epidermal intercellular IgG and C3 deposits. Circulating autoantibodies against desmoglein are present in many patients and can aid diagnosis.

(Choice A) Autoantibodies against cutaneous basement membrane proteins are characteristic of epidermolysis bullosa acquisita (forms tense acral bullae) and cicatricial pemphigoid (causes chronic conjunctivitis and scarring).

(Choice B) No known cutaneous diseases result from connexin autoimmunity, but connexin defects do underlie some specific forms of palmoplantar keratoderma or deafness-associated ichthyosis.

(Choice D) Autoantibodies against hemidesmosomal proteins cause bullous pemphigoid, in which the bullae are usually tense and remain intact

to PV lesions will show epidermal intercellular IgG and C3 deposits. Circulating autoantibodies against desmoglein are present in many patients and can aid diagnosis.

(Choice A) Autoantibodies against cutaneous basement membrane proteins are characteristic of epidermolysis bullosa acquisita (forms tense acral bullae) and cicatricial pemphigoid (causes chronic conjunctivitis and scarring).

(Choice B) No known cutaneous diseases result from connexin autoimmunity, but connexin defects do underlie some specific forms of palmoplantar keratoderma or deafness-associated ichthyosis.

(Choice D) Autoantibodies against hemidesmosomal proteins cause bullous pemphigoid, in which the bullae are usually tense and remain intact as the entire epidermis separates from the dermis (no intraepithelial cleavage). In addition, mucosal involvement is less common and Nikolsky sign is usually negative.

(Choice E) Autoantibodies against tissue transglutaminase result in dermatitis herpetiformis and celiac sprue.

Educational objective:
Pemphigus vulgaris is an autoimmune bullous disease characterized by autoantibodies directed against desmosomal proteins (eg, desmoglein). It presents with painful flaccid bullae and erosions affecting the skin and mucosal membranes. The bullae spread laterally with pressure and new blisters may form with gentle rubbing.

References

- Correlation of conventional and conformational anti-desmoglein antibodies with phenotypes and disease activities in patients with pemphigus vulgaris.
- Pemphigus vulgaris: recent advances in our understanding of its pathogenesis.

Pathology	Dermatology	Pemphigus vulgaris
Subject	System	Topic

Copyright © UWorld. All rights reserved.

Settings

1
2
3
4
5

Item 1 of 5
Question Id: 2065

Mark | Previous | Next | Full Screen | Tutorial | Lab Values | Notes | Calculator | Reverse Color | Text Zoom | Settings

Exhibit Display

Zoom In | Zoom Out | Reset | Add To New Card | Existing Card

Educational objective:

Block Time Remaining: 00:00:05
TUTOR

8 | Feedback | Suspend | End Block

Settings

1
2
3
4
5

Item 1 of 5
Question Id: 2065

Mark | Previous | Next | Full Screen | Tutorial | Lab Values | Notes | Calculator | Reverse Color | Text Zoom | Settings

new blisters may form with gentle traction or rubbing (Nikolsky sign).

Exhibit Display

Zoom In | Zoom Out | Reset | Add To New Card | Existing Card

Pathology | Dermatology | Pemphigus vulgaris

Block Time Remaining: 00:00:05
TUTOR

8 | Feedback | Suspend | End Block

Settings

1
2
3
4
5

Item 1 of 5
Question Id: 2065

Mark | Previous | Next | Full Screen | Tutorial | Lab Values | Notes | Calculator | Reverse Color | Text Zoom | Settings

new blisters may form with gentle traction or rubbing (Nikolsky sign).

Exhibit Display



Zoom In | Zoom Out | Reset | Add To New Card | Existing Card

Pathology Dermatology Pemphigus vulgaris

Block Time Remaining: 00:00:05
TUTOR

8 | Feedback | Suspend | End Block

Settings

1
2
3
4
5

Item 1 of 5
Question Id: 2065

Mark | Previous | Next | Full Screen | Tutorial | Lab Values | Notes | Calculator | Reverse Color | Text Zoom | Settings

new blisters may form with gentle traction or rubbing (Nikolsky sign).

Exhibit Display

Zoom In | Zoom Out | Reset | Add To New Card | Existing Card

Pathology Dermatology Pemphigus vulgaris

Block Time Remaining: 00:00:05
TUTOR

8 | Feedback | Suspend | End Block

A 56-year-old woman comes to the office with a pigmented lesion on her back. She first noted the lesion a year ago and says it has enlarged. Past medical history is unremarkable. The patient has worked as a forest service ranger for the last 30 years and has spent much of her time outdoors. On examination, there is a large, irregular, pigmented lesion on the upper back, as shown in the image below, as well as scattered patches of erythema and telangiectasias.

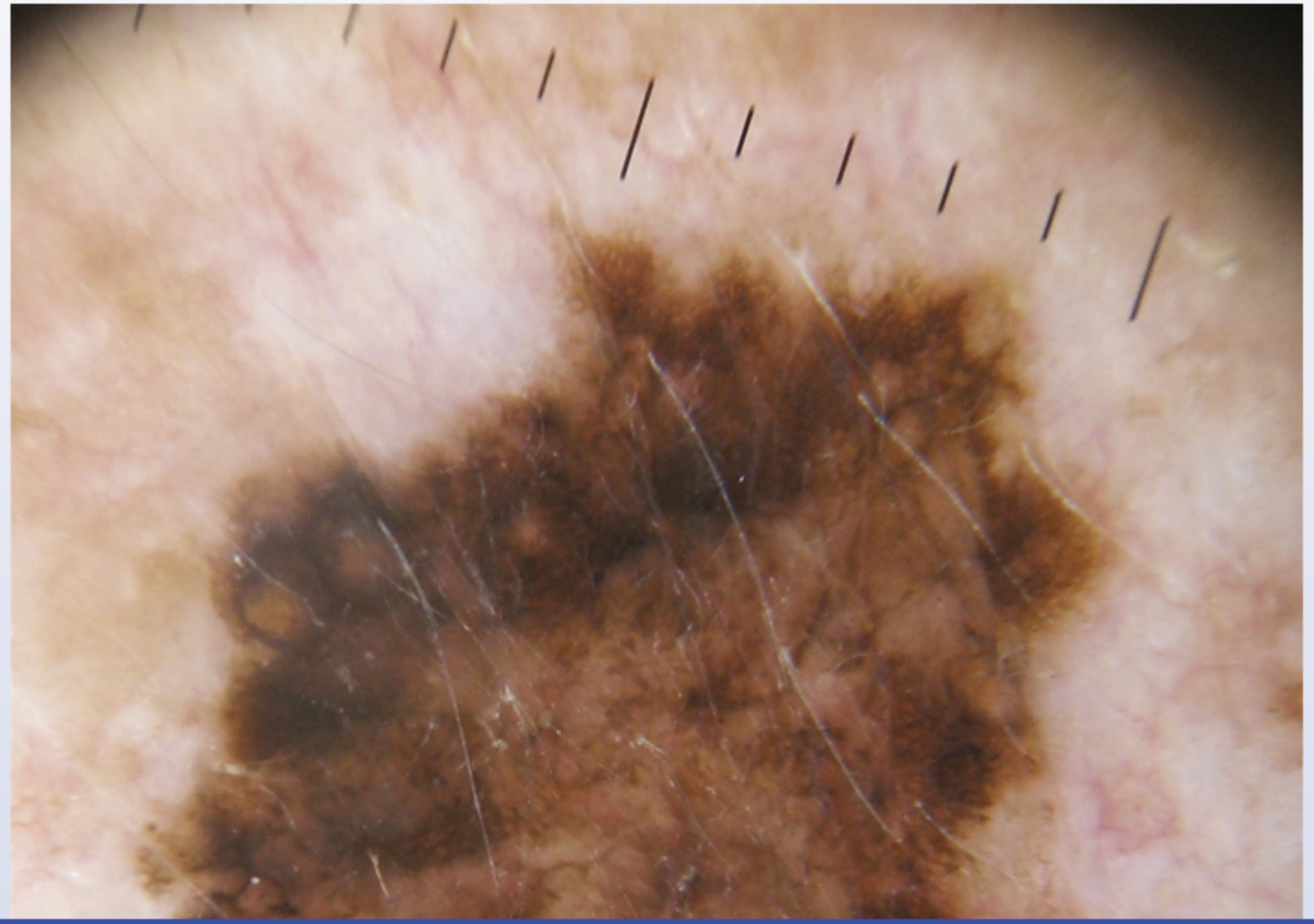

Settings

- 1
- 2
- 3
- 4
- 5

Item 2 of 5
Question Id: 1113

Mark | Previous | Next | Full Screen | Tutorial | Lab Values | Notes | Calculator | Reverse Color | Text Zoom | Settings

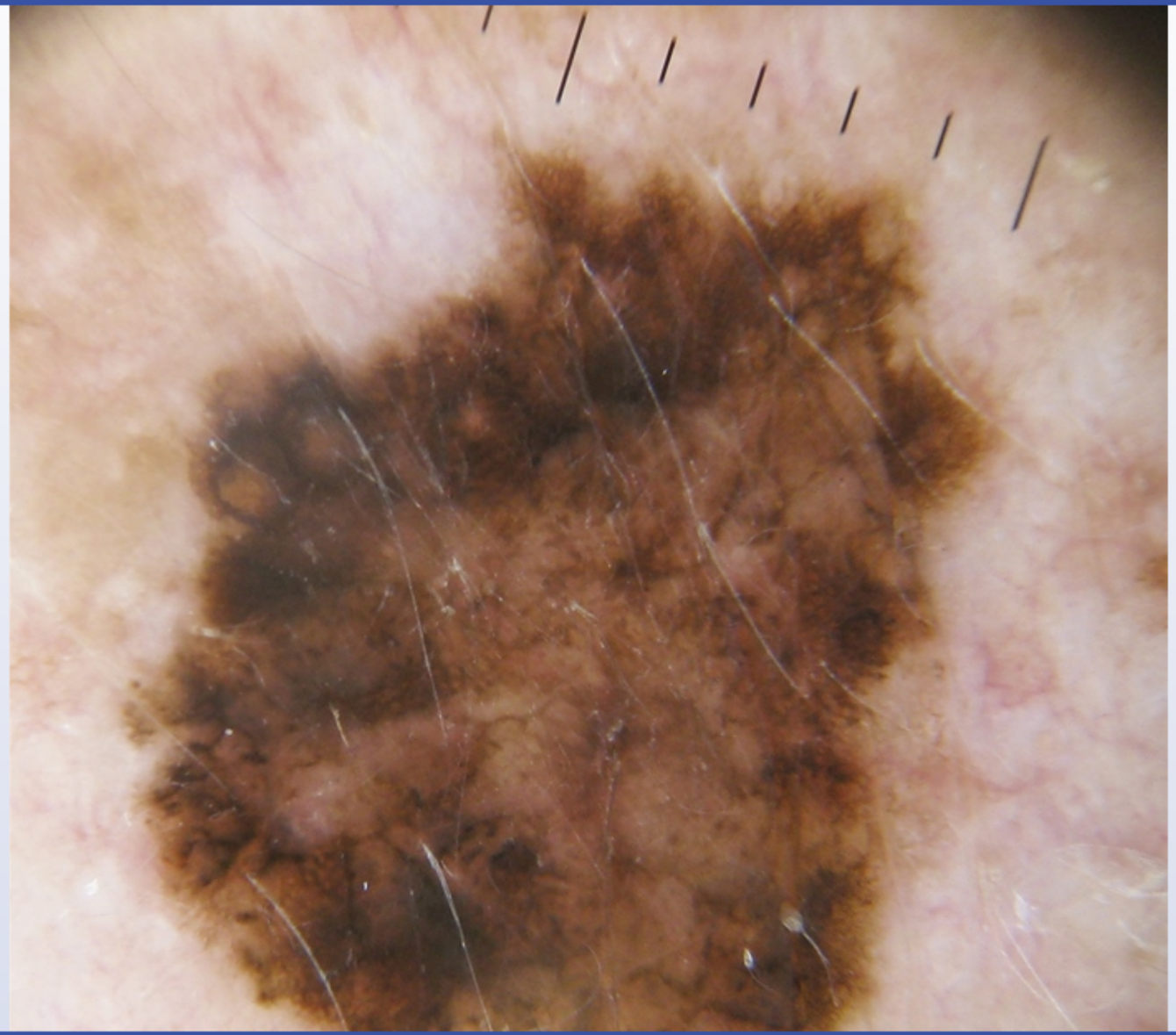

Block Time Remaining: 00:00:08
TUTOR

5 | Feedback | Suspend | End Block

Settings

1
2
3
4
5

Item 2 of 5
Question Id: 1113

Mark | Previous | Next | Full Screen | Tutorial | Lab Values | Notes | Calculator | Reverse Color | Text Zoom | Settings

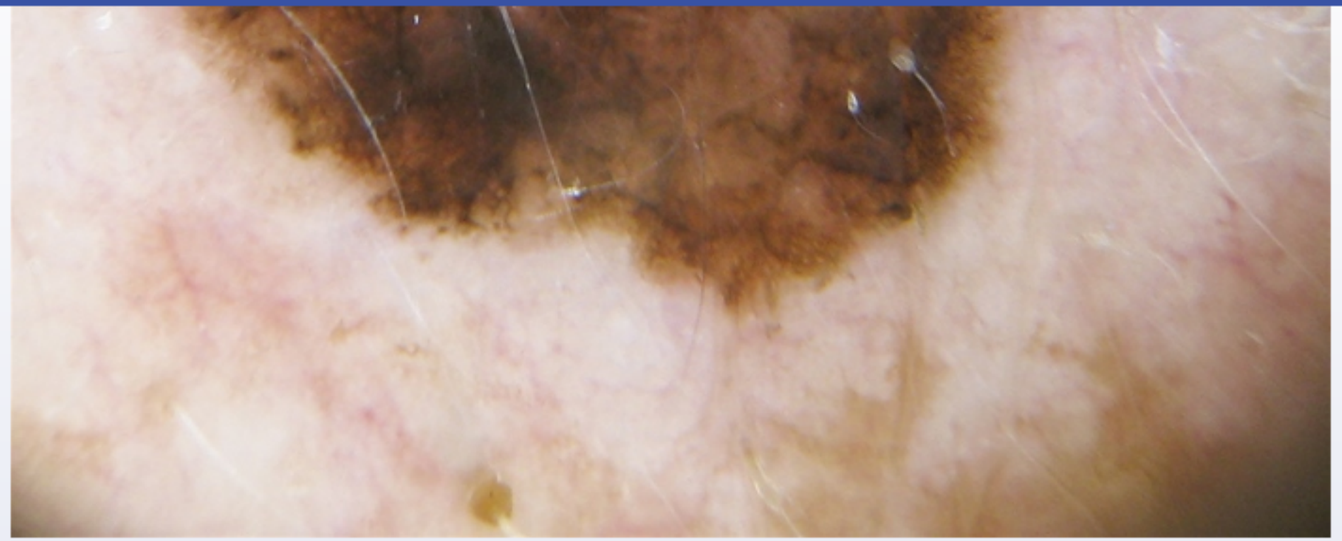

Excisional biopsy of the lesion shows malignant melanoma. Which of the following is associated with the highest risk of metastasis for this patient's lesion?

- A. Active horizontal growth
- B. Active vertical growth
- C. Dense lymphocyte infiltration
- D. Multinucleated giant melanocytes
- E. Prominent cellular atypia

Submit

Block Time Remaining: 00:00:10
TUTOR

5 | Feedback | Suspend | End Block

Settings

1
2
3
4
5

Item 2 of 5
Question Id: 1113

Mark | Previous | Next | Full Screen | Tutorial | Lab Values | Notes | Calculator | Reverse Color | Text Zoom | Settings

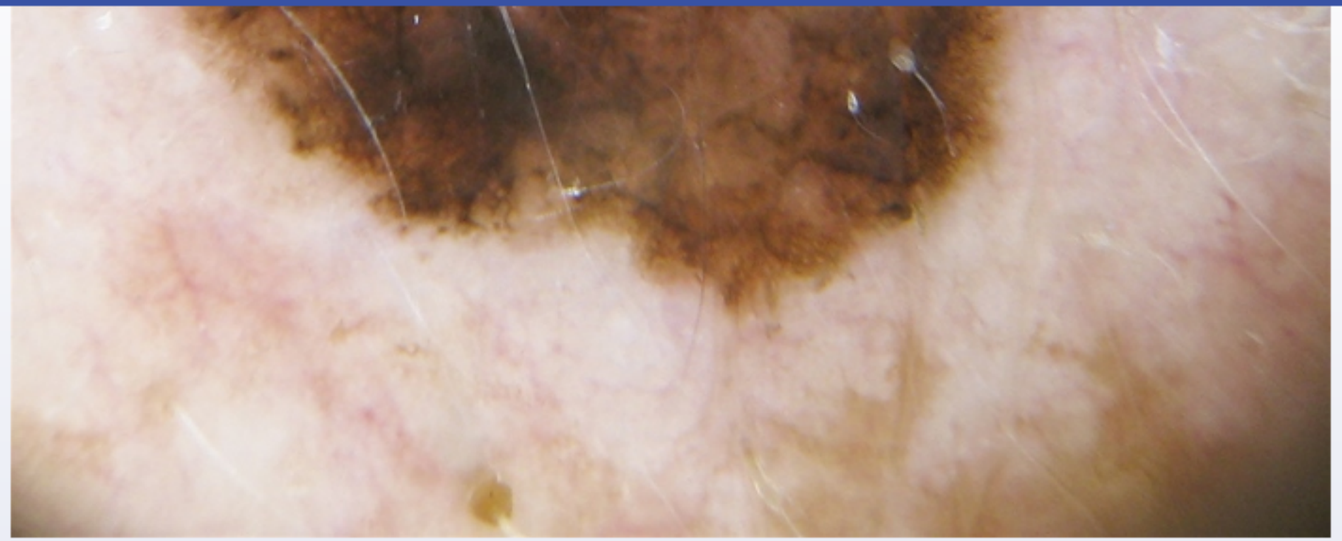

Excisional biopsy of the lesion shows malignant melanoma. Which of the following is associated with the highest risk of metastasis for this patient's lesion?

- A. Active horizontal growth (2%)
- ✓ B. Active vertical growth (89%)
- C. Dense lymphocyte infiltration (2%)
- D. Multinucleated giant melanocytes (1%)
- E. Prominent cellular atypia (4%)

Omitted
Correct answer

89%
Answered correctly

07 secs
Time Spent

01/19/2020
Last Updated

Block Time Remaining: 00:00:12
TUTOR

5 | Feedback | Suspend | End Block

Melanoma depth of invasion

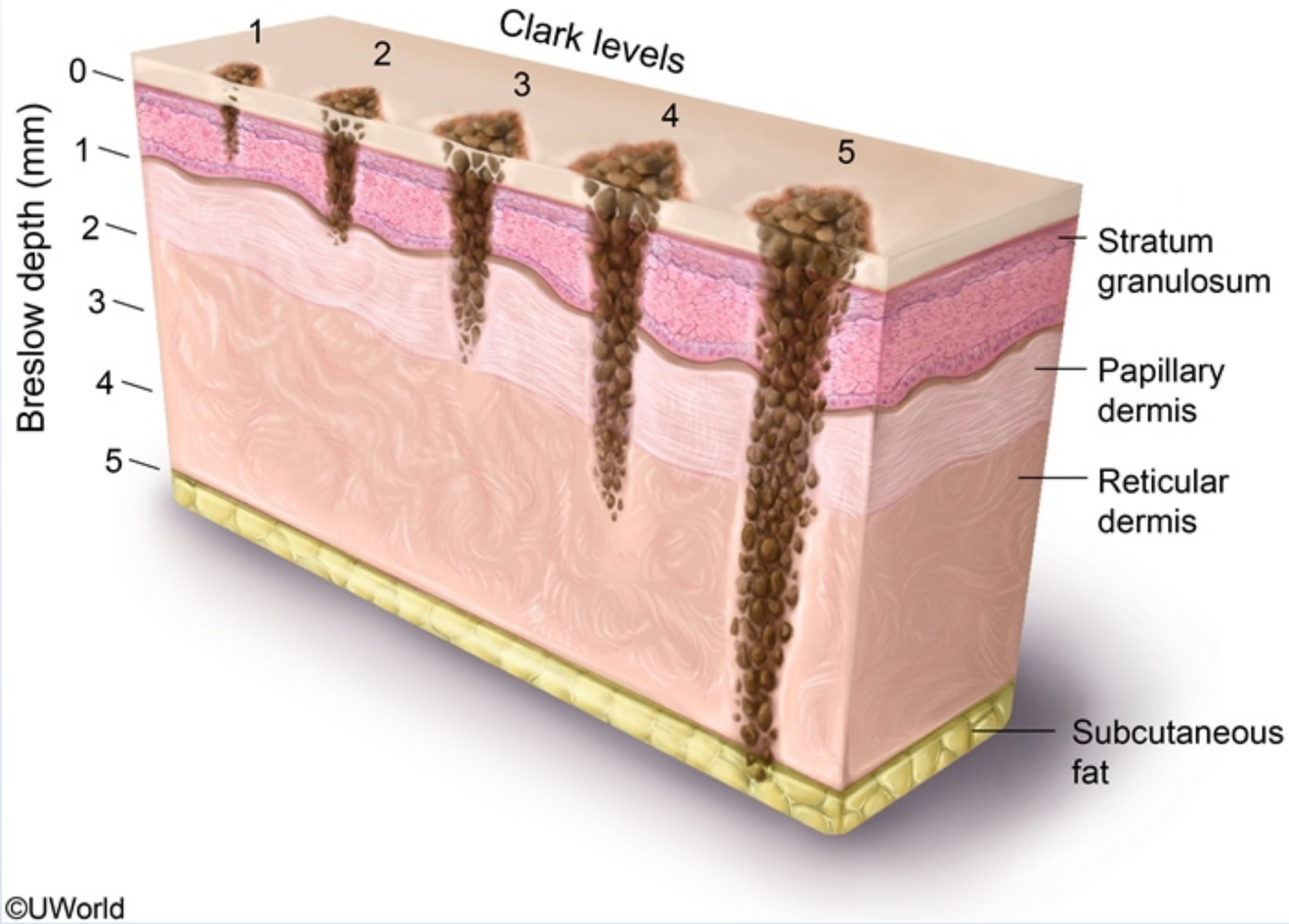

©UWorld

Malignant melanoma most often arises in the skin, although it may occur wherever there are pigmented cells, such as the eye and the mucosa of

©UWorld

Malignant melanoma most often arises in the skin, although it may occur wherever there are pigmented cells, such as the eye and the mucosa of the gastrointestinal tract. Sunlight exposure appears to be an important factor in the pathogenesis of dermal melanoma, as are hereditary factors and a history of preexistent dysplastic nevi. Light-skinned individuals are at greatest risk.

On gross inspection, melanomas are characterized by **a**symmetric shape, irregular or jagged **b**order, variability of **c**olor (brown, black, red, blue, or unpigmented), **d**iameter >0.5-1 cm, and **e**volution in size and appearance over time (**ABCDE criteria**). Histologically, melanoma cells congregate in poorly formed nests and are large with irregular nuclei, clumped chromatin, and prominent nucleoli. In early development, many melanomas exhibit a radial growth phase. This superficial, horizontal growth within the epidermis and superficial dermis carries a very low risk of metastatic spread **(Choice A)**. In contrast, melanomas in the **vertical growth phase** contain atypical, immature cells that travel downward into the deeper dermal layers, **increasing metastatic risk**. Vertical growth often corresponds to a palpable nodularity of the lesion. The **Breslow depth** (distance from the epidermal granular cell layer to the deepest visible melanoma cells) is the most important prognostic indicator in malignant melanoma.

(Choice C) A dense lymphocytic infiltration of the tumor suggests a robust immune response and is thought to improve prognosis.

(Choice D) Multinucleated giant melanocytes are a characteristic finding in lentigo maligna melanoma. Lentigo maligna are common pigmented lesions in elderly patients and are considered by some experts to be a type of melanoma in-situ. When melanoma develops in lentigo maligna, the prognosis is similar to other melanomas of the same stage.

(Choice E) Prominent cellular atypia is a classic finding of malignant melanoma, but it is not considered the most important risk factor for metastatic disease.

Educational objective:
Melanoma often has an early horizontal growth phase with low metastatic potential followed by a nodular, vertical growth phase with a significantly increased risk of metastasis. Depth of invasion (Breslow thickness) is the most important prognostic indicator in malignant melanoma.

References

- Thin melanoma.

Settings

1
2
3
4
5

Item 2 of 5
Question Id: 1113

Mark | Previous | Next | Full Screen | Tutorial | Lab Values | Notes | Calculator | Reverse Color | Text Zoom | Settings

Malignant melanoma most often arises in the skin, although it may occur wherever there are pigmented cells, such as the eye and the mucosa of

Exhibit Display

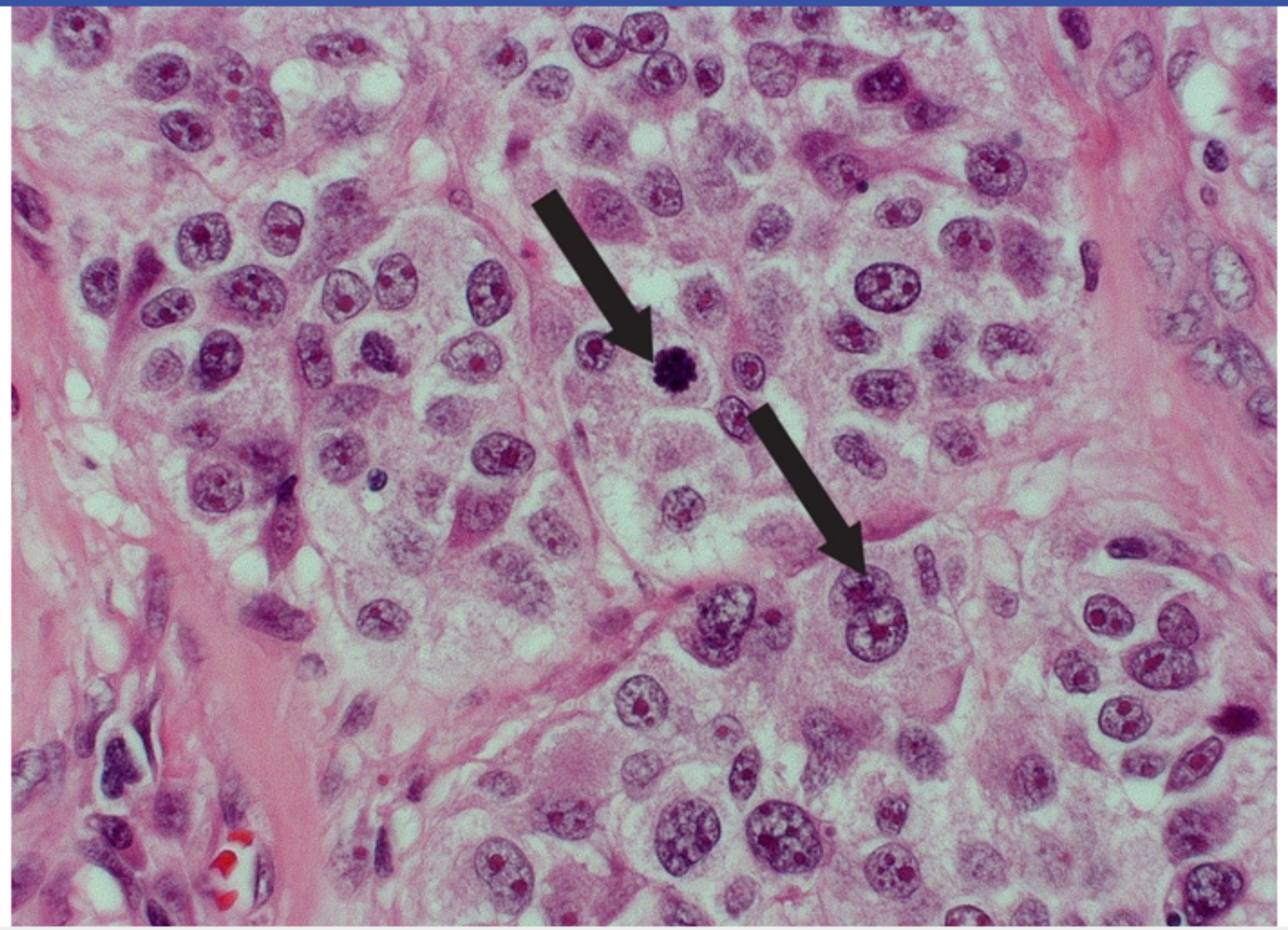

Zoom In | Zoom Out | Reset | Add To New Card | Existing Card

Subject System Topic

Block Time Remaining: 00:00:12
TUTOR

5 | Feedback | Suspend | End Block

Settings

1
2
3
4
5

Item 2 of 5
Question Id: 1113

Mark | Previous | Next | Full Screen | Tutorial | Lab Values | Notes | Calculator | Reverse Color | Text Zoom | Settings

Malignant melanoma most often arises in the skin, although it may occur wherever there are pigmented cells, such as the eye and the mucosa of

Exhibit Display

Zoom In | Zoom Out | Reset | Add To New Card | Existing Card

Subject System Topic

Block Time Remaining: 00:00:12
TUTOR

5 | Feedback | Suspend | End Block

Settings

1
2
3
4
5

Item 3 of 5
Question Id: 936

Mark | Previous | Next | Full Screen | Tutorial | Lab Values | Notes | Calculator | Reverse Color | Text Zoom | Settings

A 31-year-old woman comes to the physician with a velvety skin rash in her axilla, as shown in the image below.

Block Time Remaining: 00:00:13
TUTOR

2 | Feedback | Suspend | End Block

Settings

1
2
3
4
5

Item 3 of 5
Question Id: 936

Mark | Previous | Next | Full Screen | Tutorial | Lab Values | Notes | Calculator | Reverse Color | Text Zoom | Settings

Which of the following is the most likely cause of this patient's condition?

A. Calcitonin hypersecretion
B. Insulin resistance
C. Serotonin hypersecretion
D. Testosterone unresponsiveness
E. Vitamin D resistance

Submit

Block Time Remaining: 00:00:16
TUTOR

2 | Feedback | Suspend | End Block

Settings

1
2
3
4
5

Item 3 of 5
Question Id: 936

Mark | Previous | Next | Full Screen | Tutorial | Lab Values | Notes | Calculator | Reverse Color | Text Zoom | Settings

Which of the following is the most likely cause of this patient's condition?

- A. Calcitonin hypersecretion (1%)
- ✓ B. Insulin resistance (94%)
- C. Serotonin hypersecretion (2%)
- D. Testosterone unresponsiveness (0%)
- E. Vitamin D resistance (0%)

Omitted
Correct answer

94%
Answered correctly

05 secs
Time Spent

04/23/2020
Last Updated

Block Time Remaining: 00:00:17
TUTOR

2 | Feedback | Suspend | End Block

This image shows the typical presentation of acanthosis nigricans (AN), which occurs most commonly in flexural areas. The most common locations are the axillae, posterior neck, and groin, but it may appear on other areas of the body such as the palms, soles, and oral mucosa & vermilion border. On physical examination, these lesions appear as hyperkeratotic, hyperpigmented plaques with a classic "velvety" texture. Skin tags (acrochordons) are pedunculated outgrowths of normal skin that are commonly present on regions affected by acanthosis nigricans.

AN is associated with a number of diseases. Depending on the underlying condition, it is divided into benign and malignant forms.

1. Benign AN is commonly associated with insulin resistance. Increased levels of insulin and insulin-like growth factors stimulate epidermal and dermal proliferation.
2. Malignant AN is associated with underlying neoplasms, especially of the gastrointestinal and genitourinary tracts. The sudden appearance of such skin changes in middle-aged or elderly patients is suggestive of underlying malignancy. Gastric adenocarcinoma is the most common cause of malignant AN.

(Choices A and E) Hypersecretion of calcitonin (as in medullary thyroid cancer) and vitamin D resistance are not associated with AN.

(Choice C) Hypersecretion of serotonin can occur with carcinoid tumors, including the gastrointestinal variety. However, excess serotonin itself does not cause AN.

(Choice D) Testosterone unresponsiveness (androgen insensitivity syndrome, testicular feminization syndrome) develops due to a defect in testosterone receptors in peripheral tissues. Such patients are phenotypic females who present with primary amenorrhea. The uterus is absent and the vagina ends as a blind pouch, but breast development is normal due to the production of estrogen by aromatase.

Educational objective:
Acanthosis nigricans presents with thickening and hyperpigmentation of skin in the flexural areas. The lesions have a classic "velvety" texture. Acanthosis nigricans is commonly associated with insulin-resistant states (eg, diabetes mellitus, acromegaly, obesity) and gastrointestinal malignancies.

Pathology	Dermatology	Acanthosis nigricans
Subject	System	Topic

locations are the axillae, posterior neck, and groin, but it may appear on other areas of the body such as the palms, soles, and oral mucosa & vermilion border. On physical examination, these lesions appear as hyperkeratotic, hyperpigmented plaques with a classic "velvety" texture. Skin tags (acrochordons) are pedunculated outgrowths of normal skin that are commonly present on regions affected by acanthosis nigricans.

AN is associated with a number of diseases. Depending on the underlying condition, it is divided into benign and malignant forms.

1. Benign AN is commonly associated with insulin resistance. Increased levels of insulin and insulin-like growth factors stimulate epidermal and dermal proliferation.
2. Malignant AN is associated with underlying neoplasms, especially of the gastrointestinal and genitourinary tracts. The sudden appearance of such skin changes in middle-aged or elderly patients is suggestive of underlying malignancy. Gastric adenocarcinoma is the most common cause of malignant AN.

(Choices A and E) Hypersecretion of calcitonin (as in medullary thyroid cancer) and vitamin D resistance are not associated with AN.

(Choice C) Hypersecretion of serotonin can occur with carcinoid tumors, including the gastrointestinal variety. However, excess serotonin itself does not cause AN.

(Choice D) Testosterone unresponsiveness (androgen insensitivity syndrome, testicular feminization syndrome) develops due to a defect in testosterone receptors in peripheral tissues. Such patients are phenotypic females who present with primary amenorrhea. The uterus is absent and the vagina ends as a blind pouch, but breast development is normal due to the production of estrogen by aromatase.

Educational objective:
Acanthosis nigricans presents with thickening and hyperpigmentation of skin in the flexural areas. The lesions have a classic "velvety" texture. Acanthosis nigricans is commonly associated with insulin-resistant states (eg, diabetes mellitus, acromegaly, obesity) and gastrointestinal malignancies.

Pathology	Dermatology	Acanthosis nigricans
Subject	System	Topic

Copyright © UWorld. All rights reserved.

A 19-year-old man comes to the office due to a painful subcutaneous forearm nodule. Two weeks earlier, he received a laceration on his left forearm while playing soccer and had sutures placed. The lesion is biopsied, and results are shown in the image below:

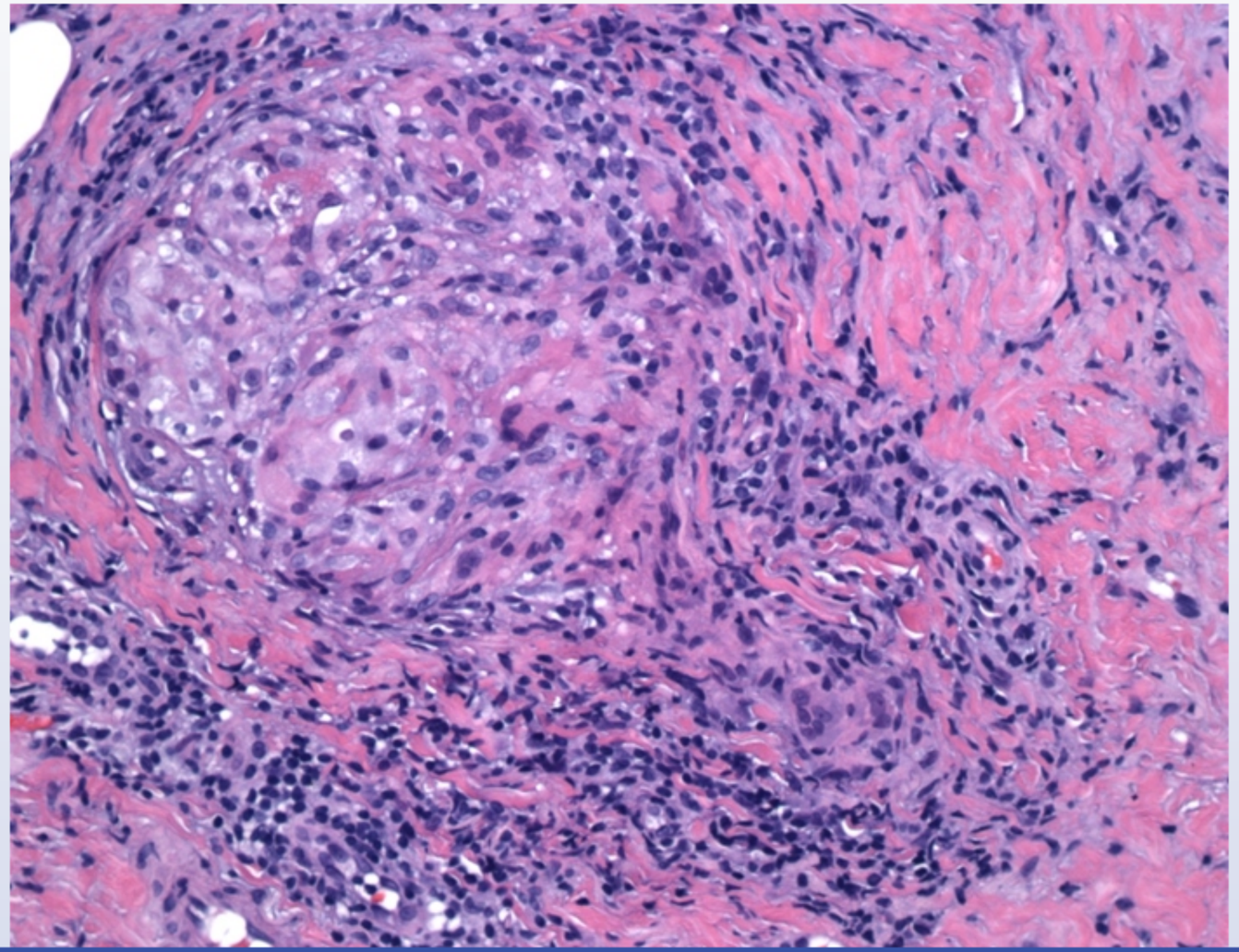

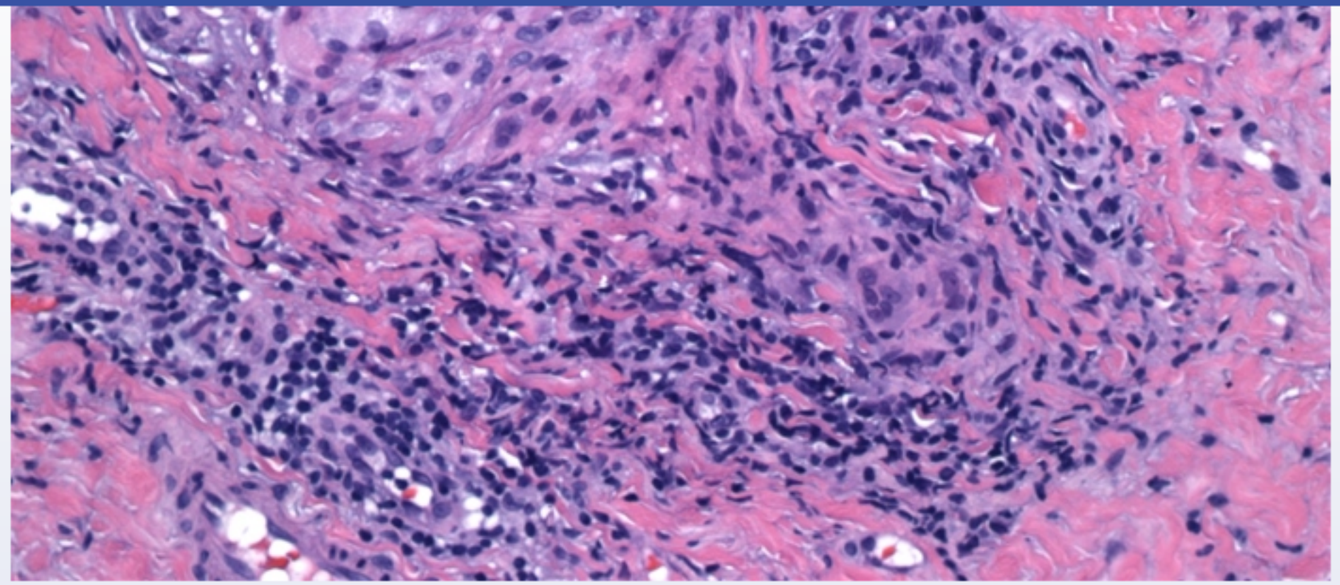

Which of the following is most likely responsible for this patient's condition?

- A. Excess granulation tissue formation
- B. Malignant transformation
- C. Normal wound remodeling
- D. Persistent neutrophil activity
- E. Reaction to a foreign body

Submit

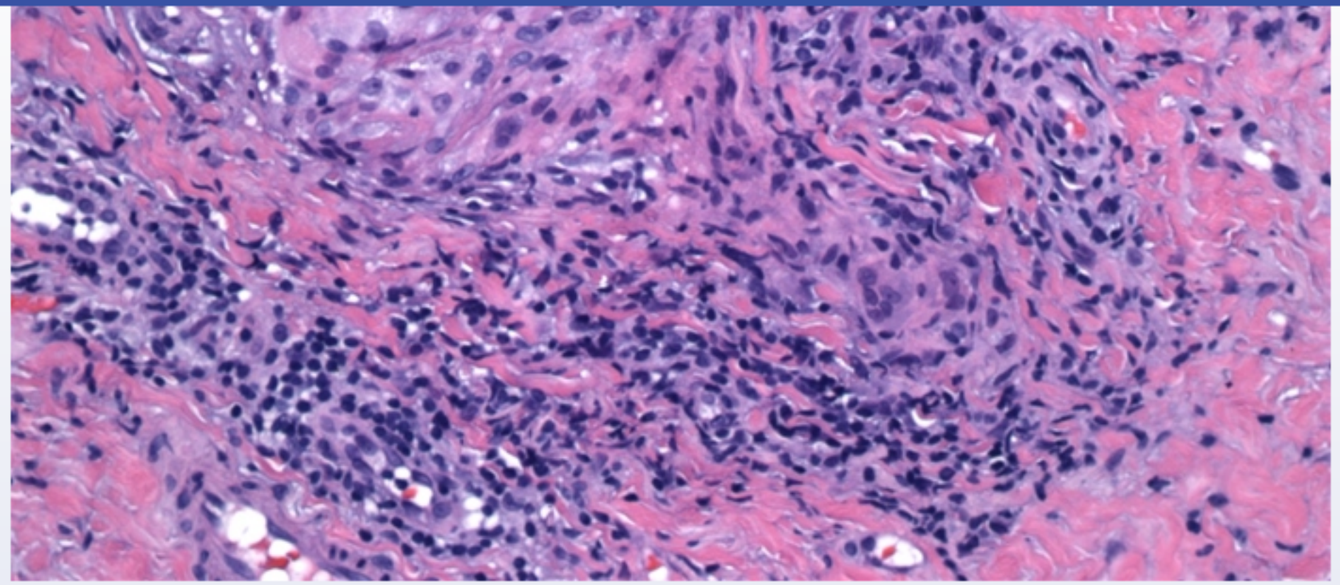

Which of the following is most likely responsible for this patient's condition?

A. Excess granulation tissue formation (24%)

B. Malignant transformation (0%)

C. Normal wound remodeling (3%)

D. Persistent neutrophil activity (10%)

✓ E. Reaction to a foreign body (60%)

Omitted
Correct answer

60%
Answered correctly

04 secs
Time Spent

07/01/2020
Last Updated

Granulomas

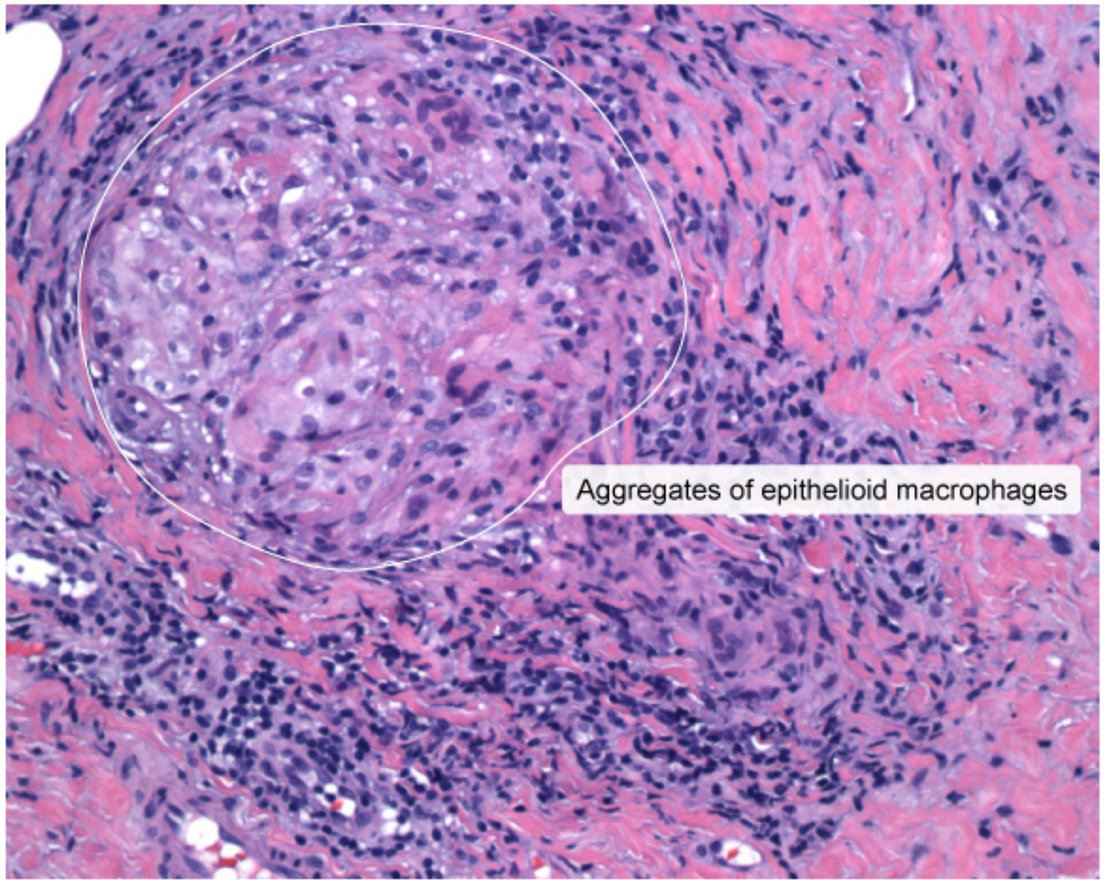

©UWorld

Foreign bodies (eg, retained sutures) can elicit a granulomatous response, seen clinically as a tender, erythematous, brown or purple papule, nodule, or plaque. **Granulomas** are characterized microscopically by aggregates of **activated macrophages** that assume an epithelioid appearance. They are often surrounded by a rim of lymphocytes that synthesize the cytokines responsible for continued macrophage activation.

Foreign bodies (eg, retained sutures) can elicit a granulomatous response, seen clinically as a tender, erythematous, brown or purple papule, nodule, or plaque. **Granulomas** are characterized microscopically by aggregates of **activated macrophages** that assume an epithelioid appearance. They are often surrounded by a rim of lymphocytes that synthesize the cytokines responsible for continued macrophage activation. Multinucleated giant cells, derived from the fusion of several macrophages, can also be found in granulomas.

Granuloma formation is a complex process that occurs over several **days to weeks** in response to an antigen that cannot be eradicated by the usual immune mechanisms. Activated TH1 $CD4^+$ cells secrete interferon gamma, which activates macrophages. Macrophages in turn secrete tumor necrosis factor alpha, resulting in further macrophage maturation and formation of a granuloma, which **walls off** the offending agent. However, the agent is not always eradicated, as certain pathogens can be resistant to killing (eg, tuberculosis) and foreign substances may not be digestible by macrophages (eg, metal, glass).

(Choice A) Excess granulation tissue formation (hypergranulation) usually occurs in a wound left to heal by secondary intention. Light microscopy would show proliferation of fibroblasts, collagen deposition, and numerous capillaries.

(Choice B) Marjolin ulcer is an aggressive, ulcerating squamous cell carcinoma that presents in an area of previously traumatized, chronically inflamed, or scarred skin. Malignant transformation often occurs long after the initial trauma, usually >10 years later. Histology would show dysplastic keratinocytes and keratinization.

(Choice C) The remodeling phase of wound healing is characterized by fibrosis (scar formation) and starts the second week after injury. During this phase, active fibroblasts synthesize collagen, elastin, and other components of the connective tissue matrix.

(Choice D) The inflammatory phase of wound healing consists of the movement of neutrophils (within the first 24 hours) and macrophages (within 2-3 days) to the damaged area, with phagocytosis of necrotic debris and bacterial contaminants. Persistent neutrophil activity in a wound would result in an abscess and/or pus drainage rather than granuloma formation.

Educational objective:
Granulomatous inflammation is a form of chronic inflammation characterized by aggregates of activated macrophages that assume an epithelioid appearance. Persistent granulomatous inflammation with subsequent fibrosis can cause organ dysfunction, which is seen in a number of granulomatous diseases.

appearance. They are often surrounded by a rim of lymphocytes that synthesize the cytokines responsible for continued macrophage activation.

Exhibit Display

Granulation tissue

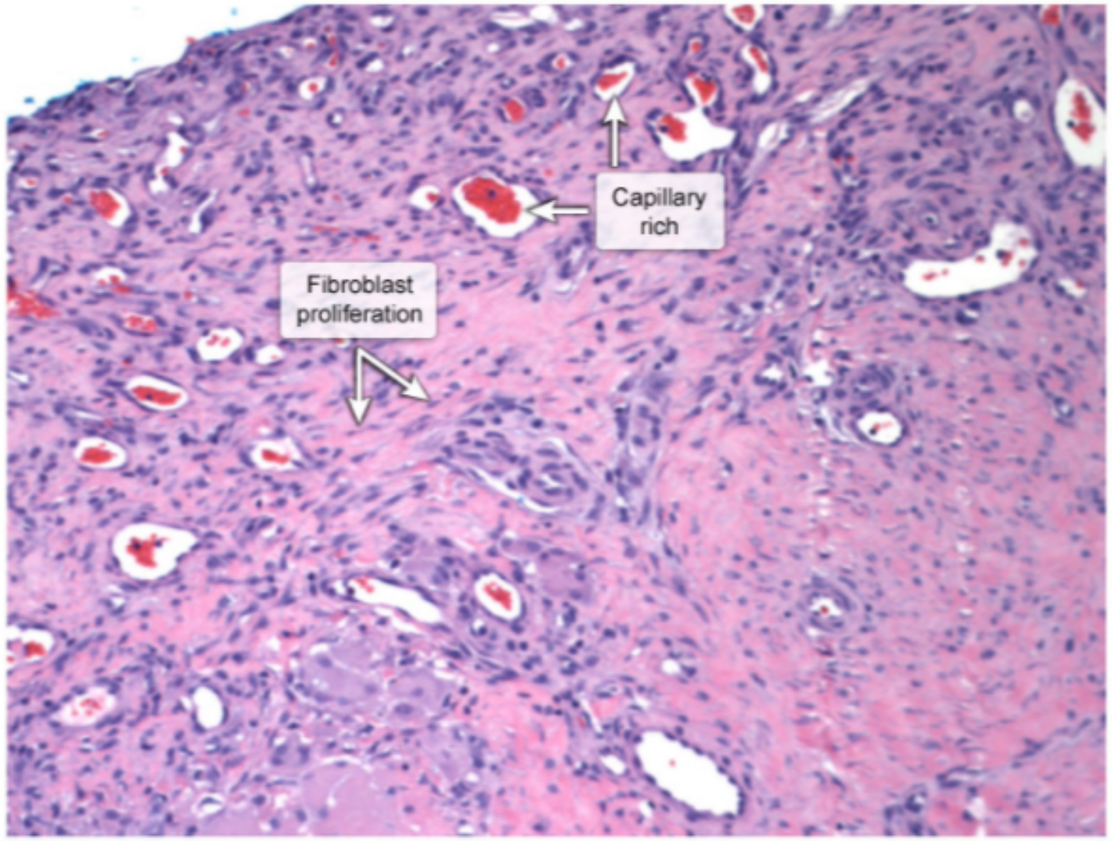

©UWorld

Zoom In | Zoom Out | Reset | Add To New Card | Existing Card

Subject System Topic

A 65-year-old man comes to the office due to 2 months of itching, occasional ulceration, and crusting of a skin lesion on his upper chest. A year ago, the patient was diagnosed with squamous cell carcinoma with perineural invasion at the site of the lesion. Surgical resection with clear margins was achieved, followed by adjuvant radiotherapy to the site. He reports no other symptoms. The patient's lesion is shown in the exhibit. If a biopsy is performed at the periphery of the lesion, which of the following histologic changes is most likely to be seen?

A. Full-thickness epidermal necrosis

B. Homogenization of dermal collagen bundles

C. Neutrophilic infiltrates and elongated dermal papillae

D. Perivascular collections of eosinophils

Submit

Settings

- 1
- 2
- 3
- 4
- 5

Item 5 of 5
Question Id: 18927

Mark | Previous | Next | Full Screen | Tutorial | Lab Values | Notes | Calculator | Reverse Color | Text Zoom | Settings

Exhibit Display

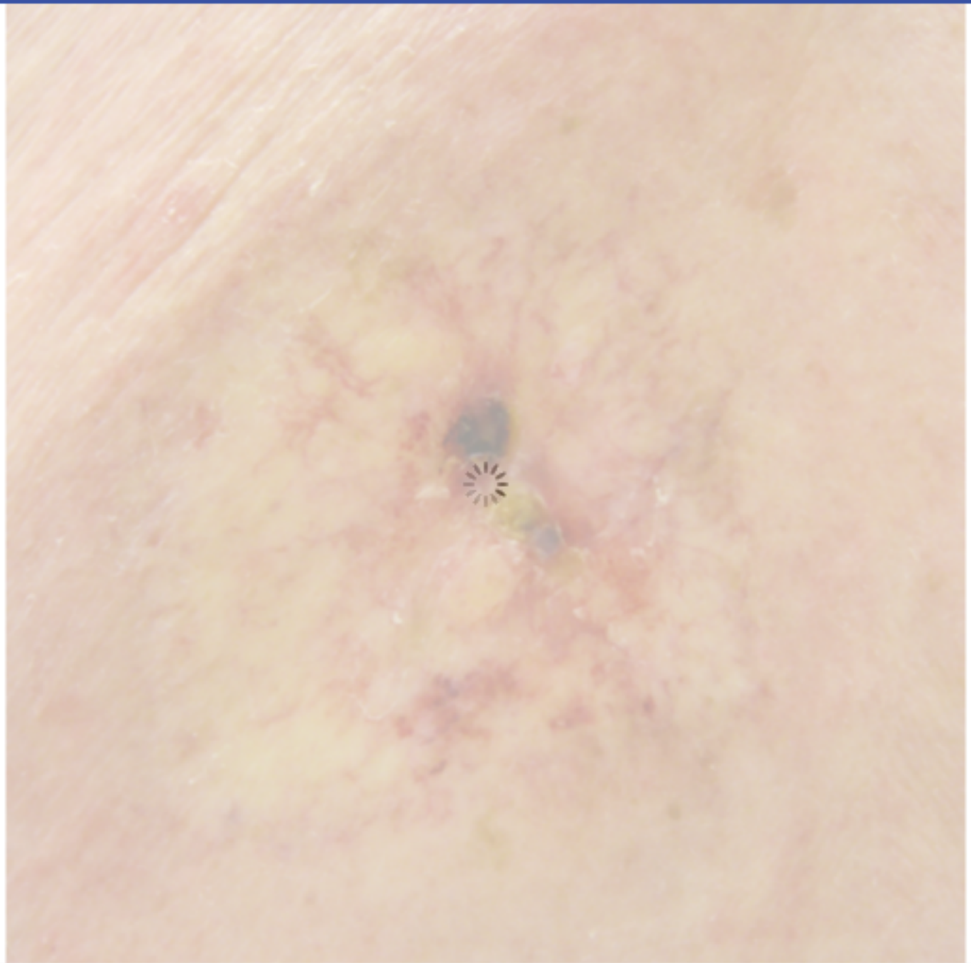

Zoom In | Zoom Out | Reset | Add To Flash Card

Block Time Remaining: 00:00:24
TUTOR

0 | Feedback | Suspend | End Block

A 65-year-old man comes to the office due to 2 months of itching, occasional ulceration, and crusting of a skin lesion on his upper chest. A year ago, the patient was diagnosed with squamous cell carcinoma with perineural invasion at the site of the lesion. Surgical resection with clear margins was achieved, followed by adjuvant radiotherapy to the site. He reports no other symptoms. The patient's lesion is shown in the exhibit. If a biopsy is performed at the periphery of the lesion, which of the following histologic changes is most likely to be seen?

A. Full-thickness epidermal necrosis (18%)

✓ B. Homogenization of dermal collagen bundles (47%)

C. Neutrophilic infiltrates and elongated dermal papillae (23%)

D. Perivascular collections of eosinophils (10%)

Omitted
Correct answer
B

47%
Answered correctly

06 secs
Time Spent

06/16/2020
Last Updated

Explanation

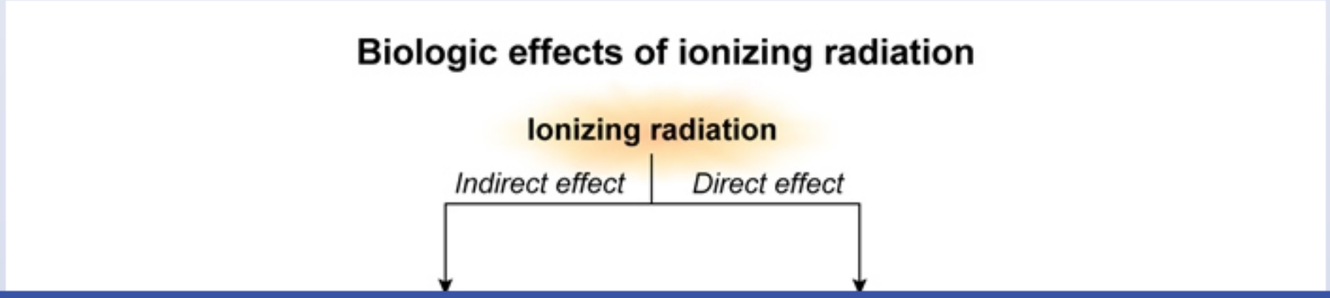

Biologic effects of ionizing radiation

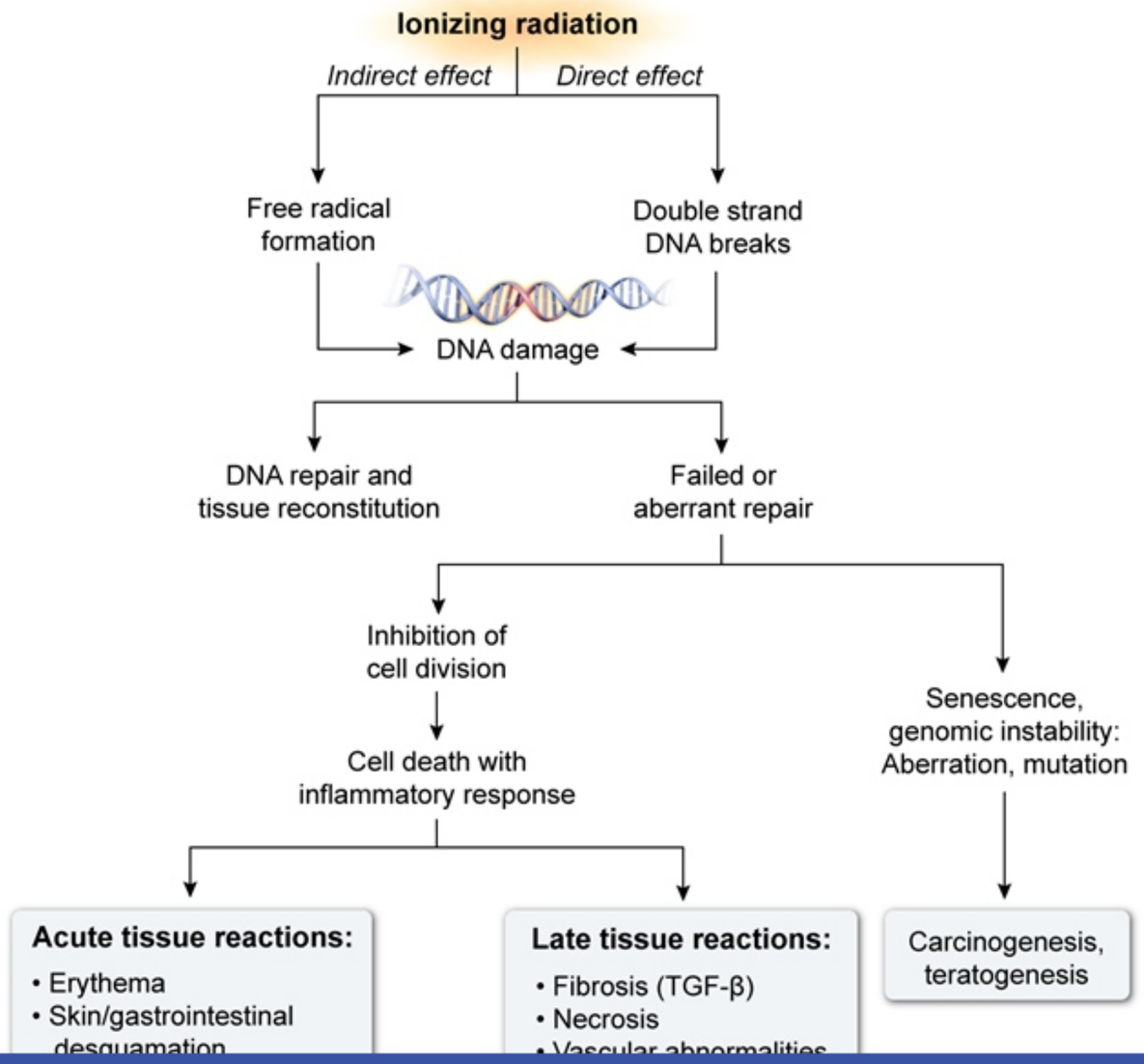

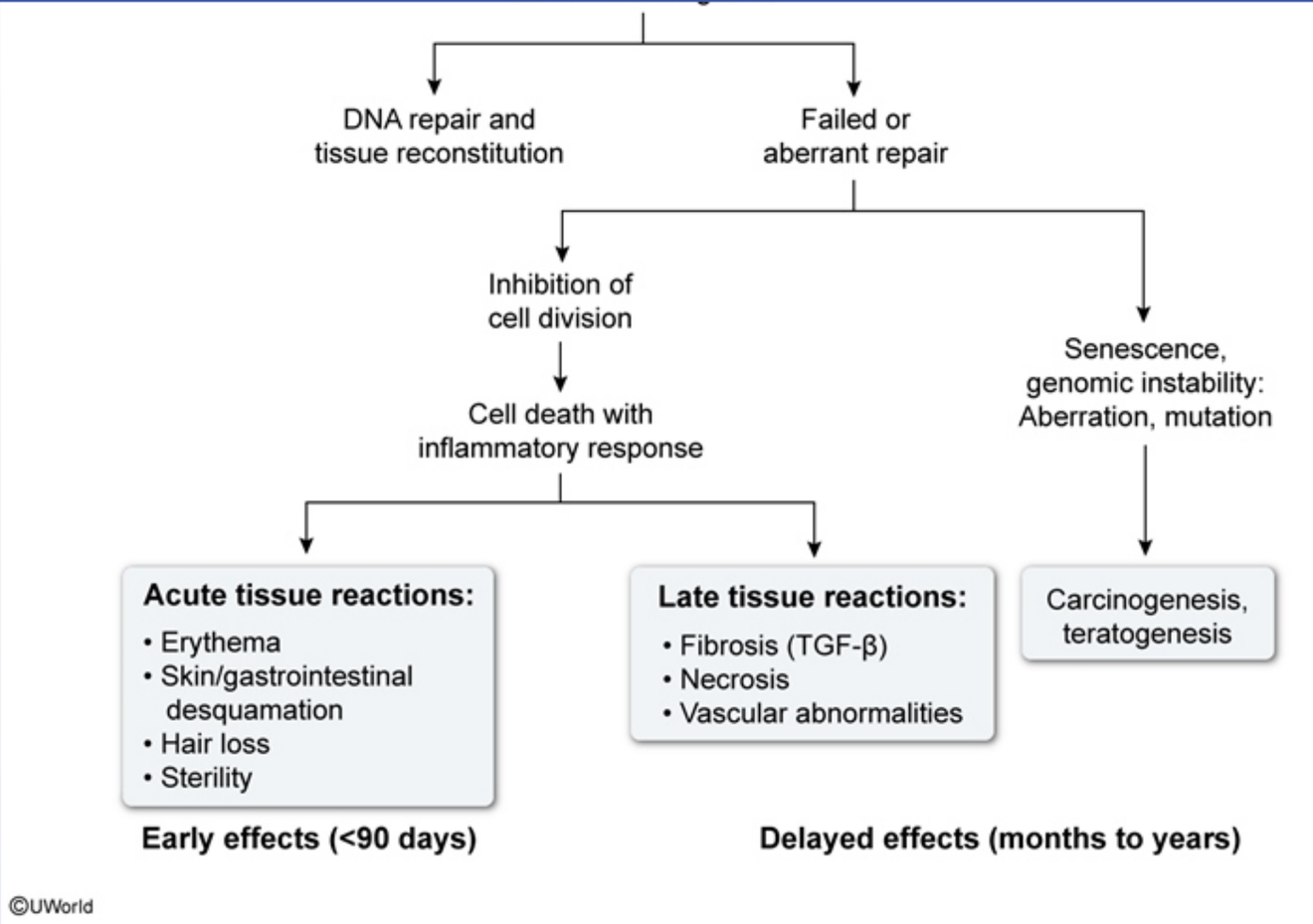

This patient has a persistent, itchy, ulcerating skin lesion with **hypopigmentation** and **telangiectasias** at a site of prior radiotherapy, consistent with **late-stage radiation dermatitis**. Radiotherapy can be used with excision in the treatment of high-risk, invasive skin cancer to kill remaining cancer cells and decrease recurrence risk. **Ionizing radiation** causes **apoptosis** of rapidly dividing cancer cells directly by inducing **DNA damage** and indirectly by generating **free radicals**.

However, all **rapidly dividing cells** in the area (eg, hair follicle stem cells, melanocytes, basal keratinocytes) treated by the radiation can be

However, all **rapidly dividing cells** in the area (eg, hair follicle stem cells, melanocytes, basal keratinocytes) treated by the radiation can be affected, initiating a series of characteristic skin changes:

- Acute (<90 days after radiotherapy):
  - Apoptosis of basal keratinocytes and epidermal edema
  - Dose-dependent effects ranging from erythema to desquamation (ie, skin peeling), superficial ulceration, and/or blistering
  - Pigment changes and loss of skin appendages (eg, hair follicles, sebaceous glands)
- Late (months to years after radiotherapy):
  - **Fibrosis**, characterized histologically by **homogenization of dermal collagen**, due to fibroblast activation by **transforming growth factor-beta** from damaged tissue and responding immune cells
  - Vascular damage, resulting in chronic hypoxia and ulceration
  - Abnormal, dilated microvasculature (ie, telangiectasias)

(Choice A) Full-thickness epidermal necrosis with subepidermal bullae is characteristic of Stevens-Johnson syndrome/toxic epidermal necrolysis. This systemic immune reaction to certain medications (eg, allopurinol, carbamazepine, sulfonamides) results in fever, skin tenderness, desquamation, and widespread blistering.

(Choice C) Neutrophilic infiltrates and elongation of dermal papillae are characteristic of psoriasis vulgaris, which typically causes symmetric, salmon-colored scaly plaques with sharply defined borders.

(Choice D) During an urticarial reaction, mast cells release inflammatory mediators and cytokines (eg, IL-5) that can recruit eosinophils, resulting in perivascular collections of eosinophils in and around the urticarial lesion. Urticaria usually manifests as pruritic, erythematous plaques (ie, wheal and flare reaction).

Educational objective:
Late-stage radiation dermatitis occurs months to years after radiation exposure and is characterized grossly by pigment changes, telangiectasias, and chronic ulceration. Typical histologic changes include vascular abnormalities, fibroblast proliferation, and homogenization of dermal collagen.

- **Fibrosis**, characterized histologically by **homogenization of dermal collagen**, due to fibroblast activation by **transforming growth factor-beta** from damaged tissue and responding immune cells
- Vascular damage, resulting in chronic hypoxia and ulceration
- Abnormal, dilated microvasculature (ie, telangiectasias)

(Choice A) Full-thickness epidermal necrosis with subepidermal bullae is characteristic of Stevens-Johnson syndrome/toxic epidermal necrolysis. This systemic immune reaction to certain medications (eg, allopurinol, carbamazepine, sulfonamides) results in fever, skin tenderness, desquamation, and widespread blistering.

(Choice C) Neutrophilic infiltrates and elongation of dermal papillae are characteristic of psoriasis vulgaris, which typically causes symmetric, salmon-colored scaly plaques with sharply defined borders.

(Choice D) During an urticarial reaction, mast cells release inflammatory mediators and cytokines (eg, IL-5) that can recruit eosinophils, resulting in perivascular collections of eosinophils in and around the urticarial lesion. Urticaria usually manifests as pruritic, erythematous plaques (ie, wheal and flare reaction).

Educational objective:
Late-stage radiation dermatitis occurs months to years after radiation exposure and is characterized grossly by pigment changes, telangiectasias, and chronic ulceration. Typical histologic changes include vascular abnormalities, fibroblast proliferation, and homogenization of dermal collagen (ie, fibrosis) due to the increased expression of transforming growth factor-beta.

References

- Chronic radiation-induced dermatitis: challenges and solutions.

Pathology	Dermatology	Radiation injury
Subject	System	Topic

Copyright © UWorld. All rights reserved.

Settings

1
2
3
4
5

Item 5 of 5
Question Id: 18927

Mark | Previous | Next | Full Screen | Tutorial | Lab Values | Notes | Calculator | Reverse Color | Text Zoom | Settings

Exhibit Display

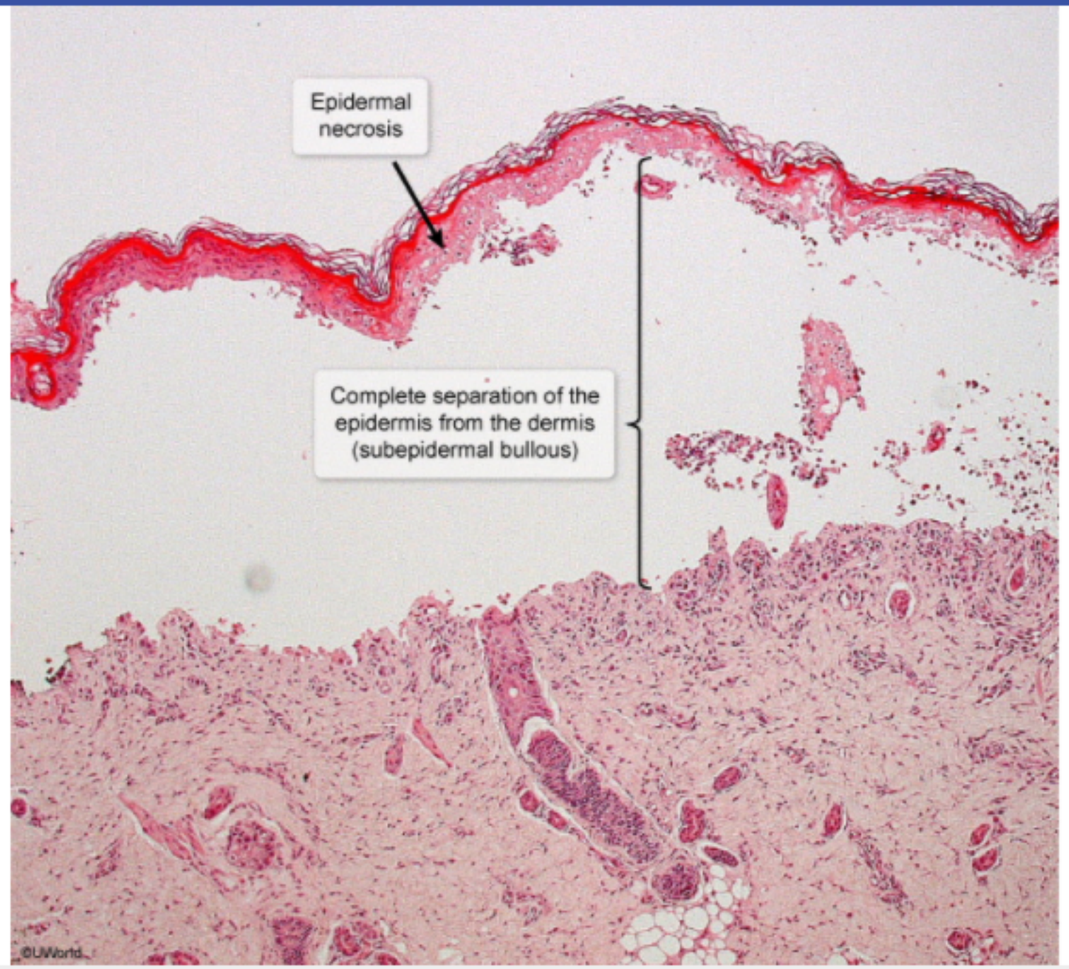

Zoom In | Zoom Out | Reset | Add To Flash Card

Block Time Remaining: 00:00:27
TUTOR

0 | Feedback | Suspend | End Block

Settings

1
2
3
4
5

Item 5 of 5
Question Id: 18927

Mark | Previous | Next | Full Screen | Tutorial | Lab Values | Notes | Calculator | Reverse Color | Text Zoom | Settings

Exhibit Display

Toxic epidermal necrolysis

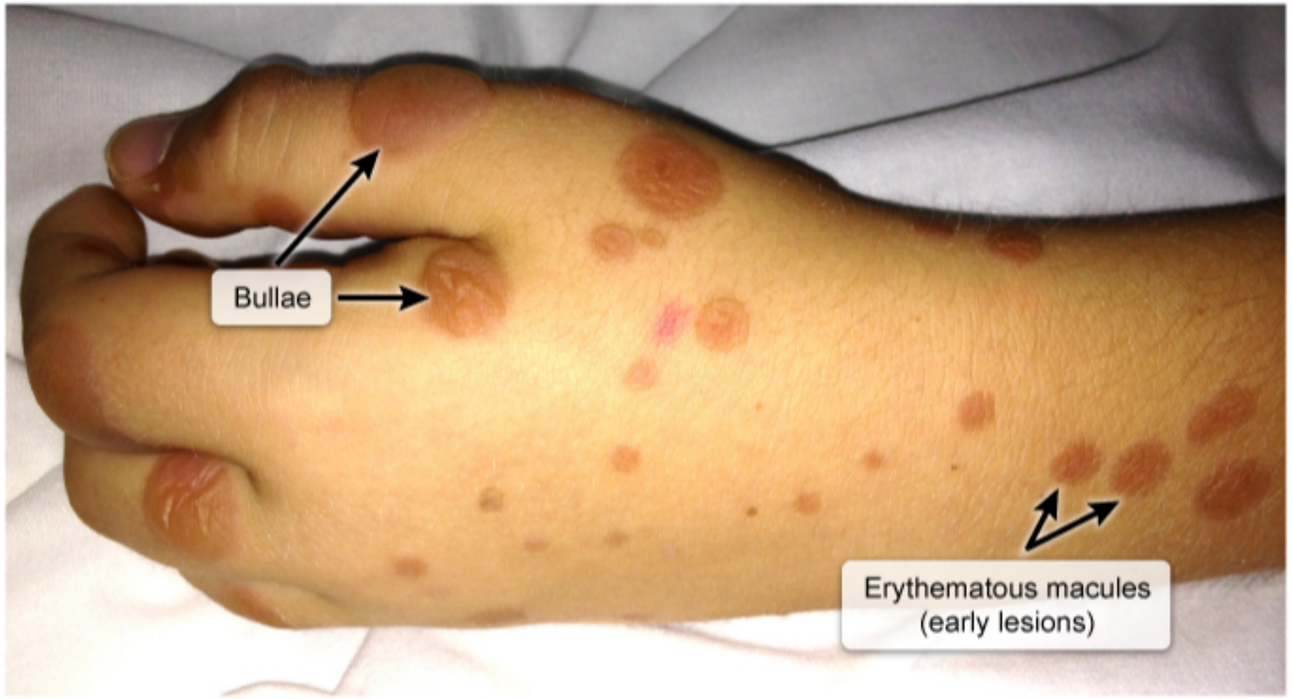

©UWorld

Zoom In | Zoom Out | Reset | Add To Flash Card

Block Time Remaining: 00:00:27
TUTOR

0 | Feedback | Suspend | End Block

Settings

1
2
3
4
5

Item 5 of 5
Question Id: 18927

Mark | Previous | Next | Full Screen | Tutorial | Lab Values | Notes | Calculator | Reverse Color | Text Zoom | Settings

Fibrosis, characterized histologically by **homogenization of dermal collagen**, due to fibroblast activation by **transforming growth**

Exhibit Display

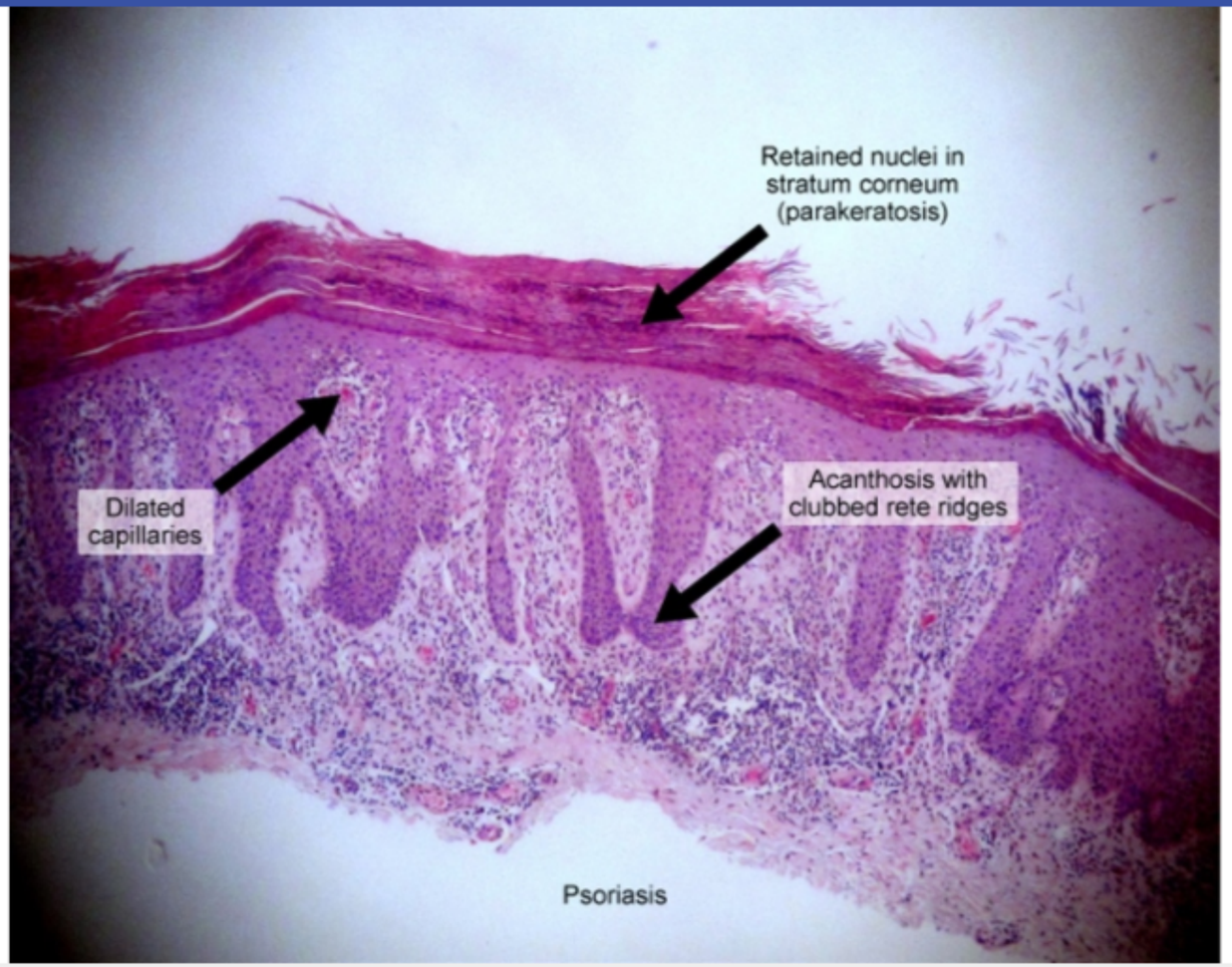

Zoom In | Zoom Out | Reset | Add To Flash Card

Block Time Remaining: 00:00:27
TUTOR

0 | Feedback | Suspend | End Block

Settings

1
2
3
4
5

Item 5 of 5
Question Id: 18927

Mark | Previous | Next | Full Screen | Tutorial | Lab Values | Notes | Calculator | Reverse Color | Text Zoom | Settings

Exhibit Display

Zoom In | Zoom Out | Reset | Add To Flash Card

Block Time Remaining: 00:00:27
TUTOR

0 | Feedback | Suspend | End Block

Exhibit Display

Wheal and flare

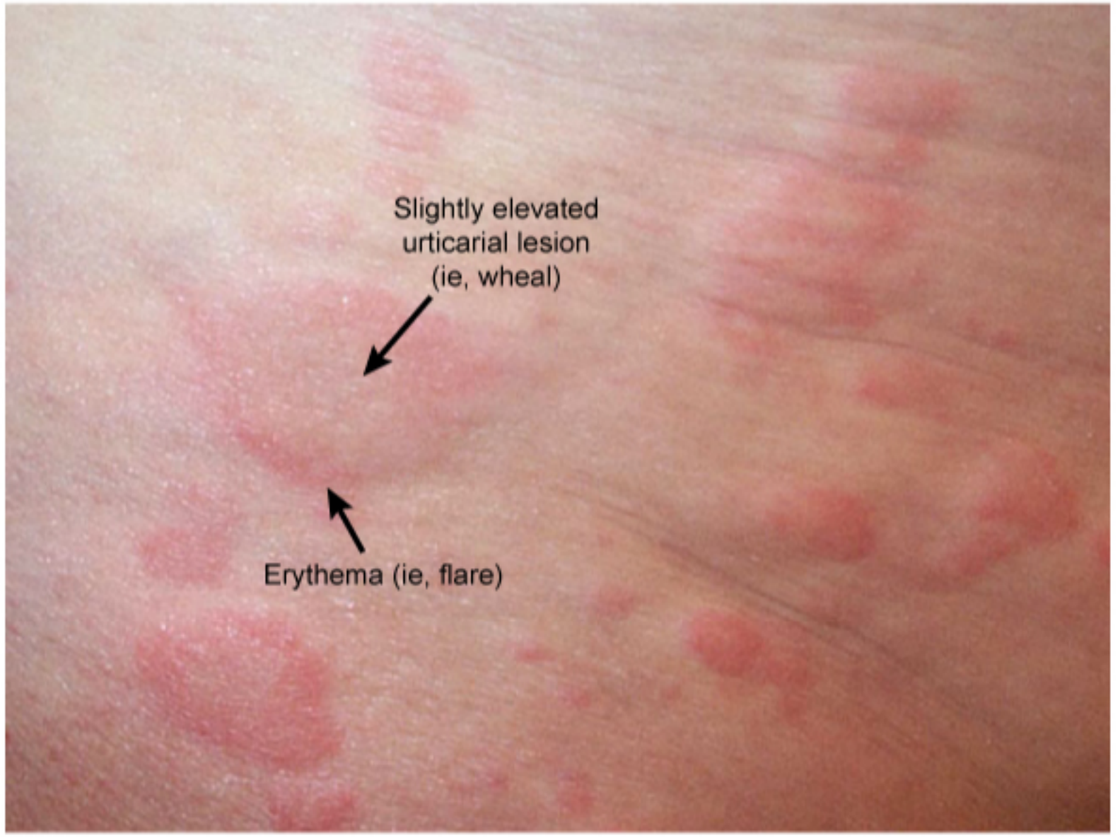

©UWorld

Zoom In
Zoom Out
Reset
Add To Flash Card